

Case Report

A RARE CASE OF PRIMARY TUBERCULAR OSTEOMYELITIS OF TEMPOROMANDIBULAR JOINT, CAUSING A FACIAL AND FUNCTIONAL MARRING - A CASE REPORT

Sreelatha S.V.¹, Pusphparaj Shetty², Vimal Kumar Karnaker³, Sanjeev H.⁴
 Reader¹, Professor & Head, Dept. of Oral Pathology & Microbiology²,
 A.B. Shetty Memorial Institute of Dental Sciences,
 Professor & Head³, Asst. Professor⁴, Dept. of Microbiology, K.S. Hegde Medical Academy,
 Nitte University, Mangalore - 575 018

Correspondence:

Sreelatha S.V.

Phone : +91-0824-2204963, Fax: +91-0824-22014162,

E-mail : sreelathakarnaker@hotmail.com

Introduction :

Tuberculosis of the temporomandibular joint is an extremely rare infection. We report a case of primary tubercular temporomandibular joint osteomyelitis in a 22 year old female patient presenting with swelling. A high index of suspicion is required for a correct diagnosis.

Tuberculous lesions of the oral cavity by primary inoculation are unusual, most cases occur as a result of tuberculosis of other parts of the body, generally the lung¹. Primary infection may occur in other organs of the body including the bones and joints but it usually involves a major joint². Only a few cases of primary tuberculosis of the temporomandibular joint (TMJ) are recorded, as it seldom arouses clinical suspicion. The diagnosis therefore, is variable and is established after biopsy. We report this case because of the rarity of its presentation and clinical interest.

Key-words: Primary tuberculosis, temporomandibular joint, osteomyelitis

Case report :

A 22 year old female patient reported with complaints of swelling and pus discharge occurring in the left preauricular area. The swelling increased in size over the last 6 months and has been associated with pain and reduced mouth opening. There was no history of trauma.

Past dental history revealed that the patient had undergone TMJ arthrocentesis for difficulty in mouth

opening after which the patient noticed an increase in the size of the swelling on the left side of her face for which she underwent an incision and drainage and was treated with antibiotics. The swelling still persisted with increased pain and reduced mouth opening.

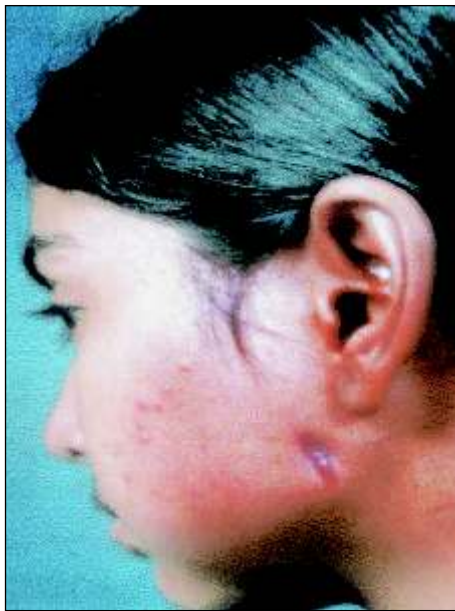Extra oral examination revealed a swelling measuring 3 x 2 cms which was tender soft in consistency causing a deviation of the mandible to the left with trismus. A purulent draining sinus near the angle of the mandible 1cm below the left tragus was seen. The left submandibular lymph node was enlarged, mobile and non tender.

Intraoral examination revealed a swelling measuring 2 x 2 cm over the left lower border of the mandible, extending from the second molar to the anterior border of the ramus with bicortical expansion. Orthopantomographic (OPG) examination revealed radiolucency with absence of the entire left condyle upto the subcondylar region with irregular hazy margins near the condylar neck area.

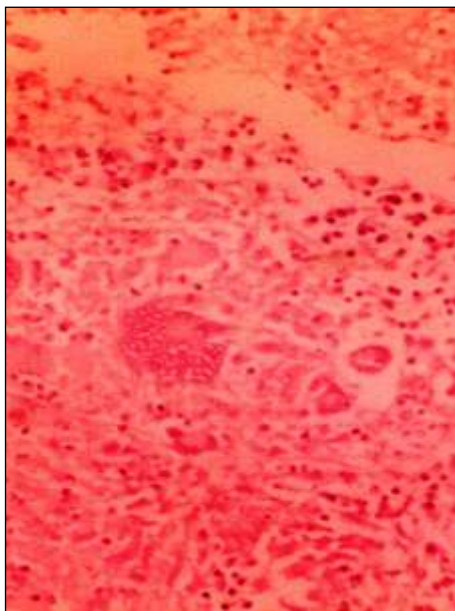
Routine haematological examination showed an elevated Erythrocyte Sedimentation Rate of 50 mm at the end of 1 hour. Mantoux skin test showed an induration of 30 mm. An excision biopsy was done and histopathological examination showed areas of necrosis, Langhans and foreign body type of giant cells, with epithelioid cells and lymphocytic infiltration, suggestive of a granulomatous lesion, probably tuberculosis. Acid Fast staining of the Histopathological section and pus specimen were negative

for Acid Fast bacilli.

Based on the clinical, OPG and Histopathological examination and a positive test for mantoux on skin testing a diagnosis of tuberculosis of TMJ was made and the patient was given antituberculosis treatment as per RNTCP-DOTS regimen Cat I. The patient responded well to the treatment with a complete remission and there was no evidence of recurrence and surgical corrective steps were



a- Sinus tract near the angle of the mandible 1cm below the left tragus



c- Langhans and foreign body type of giant cells, with epithelioid cells and lymphocytic infiltration

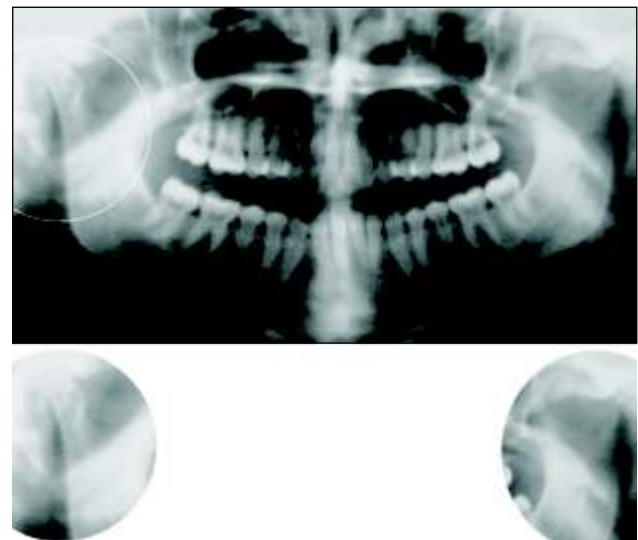
taken

Discussion :

Primary tuberculosis of the temporomandibular joint is rare. The clinical appearance of Tuberculosis of TMJ is non specific and may be similar to that of arthritis, osteomyelitis or chronic joint disease³. Tuberculosis of the jaw causes slow necrosis of the bone and may involve the entire mandible. The destruction of the bone in radiographs appears as blurring of trabecular details with irregular areas of radiolucency. There is erosion of cortex with little tendency to repair. Gradually the bone is replaced by soft tuberculous granulation tissue. Caseation appears at places followed by softening and liquefaction. A soft periosteal abscess then forms presenting as a painless, soft swelling. This cold abscess may burst either intra or extra orally forming single or multiple sinuses. Pathological fracture of mandible and sequestration may also occur⁴. In The present case the patient presented with swelling and discharging sinus at the TMJ.

The infection may extend to the mandible by:

1. Direct transfer from infected sputum or infected raw milk of cow through a) An open pulp in carious tooth b) An extraction wound or c) Gingival margin or perforation of an erupting tooth.



-I -Right Normal TMJ with mandibular condyle
b-ii -Left TMJ showing destroyed mandibular condyle

2. Regional extension of soft tissue lesion to involve the underlying bone.
3. Haematogenous route.⁴

Predisposing factors for primary oral tuberculosis include poor oro-dental hygiene, dental extractions, periodontitis and Leukoplakia^{5, 6}. In the present case the predisposing factor was the arthrocentesis procedure carried out in the patient. Followed by incision and drainage could be a source for the entry of Mycobacterium tuberculosis directly into the temporomandibular joint.

In our case histopathological examination of the biopsy specimen was an important aid in the diagnosis of a long

standing swelling refractory to routine treatment. The patient was also found to be positive for Mantoux test. Treatment if initiated early on diagnosis of tuberculosis can prevent the bone changes, facial deformity and a functional and facial marring. According to different authors, the difficulty in microbiologic detection of the tubercle bacilli may be due to the high immunity of the patient resulting in the destruction of the bacilli, their enclosure by local tissue reaction, very small numbers of tubercle bacilli in oral lesions, hence direct examination of scrapings stained with Ziehl - Neelsen stain are usually negative, and previous long term treatment with antibiotics¹. The response to treatment aided in the confirmation of the diagnosis.

References :

1. Ioannis D, Lambros Z, Lazaridis N, Dimitri K, Trigonidis G, Sichletidis L, et al., Primary tuberculosis of the oral cavity., Oral Surg Oral Med Oral Pathol 1991; 72:712-715.
2. D. Soman & S. J. Davies., A suspected case of tuberculosis of the temporomandibular joint. Br Dent J 2003; 194:23-24.
3. C. A. Helbling, O. Lieger, W. Smolka, T. Iizuka, J. Kuttenger., Primary tuberculosis of the TMJ: presentation of a case and literature review. Int. J. Oral Maxillofac. Surg 2010; 39:834-838.
4. K.B. Gupta, M .Manchanda, S.P.S. Yadav & A. Mittal., Tubercular osteomyelitis of mandible. Indian J Tuberc 2005; 52:147-150.
5. A. Chakravarti, Swatilika Pal & J. K. Sahni., Primary tuberculosis of tonsil and posterior oropharyngeal wall. Indian J Tuberc 2008; 55:48-50.
6. K .B. Gupta, S. Tandon, T. S. Jaswal & Sunita Singh., Tuberculosis of tonsil with unusual presentation. Indian J Tuberc 2001; 48:223-224.