

## Case Report

# AGGRESSIVE MONOPHASIC SARCOMATOID CARCINOMA OF SMALL INTESTINE - A RARE CASE REPORT WITH REVIEW OF LITERATURE

Shetty K. Padma<sup>1</sup>, Harish S. Permi<sup>2</sup>, C.N. Patil<sup>3</sup>, Michelle Mathias<sup>1</sup>

<sup>1</sup>Professor, <sup>2</sup>Associate Professor, Department of Pathology.

<sup>3</sup>Medical Oncologist, Department of Oncology.

K.S. Hegde Medical Academy, Nitte University, Deralakatte, Mangalore.

Correspondence :

Harish S. Permi,

Associate Professor, Department of Pathology, K.S. Hegde Medical Academy, Nitte University, Deralakatte, Mangalore.

Mobile : 99641 31827, E-mail : drharish01@gmail.com

## Abstract :

Sarcomatoid carcinoma occurring in the small intestine is very rare. They can be monophasic or biphasic. We report a rare case of monophasic Sarcomatoid carcinoma of the small intestine in a 60 year old male patient. The tumor was an ulceronodular mass involving the ileum circumferentially. The tumor infiltrated the full thickness of the intestinal wall and the serosa of an adjacent loop of ileum. Microscopically, the tumor was composed of sheets of malignant spindle cells. The carcinomatous nature of the tumor was evident only after Immunohistochemistry. The diagnosis of sarcomatoid carcinoma should be considered in the differential diagnosis of malignant spindle cell tumor of small intestine and immunohistochemical stains are required for the correct diagnosis.

Keywords : Sarcomatoid carcinoma, small intestine, monophasic, immunohistochemistry

## Introduction :

Small intestine represents more than 75% of the length and 90% of the total mucosal surface area of the alimentary tract. <sup>[1]</sup> Primary small intestinal malignant tumors are rare compared to gastric and colorectal cancer. <sup>[2]</sup> Sarcomatoid carcinoma is a rare variant of small intestinal carcinoma. <sup>[1]</sup> As the name implies, Sarcomatoid carcinoma is a carcinoma containing mesenchymal like spindle cell elements thus mimicking sarcoma or a composite malignant tumor. <sup>[3]</sup> We report here a rare case of small intestinal, Sarcomatoid carcinoma of ileum in a 60 year old male. Immunohistochemistry was very helpful in the correct diagnosis. To our knowledge, only 20 cases have been reported to date in the English literature. <sup>[3]</sup>

## Case Report :

A 60 year old male presented with continuous dull aching pain in the upper part of abdomen with radiation to back and recent onset constipation. Routine haematological, biochemical and serological investigations were within normal limits. CT scan of abdomen showed irregular thickening of small bowel loop in the right iliac fossa for

about 5 cms. [Figure 1] Few lymph nodes were noted in the mesentery and left paraaortic region. A portion of ileal segment, caecum with appendix and proximal third of transverse colon along with adherent loop of ileum was resected with ileo-transverse anastomosis. An 18 cms convoluted segment of intestine consisting of distal ileum, appendix, caecum, ascending colon and proximal third of transverse was received for histopathological examination. This segment of intestine was adherent to another segment of ileum measuring 13 cms in length. On cut opening the segment of intestine, an ulceronodular circumferential growth measuring 5cms noted. [Figure 2] The growth extended focally to the serosa of the ileum connected to the caecum. Microscopically the tumor showed sheets of predominantly malignant spindle cells arranged in fascicles, whorls and loose cohesive cluster. [Figure 3] The spindle cells displayed scanty cytoplasm with round to oval vesicular nucleus with enlarged prominent nucleoli. [Figure 4] Good number of abnormal mitotic figure was seen. (4-5/10 High Power Field). There was no evidence of epithelial differentiation. The tumor extended to the serosa with focal infiltration of the serosa of adjacent

loop of ileum. Possibility of malignant spindle cell sarcoma was considered. Immunohistochemical stains showed immunoreactivity to cytokeratin and negative for CD 117, Desmin, SMA, S-100, HMB-45 and Melan A. Final diagnosis of Sarcomatoid carcinoma was considered.

Discussion :

Primary small intestinal malignant tumors are relatively uncommon as compared to stomach and large intestine. Pathologically adenocarcinoma accounts for 40% of small bowel malignancies; others include carcinoid tumor, lymphoma, gastrointestinal stromal tumor and metastasis from melanoma, breast, lung and renal cancers. [2] Sarcomatoid carcinomas have been described in lungs, intestine, thyroid, salivary gland, breast and uterus. [4] Gastrointestinal Sarcomatoid carcinomas are unusual tumors seen mostly in the stomach, gall bladder, oropharynx and esophagus. [4] Dikman and Toker in 1973

were the first to describe such a tumor in the small bowel and named it enteroblastoma. [5] Other authors used terms like Sarcomatoid carcinoma, Carcinosarcoma, metaplastic carcinoma and spindle cell carcinoma. [3] Some authors have considered Carcinosarcoma or Sarcomatoid carcinoma as tumors with sarcomatous features immunoreactive for cytokeratin and epithelial membrane antigens but lacking carcinomatous component as was seen in our case. Shoji highlights the difficulty in making the correct diagnosis since Sarcomatoid component closely resembles sarcoma except for cytokeratin immunoreactivity. [6] The neoplasm primarily affects middle aged to older patients with a mean age of 57 years at presentation. [3] The symptoms associated with primary small intestinal tumors are nonspecific which include pain, gastrointestinal bleeding, weight loss ,nausea and vomiting. Non specificity of the symptoms is considered a contributing factor in the delayed diagnosis associated with small intestinal tumors. [1] Sarcomatoid

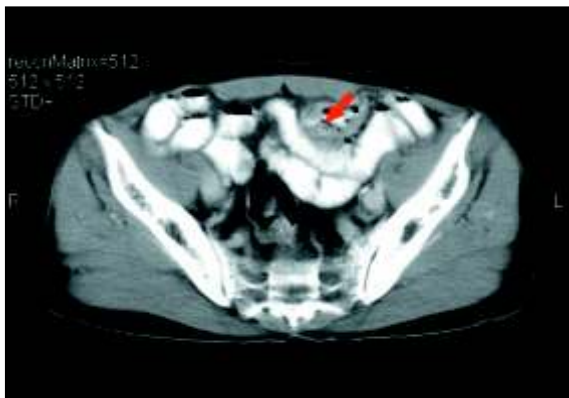

Figure 1) CT scan abdomen showing short segment of asymmetrical bowel wall thickening of small bowel (arrow).

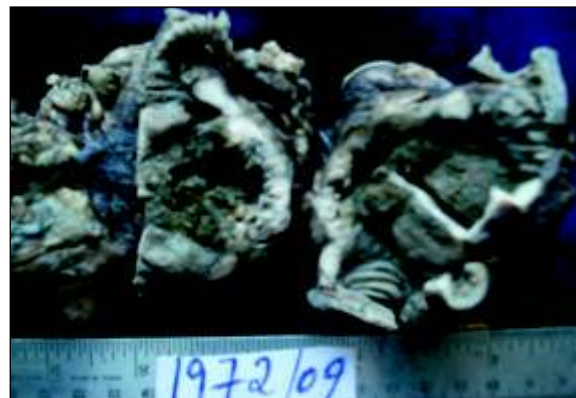

Figure 2) Gross specimen of ileum cut opened showing irregular greywhite ulcer-nodular growth.

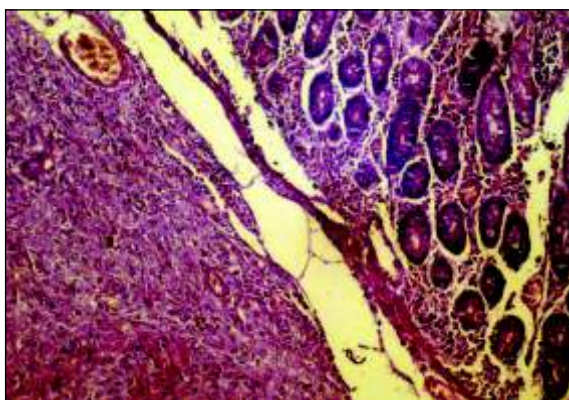


Figure 3) Microscopy showing pleomorphic spindle tumor cells arranged in fascicles and sheets infiltrating beneath the surrounding intact mucosa. (Hematoxylin & Eosin X100).

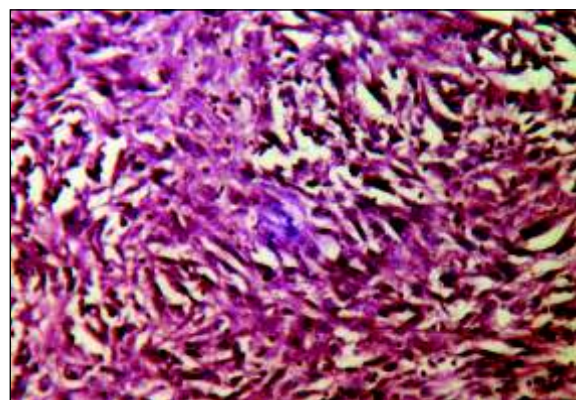


Figure 4) Microscopy showing pleomorphic spindle tumor cells showing vesicular nucleus with prominent nucleoli. (Hematoxylin & Eosin X400)

carcinoma occurs primarily in the ileum followed by jejunum. Only one case has been reported to date in the duodenum.<sup>[7]</sup> On histopathology, Sarcomatoid carcinoma may be monophasic or biphasic. The biphasic pattern is composed of a mixture of epithelial and mesenchymal components. The epithelial component is made up of oval to polygonal cells arranged in glandular, clusters and sheets. The cells have round to oval vesicular nucleus with prominent nucleolus. The mesenchymal component is composed of spindle cells with tapering cytoplasm, vesicular nucleus, and prominent nucleoli arranged in sheets, fascicles or haphazard pattern. Monophasic tumors show a predominance of mesenchymal component with minimal or absent epithelial components as was seen in our case.<sup>[3]</sup> Immunohistochemical markers show positivity for cytokeratin both in epithelial and mesenchymal components.<sup>[8]</sup> Both components may show focal positivity

for vimentin, chromogranin and Neuron specific enolase.<sup>[4]</sup> Our case showed only positivity for cytokeratin. Surgical resection remains the mainstay of treatment. Of the 20 cases reported 70% of the patients died within 2 months to 3 years of diagnosis.<sup>[3]</sup> Our case is on regular follow up following surgery as he was not willing for palliative chemotherapy.

#### Conclusion :

Monophasic Sarcomatoid carcinoma of small intestine is an aggressive tumor. It mimicks gastrointestinal stromal sarcoma where immunohistochemistry plays a vital role in the proper diagnosis. Although very rare in occurrence, it should be considered as one of the differential diagnosis of small intestinal malignancies due to aggressive nature of the tumor.

#### References :

1. Tsutomer Namikawa, Kazuhiro Hanazaki. Clinical analysis of primary anaplastic carcinoma of small intestine. *Gastro enterol* 2009; 15: 526-30.
2. Jun Cao, Yumxia Zuo, Fangfang L V, Zhiyu Chen. Primary small intestinal malignant tumors. Survival analysis in 48 postoperative patients. *J Clin Gastroenterol* 2008; 42:167-73.
3. Michelle Reid -Nicholson, Muhammed Idres, Giorgio Perino, Prodromos Hytioglou. Sarcomatoid carcinoma of small intestine. A case report & review of literature. *Arch Pathol Lab Med* 2004; 128:918-21.
4. Lezzoni JC, Mills SE. Sarcomatoid carcinoma of the gastrointestinal tract: a review. *Semin Diagn Pathol* 1993; 2:176-87.
5. Dikman SH, Toker C. Enteroblastoma complicating regional enteritis. *Gastroenterology* 1973; 65:562-6.
6. Shoji M, Doleashi Y, Iwaluchi K, Kuwao S, Mikami Kameya T. Sarcomatoid carcinoma of the descending colon. A histological, immunohistochemical and ultra structural analysis. *Acta Oncol* 1998; 37:765-8.
7. Robey-Cafferty SS, Silva EG, Cleary KR. Anaplastic and Sarcomatoid carcinoma of the small intestine. *Hum Pathol* 1989; 20:858-63.
8. Radi MF, Grey GF, Scott HW. Carcinosarcoma of ileum in regional enteritis. *Hum Pathol* 1985; 15:385-7.