

# The Role of Allopregnanolone Levels in Traumatic Brain Injury in Children and Adults and the Correlation of Its Levels with Computerized Tomography Images of the Brain

Göker Coskun<sup>1, </sup> Nesrin Gökben Beceren<sup>2</sup> Cihan Bedel<sup>3, </sup>

<sup>1</sup>Department of Emergency Medicine, Cigli Regional Training and Research Hospital, Izmir, Turkey

<sup>2</sup>Department of Emergency Medicine, Suleyman Demirel University Faculty of Medicine, Isparta, Turkey

<sup>3</sup>Department of Emergency Medicine, Health Science University Antalya Training and Research Hospital, Antalya, Turkey

**Address for correspondence** Cihan Bedel, MD, Health Science University Antalya Training and Research Hospital, Kazım Karabekir Street, Muratpaşa, Antalya 07100, Turkey (e-mail: cihanbedel@hotmail.com).

Indian J Neurosurg 2019;8:24–29

## Abstract

**Aim** Allopregnanolone (AP) is a steroid of progesterone origin and it can readily pass through the blood–brain barrier. The aim of this study was to determine the AP levels occurring after head trauma in children and adults and to compare these results to the findings observed in the computed tomography (CT) of the respective individuals.

**Materials and Methods** This study was conducted in the period from April 2018 to December 2018 on 92 patients admitted with isolated head trauma and on 80 healthy individuals in similar gender and age groups. The age, gender, and Glasgow Coma Scores of the patients; the cause of the head trauma; and the findings from CT imaging were recorded.

**Results** The levels of AP were significantly lower in the head trauma patients both in the adult and pediatric groups compared with the healthy control groups of respective ages ( $p < 0.001$ ). Furthermore, the levels of AP were significantly lower in both the pediatric and adult patients with identified pathologies in the CT images compared with their counterpart control groups ( $p < 0.001$ ). In predicting an existing pathology in the CT, an AP level of  $> 138.5$  was found to be 85.7% sensitive and 85.3% specific in the pediatric patients, and an AP level of  $> 118.3$  was 75% sensitive and 83.5% specific in the adult patients.

**Conclusion** The levels of AP in head trauma patients were reduced in both the pediatric and adult patients and these low levels increase the likelihood of detecting pathology in CT images.

## Keywords

- ▶ traumatic head injury
- ▶ allopregnanolone
- ▶ emergency department

## Introduction

Traumatic brain injury (TBI) is a type of external trauma, which may result in impairments in physical, cognitive, and psychosocial functions. It is the leading cause of mortality and disability in young individuals. The incidence of TBI has recently been found to be growing considerably.<sup>1</sup> In the United States of America (USA), approximately 1.5 to 2 million

patients present with TBI to an emergency department (ED) annually and the mortality rate of these patients is 17.6/100,000.<sup>2</sup> The most common causes of head trauma in Turkey are road traffic accidents and falls. Especially TBI due to motor-vehicle accidents has come to be a major socioeconomic problem because it is associated with long-term treatments, the requirement for care, and severe disability.<sup>3</sup>

The implementation of the computed tomography (CT) into the clinical practice in EDs made it the gold standard diagnostic technique especially for the evaluation of the head trauma patients. CT allows for facilitation in making the diagnosis of the lesions including intracranial bleeding, cerebral edema, traumatic infarcts, and basilar skull fractures.<sup>4</sup> However, despite the significant role of CT in diagnosing the intracranial pathologies, this imaging method is not entirely innocent. The potentially untoward effects of ionizing radiation in pregnancy and the risk of developing cancer in children after a series of imaging are major unfavorable effects of CT.<sup>5</sup>

Neurosteroids are synthesized from cholesterol in the central nervous system independent of the involvement of the adrenal glands and the gonads. These molecules have been recognized with their preserving activities on neurons. Allopregnanolone (AP) is a steroid of progesterone origin, which is synthesized *de novo* in the human brain independent of peripheral synthetic processes. AP can readily cross the blood-brain barrier owing to its lipophilic characteristics and low molecular weight.<sup>6</sup> In this study, we aimed to determine the levels of AP developing after head trauma in children and adults and to compare these levels with the findings obtained in the brain CT images of the respective individuals.

## Materials and Methods

This study was conducted at a tertiary-care hospital setting in the emergency department of a university hospital in the period from April 2018 to December 2018. After obtaining the Ethics Committee's approval, 92 patients (52 adults vs. 40 children) with isolated head trauma, who accepted to participate in the study, were included. The control group consisted of 80 healthy individuals (40 adults vs. 40 children) in similar gender and age groups. An informed consent form on paper was obtained from all individuals in the patient and control groups, who accepted to participate in the study.

The following individuals were excluded from the study: the ones having signs and symptoms indicating increased intracranial pressure or an organic brain lesion; patients with a major psychiatric disorder; patients admitted to the emergency surgery department; patients with a history of chronic diseases such as hypertension, cardiac failure, and asthma; pregnant women; individuals with a history of using oral contraceptives; and patients with a malignant disorder. Isolated head trauma is defined as any trauma to the head without other organ injury (extremity, abdominal, etc.). The patient and control groups were categorized into two subgroups within themselves as the pediatric and adult groups, consisting of patients younger than 18 years and patients aged 18 years or older, respectively. The age, gender, and Glasgow Coma Scores (GCS) of the patients; the cause of the head trauma and the way of its occurrence; the time elapsed until the collection of the blood samples; and the findings from CT imaging were recorded. The findings observed in the cranial CT images of the patients were reported by a specialist physician in radiology. Contusion/intraparenchymal bleeding, subarachnoid hemorrhage, epidural hemorrhage,

subdural hemorrhage, diffuse axonal injuries, and brain edema were accepted as pathological findings. Linear fractures, depression fractures, or basilar skull fractures were not accepted as pathological findings.

Blood samples were collected in 5 cm<sup>3</sup> biochemistry test tubes within at least an hour from every patient who presented with head trauma and who underwent a CT imaging. The blood samples were centrifuged at 4,000 rpm for 5 minutes as soon as they were collected. The obtained serum samples after the centrifuging process were stored at -80°C. The levels of AP in the serum samples were manually tested with enzyme-linked immunosorbent assay (ELISA) method, using Elabscience Human AP kit (Elabscience Biotechnology Co., Ltd., China). In the interpretation of the test results, the information in the manufacturer's instructions was used, reporting that the lowest possible AP level was 1.56 ng/mL and that the value of the optical density was inversely proportional to the levels of AP. All reagents were brought to the level of room temperature before use. The washing solution was diluted at a ratio of 1:25. The standard sample was made by diluting the reference standard in the consecutive concentrations of 100, 50, 25, 12.5, 6.25, 3.13, 1.56, and 0 ng/mL. Biotinylated antibodies for recognition and horseradish peroxidase conjugates were diluted at a ratio of 1:100. Immediately after putting a volume of 50 µL of the standard sample in each test tube, a 50 µL volume of biotinylated recognition antibodies was added into the tubes. Then, the tubes were incubated at 37°C for 45 minutes. After aspiration and washing, a 100 µL volume of horseradish peroxidase conjugate was added and, then, the tubes were incubated for 30 minutes. After they were aspirated and washed, a 90 µL volume of substrate reagent was added and left for incubation at 37°C for 15 minutes. The optic density values were obtained by reading the samples at a wavelength of 450 nm immediately after adding a 50 µL volume of stopping solution. The AP levels were calculated using the curve of the standard absorbance chart.

Standard deviation and the mean values were calculated for the continuous variables. Median and interquartile ranges were calculated for the non-parametric data. The independent variables were compared with the Chi-square or independent *t*-test, whichever was suitable. The optimum cutoff value for the AP level in detecting pathology in cranial CT was analyzed using receiver operating characteristic (ROC). The descriptive statistical analyses of all variables were performed with SPSS 18.0.

## Results

A total of 92 head trauma patients were included in the patient group in the study. Of them, 40 were children (9 females [22.5%] vs. 31 males [77.5%]) and 52 were adults (20 females [38.5%] vs. 32 males [61.5%]). In the control group, 40 children (9 females [22.5%] vs. 31 males [77.5%]) and 40 adults (15 females [37.5%] vs. 25 males [62.5%]) were included. The mean age was 8.17 ± 5.05 years in the pediatric patient group and it was 43.44 ± 20.82 years in the adult patient group. The mechanisms of trauma in the patient group included

motor-vehicle or motorcycle accidents in 56.5% ( $n = 52$ ) of the patients, high level-falls in 21.75% ( $n = 20$ ) of the patients, and sports injuries or other accidents in 21.75% ( $n = 20$ ) of the patients. According to the GCS scores; 87 patients had a mild brain injury (GCS:13–15), 3 patients had a moderate brain injury (GCS:9–12), and 2 patients had severe brain injury (GCS:3–8). The time elapsed from the time of the trauma until the collection of the blood samples was observed to be within the first hour in more than half of the patients. The main characteristics of the patients were presented in **Table 1**.

The levels of AP were statistically significantly different in the pediatric head trauma group compared with the pediatric control group. The AP levels were significantly low in the pediatric patient group ( $110.19 \pm 24.92$  vs.  $181.76 \pm 52.41$ , respectively,  $p < 0.001$ ). There was a statistically significant difference in the AP levels between the adult patient group and adult control group. The levels of AP were found to be significantly low in the adult patient group ( $101.23 \pm 49.40$  vs.  $175.86 \pm 58.31$ , respectively,  $p < 0.001$ ). The mechanisms of the trauma, the severity of the trauma, and the time elapsing from the occurrence of the trauma to the time of sampling were not significantly different between the groups ( $p > 0.05$ ). The comparison of the AP levels in the pediatric and adult patient groups was presented in **Table 2**.

There was a statistically significant difference in the AP levels between the pediatric control group and the pediatric patient group with identified pathology in the

CT images. The levels of AP were significantly low in the pediatric patient group ( $110.7 \pm 27.48$  vs.  $181.76 \pm 52.41$ , respectively,  $p < 0.001$ ) (**Fig. 1**). There was a statistically significant difference in the AP levels between the adult control group and the patient group with pathology in the CT images. The levels of AP were significantly low in the adult patient group ( $88.28 \pm 41.72$  vs.  $175.86 \pm 58.31$ , respectively,  $p < 0.001$ ) (**Fig. 2**).

A ROC curve analysis was performed to determine the optimum cutoff level of AP values to predict an existing pathology in the CT images. The AP value was  $>138.5$  and AUC was 0.873 in the pediatric patients (95% CI: 0.781 to 0.966,  $p < 0.001$ ). The cutoff value of AP  $> 138.5$  was 85.7% sensitive and 85.3% specific in detecting pathology in the CT images of the pediatric patients (**Fig. 3**). In the adult patients, the level of AP was  $>118.3$  and AUC was 0.871 (95% CI: 0.774 to 0.967,  $p < 0.001$ ). The cutoff value of AP  $> 118.3$  was 75% sensitive and 83.5% specific in detecting pathology in the CT images (**Fig. 4**).

## Discussion

Owing to the advances in technology and the improved imaging methods, CT has been the gold standard since the 1970s.<sup>7</sup> The common use of this method has revealed inappropriate use of this technique in the clinic and the lack of clear criteria to determine which patients should undergo an imaging test, leading to the conclusion that these factors increase the rate of unnecessary use of CT.<sup>8</sup> CT is a non-sensitive technique especially in minor head traumas and the ionizing radiation is a critical problem particularly for the pediatric patients.<sup>9</sup> Unfortunately, the use of biomarkers to facilitate the early diagnosis and treatment of TBI is not common in the clinical practice.<sup>10</sup> We aimed to demonstrate the feasibility of the use of serum AP levels as biomarkers in adult and pediatric TBI patients.

Neurosteroids are neuromodulators with important actions on neuron-neuron communication and interaction, which regulate numerous functions of the brain. It has long been known that these hormones readily cross the blood-brain barrier and are involved in neuron growth, development, and maturation.<sup>11</sup> AP is a derivative of progesterone and is one of the most commonly studied compounds among the neurosteroids. AP is a potent positive allosteric modulator of the GABA-A receptors.<sup>12</sup> AP has been demonstrated to act on several aspects of the neuron physiology via interacting with the GABA-A receptors. Thereby, it plays a critical role in the development and treatment processes of neurologic and psychiatric disorders.<sup>13,14</sup> The study by Yoshizawa et al demonstrated the anxiolytic properties of AP on mice.<sup>15</sup> A study on Alzheimer patients reported that AP is the main element in neurogenic and regenerative therapies because it readily crosses the blood-brain barrier.<sup>16</sup> Reddy et al conducted a study on treatment-resistant epilepsy patients and observed that progesterone given to the patients in the second half of the menstrual cycle increased the AP levels, providing therapeutic benefits.<sup>17</sup> Similarly, there are studies demonstrating the relationship of AP with several diseases

**Table 1** Baseline characteristics of patients

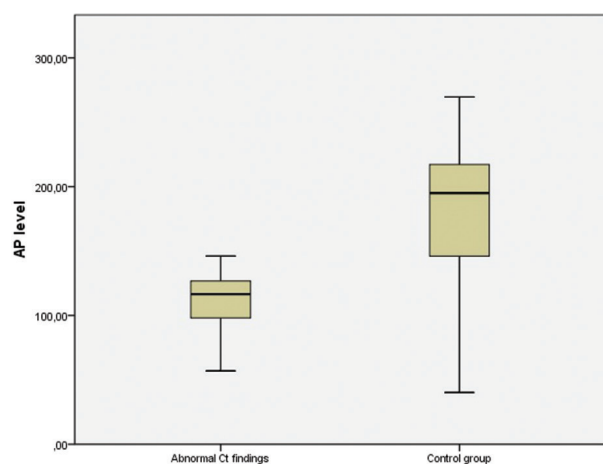
Variables	
Age, mean (range), y	
<18 y	8.17 $\pm$ 5.05
$\geq$ 18 y	43.44 $\pm$ 20.82
Gender n (%)	
Female	29 (31.5)
Male	63 (68.5)
Mechanism of dislocation n (%)	
Motor vehicle or motorcycle accident	52 (56.5)
Fall	20 (21.75)
Sports injury or other event	20 (21.75)
Severity of injury (GCS) n (%)	
Mild (13–15)	87 (94.5)
Moderate (9–12)	3 (3.2)
Severe (3–8)	2 (2.3)
Hours after TBI and AP analysis n (%)	
0–1 h	49 (53.3)
1–2 h	25 (27.2)
2–3 h	10 (10.9)
>3 h	8 (8.6)

Abbreviations: AP, allopregnanolone; GCS, Glasgow coma score; TBI, traumatic brain injury.

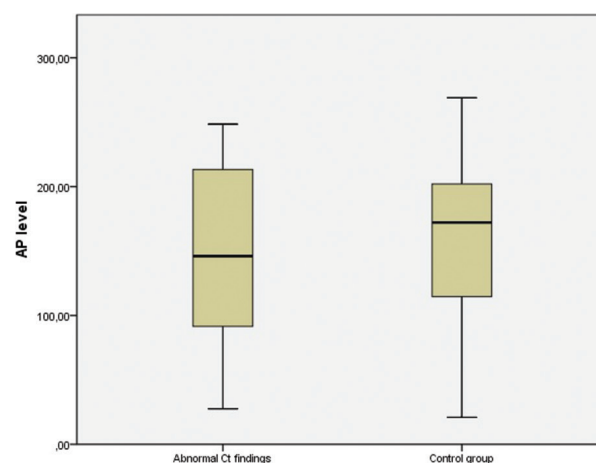
**Table 2** Comparison of AP levels in pediatric and adult groups

Variables	Pediatric patient	Pediatric control	p-Value	Adult patient	Adult patient	p-Value
Mean AP level	110.19 ± 24.92	181.76 ± 52.41	<0.001	101.23 ± 49.40	175.86 ± 58.31	<0.001
Gender			0.011			<0.001
Female	111.25 ± 20.92	126.56 ± 50.68		126.56 ± 50.68	159.71 ± 59.59	
Male	109.89 ± 26.27	182.61 ± 43.21		85.40 ± 42.05	185.26 ± 55.91	
Mechanism of dislocation			0.267			0.848
Motor vehicle or motorcycle accident	107.42 ± 23.89			89.39 ± 39.34		
Fall	124.04 ± 20.72			93.12 ± 49.59		
Sports injury or other event	85.25 ± 21.58			97.92 ± 31.28		
Severity of injury (GCS)			0.41			0.912
Mild (13–15)	110.52 ± 25.26			101.62 ± 50.05		
Moderate (9–12)	97.64 ± 11.21			98.5 ± 67.29		
Severe (3–8)				95.99 ± 9.67		
Hours after TBI and AP analysis			0.682			0.582
0–1 h	109.48 ± 21.91			87.57 ± 46.07		
1–2 h	109.43 ± 26.71			120.32 ± 27.63		
2–3 h	125.94 ± 27.03			143.49 ± 70.43		
>3 h	97.29 ± 36.07			90.42 ± 48.9		
CT findings			NS			NS
Normal	110.69 ± 24.28			104.58 ± 50.78		
Abnormal	107.38 ± 30.7			88.72 ± 43.73		

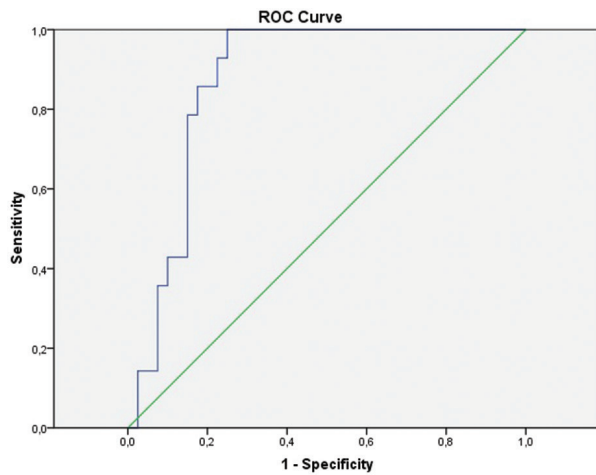
Abbreviations: AP, allopregnanolone; CT, computed tomography; GCS, Glasgow coma score; NS, not significant; TBI, traumatic brain injury.



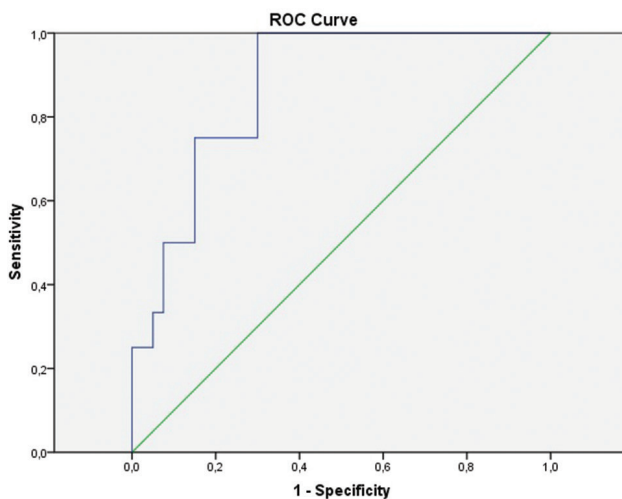
**Fig. 1** Box graph of AP levels between the pediatric control group and the pediatric patient group with identified pathology in the CT images. AP, allopregnanolone; CT, computed tomography.



**Fig. 2** Box graph of AP levels between the adult control group and the patient group with pathology in the CT images. AP, allopregnanolone; CT, computed tomography.



**Fig. 3** A receiver operating characteristic (ROC) curve analysis in pediatric groups to determine AP values to predict an existing pathology in the CT images. AP, allopregnanolone; CT, computed tomography.



**Fig. 4** A receiver operating characteristic (ROC) curve analysis in adult groups to determine AP values to predict an existing pathology in the CT images. AP, allopregnanolone; CT, computed tomography.

including depression, neurodegenerative diseases, and alcohol intoxication.<sup>18-20</sup> However, there are currently no studies in the literature evaluating the association of AP levels with the findings in TBI patients. In our study, we found out that the AP levels both in the pediatric and adult head trauma patient groups were significantly lower compared with the control group. Furthermore, we have demonstrated that the levels of AP can be used as a biomarker in detecting pathology in CT images. A study found out that the pregnenolone levels were significantly lower in the soldiers with a history of TBI compared with the control group.<sup>21</sup> However, the time elapsed from the time of the trauma until the collection of laboratory samples was not reported in that study. The potential length of this period may suggest that the levels of pregnenolone might have been found low due to the post-traumatic stress disorder.<sup>22</sup>

In our study, a significant difference in the relationship between the AP levels and the time to elapse from

the trauma until the analysis was not observed in both of the two groups. However, we think that our study is more independent of the effect of the time and our data are more homogeneous compared with similar studies because more than half of the samples in our study were collected within the first hour. A study designed in a stream of thought similar to ours addressed the unreliability of the results from the samples collected within a period longer than 3 hours.<sup>23</sup>

There are several studies in the literature, investigating the likelihood of GCS scores in detecting pathology in CT images of TBI patients. Similarly, despite the studies on mild head trauma patients reporting the negative predictive value of some proteins in detecting pathology in CT images, it was also observed that the levels of these proteins increased in the marathon runners and swimmers after the exercise, affected by the dark color of the skin, and their levels especially increased in spinal cord injuries and long bone fractures in the absence of head trauma. It is also reported that the tests became negative after a period of 180 minute, which was the half-life of the respective proteins.<sup>24</sup> To the best of our knowledge, there were no studies in the literature, investigating the relationship between TBI and AP levels. Our study revealed the likelihood of the existence of a relationship of the low AP levels with detecting pathology in CT images.

This present study had some limitations. The first of them was the conduct of the study at a single center on a limited number of patients. Second, it is a major limitation that the menstrual cycle state of the patients, comorbid conditions, and medication use were not evaluated in our study. The third limitation is the evaluation of the baseline AP levels only, which were tested in the sera of the patients at the time of admission. This made it not possible to compare the basal levels of AP with the consecutive test results. Furthermore, another major limitation is the lack of comparison of the AP levels with the other biomarkers of TBI. In addition, the study patients mostly had mild head trauma according to the severity of the trauma.

## Conclusion

Levels of AP are found to be low in both adult and pediatric trauma patients and these low levels increase the likelihood of detecting pathology in CT images. Based on the results derived from the analysis of the present study data, we are of the opinion that the levels of AP can contribute to the decision-making process for having CT images in making the diagnosis of head trauma and that it can be a favorable biomarker in predicting pathology in CT images.

### Authors' Contributions

All authors made a substantial contribution to the study design, data interpretation, and writing and reviewing the manuscript.

### Ethical Approval

Ethics committee approval was received for this study (66/2018).



**Informed Consent**

Written informed consent was obtained from the participants for their anonymized information to be published in this article.

**Funding**

This study was supported by Süleyman Demirel University Scientific Research Projects Coordination Unit (Project no: 4647-TU1-16).

**Conflict of Interest**

None declared.

**References**

- 1 Martins ET, Linhares MN, Sousa DS, et al Mortality in severe traumatic brain injury: a multivariate analysis of 748 Brazilian patients from Florianópolis city. *J Trauma* 2009;67(1):85–90
- 2 Maas AIR, Menon DK, Adelson PD, et al InTBIR Participants and Investigators. Traumatic brain injury: integrated approaches to improve prevention, clinical care, and research. *Lancet Neurol* 2017;16(12):987–1048
- 3 Polat Ö, Uçkun ÖM, Tuncer C, Belen AD. Is IL-8 level an indicator of clinical and radiological status of traumatic brain injury? *Ulus Travma Acil Cerrahi Derg* 2019;25(2):193–197
- 4 Marincowitz C, Lecky FE, Townend W, Borakati A, Fabbri A, Sheldon TA. The risk of deterioration in GCS13–15 patients with traumatic brain injury identified by computed tomography imaging: a systematic review and meta-analysis. *J Neurotrauma* 2018;35(5):703–718
- 5 Huda W. Radiation risks: what is to be done? *Am J Roentgenol* 2015;204(1):124–127
- 6 Karout M, Miesch M, Geoffroy P, et al Novel analogs of allopregnanolone show improved efficiency and specificity in neuroprotection and stimulation of proliferation. *J Neurochem* 2016;139(5):782–794
- 7 Mutch CA, Talbot JF, Gean A. Imaging evaluation of acute traumatic brain injury. *Neurosurg Clin N Am* 2016;27(4):409–439
- 8 Rosen CB, Luy DD, Deane MR, Scalea TM, Stein DM. Routine repeat head CT may not be necessary for patients with mild TBI. *Trauma Surg Acute Care Open* 2018;3(1):e000129
- 9 So WH, Chan HF, Li MK. Investigation of risk factors of geriatric patients with significant brain injury from ground-level fall: a retrospective cohort study in a local Accident and Emergency Department setting. *Hong Kong J Emerg Med* 2018;25:305–312
- 10 Zetterberg H, Blennow K. Fluid markers of traumatic brain injury. *Mol Cell Neurosci* 2015;66(Pt B):99–102
- 11 Vallée M. Neurosteroids and potential therapeutics: focus on pregnenolone. *J Steroid Biochem Mol Biol* 2016;160:78–87
- 12 McEvoy K, Payne JL, Osborne LM. Neuroactive steroids and perinatal depression: a review of recent literature. *Curr Psychiatry Rep* 2018;20(9):78
- 13 Dichtel LE, Lawson EA, Schorr M, et al. Neuroactive steroids and affective symptoms in women across the weight spectrum. *Neuropsychopharmacology* 2018;43(6):1436–1444
- 14 Guennoun R, Labombarda F, Gonzalez Deniselle MC, Liere P, De Nicola AF, Schumacher M. Progesterone and allopregnanolone in the central nervous system: response to injury and implication for neuroprotection. *J Steroid Biochem Mol Biol* 2015;146:48–61
- 15 Yoshizawa K, Okumura A, Nakashima K, Sato T, Higashi T. Role of allopregnanolone biosynthesis in acute stress-induced anxiety-like behaviors in mice. *Synapse* 2017;71(8):21978
- 16 Meyer M, Garay LI, Kruse MS, et al. Protective effects of the neurosteroid allopregnanolone in a mouse model of spontaneous motoneuron degeneration. *J Steroid Biochem Mol Biol* 2017;174:201–216
- 17 Reddy DS, Kim HY, Rogawski MA. Neurosteroid withdrawal model of perimenstrual catamenial epilepsy. *Epilepsia* 2001;42(3):328–336
- 18 Schüle C, Nothdurfter C, Rupprecht R. The role of allopregnanolone in depression and anxiety. *Prog Neurobiol* 2014;113:79–87
- 19 Griffin LD, Gong W, Verot L, Mellon SH. Niemann-Pick type C disease involves disrupted neurosteroidogenesis and responds to allopregnanolone. *Nat Med* 2004;10(7):704–711
- 20 Torres JM, Ortega E. Alcohol intoxication increases allopregnanolone levels in female adolescent humans. *Neuropsychopharmacology* 2003;28(6):1207–1209
- 21 Marx CE, Naylor JC, Kilts JD, et al. Neurosteroids and traumatic brain injury: translating biomarkers to therapeutics; overview and pilot investigations in Iraq and Afghanistan era veterans. In: Laskowitz D, Grant G, eds. *Translational Research in Traumatic Brain Injury* Boca Raton (FL). CRC Press; 2016: 166–183
- 22 Rasmusson AM, Pinna G, Paliwal P, et al. Decreased cerebrospinal fluid allopregnanolone levels in women with posttraumatic stress disorder. *Biol Psychiatry* 2006;60(7):704–713
- 23 Müller K, Townend W, Biasca N, et al. S100B serum level predicts computed tomography findings after minor head injury. *J Trauma* 2007;62(6):1452–1456
- 24 Thelin EP, Nelson DW, Bellander BM. A review of the clinical utility of serum S100B protein levels in the assessment of traumatic brain injury. *Acta Neurochir (Wien)* 2017;159(2):209–225