




# Humeral Head Osteonecrosis: Outcomes of Hemiarthroplasty After Minimum 10-Year Follow-Up\*

## *Osteonecrose da cabeça do úmero: Avaliação dos resultados da artroplastia parcial com seguimento mínimo de 10 anos*

Alberto Naoki Miyazaki<sup>1</sup> Guilherme do Val Sella<sup>2</sup> Luciana Andrade da Silva<sup>2</sup> Caio Santos Checchia<sup>2</sup>  
Felipe Cerávolo Lemos<sup>2</sup>

<sup>1</sup>Department of Orthopedics and Traumatology, Faculty of Medical Sciences, Shoulder and Elbow Surgery Group, Santa Casa de São Paulo, São Paulo, SP, Brazil

<sup>2</sup>Shoulder and Elbow Surgery Group, Santa Casa de São Paulo, São Paulo, SP, Brazil

Address for correspondence Luciana Andrade da Silva, Rua Estuário, 519, Chácara Monte Alegre, São Paulo, SP, 04645-100, Brazil (e-mail: lucalu@terra.com.br).

Rev Bras Ortop 2021;56(1):91–97.

### Abstract

**Objective** To analyze long-term functional and radiographic results of partial shoulder replacement for humeral head osteonecrosis.

**Methods** Retrospective review of thirteen cases, with a mean postoperative follow-up of 17 years (range 10 to 26 years). The findings from the last follow-up were compared to those in which the patients had one year of postoperative follow-up. Functional assessment consisted of shoulder movement measurements and application of the University of California, Los Angeles (UCLA) shoulder score. All patients underwent radiographic examination to measure glenoid erosion, proximal humeral migration and lateral glenohumeral dislocation.

**Results** Glenoid erosion increased over time significantly ( $p < 0.05$ ). Paradoxically, all active shoulder movements also improved ( $p < 0.05$ ), while UCLA scores remained the same. Radiographic deterioration was not correlated with clinical function. We had an 84.7% survival rate for arthroplasties after a mean time of 16 years.

**Conclusions** Early functional outcomes were maintained in the long run and do not correlate with radiographic deterioration (increased erosion of the glenoid).

### Keywords

- ▶ osteonecrosis
- ▶ humeral head
- ▶ follow-up studies

### Resumo

**Objetivo** Analisar os resultados funcionais e radiográficos de longo prazo da artroplastia parcial do ombro para osteonecrose da cabeça do úmero.

**Métodos** Revisão retrospectiva de 13 casos, com seguimento pós-operatório médio de 17 anos (variação de 10 a 26 anos). Os achados do último seguimento foram

\* Shoulder and Elbow Surgery Group, Department of Orthopedics and Traumatology, Faculty of Medical Sciences of Santa Casa de São Paulo, "Pavilhão Fernandinho Simonsen" (DOT – FCMSCSP) (Director: Prof. Ivan Chakkour, Ph.D).

received  
June 21, 2019  
accepted  
October 3, 2019  
published online  
March 16, 2020

DOI <https://doi.org/10.1055/s-0039-3402471>.  
ISSN 0102-3616.

© 2020. Sociedade Brasileira de Ortopedia e Traumatologia. All rights reserved.  
This is an open access article published by Thieme under the terms of the Creative Commons Attribution-NonDerivative-NonCommercial-License, permitting copying and reproduction so long as the original work is given appropriate credit. Contents may not be used for commercial purposes, or adapted, remixed, transformed or built upon. (<https://creativecommons.org/licenses/by-nc-nd/4.0/>)  
Thieme Revinter Publicações Ltda., Rua do Matoso 170, Rio de Janeiro, RJ, CEP 20270-135, Brazil

**Palavras-chave**

- ▶ osteonecrose
- ▶ cabeça do úmero
- ▶ seguimentos

comparados àqueles em que os pacientes tinham com 1 ano de acompanhamento pós-operatório. A avaliação funcional consistiu em medidas do movimento do ombro e aplicação do escore do ombro da Universidade da Califórnia, Los Angeles (UCLA). Todos os pacientes foram submetidos a exame radiográfico para medir a erosão glenoidal, a migração umeral proximal, e o deslocamento glenoumeral lateral.

**Resultados** A erosão da glenoide aumentou com o tempo significativamente ( $p < 0,05$ ). Paradoxalmente, todos os movimentos ativos do ombro também melhoraram ( $p < 0,05$ ), enquanto os escores da UCLA permaneceram os mesmos. A deterioração radiográfica não teve correlação com a função clínica. Tivemos uma taxa de sobrevida de 84,7% das artroplastias após tempo médio de 16 anos.

**Conclusões** Os resultados funcionais precoces mantiveram-se a longo prazo e não se correlacionem com a deterioração radiográfica (aumento da erosão glenoidal).

**Introduction**

Humeral head osteonecrosis is a rare condition, but a significant cause of shoulder joint pain, which in many cases responds poorly to non-surgical treatment.<sup>1-3</sup> It corresponds to approximately 5% of the preoperative diagnosis of all shoulder arthroplasties performed.<sup>4</sup>

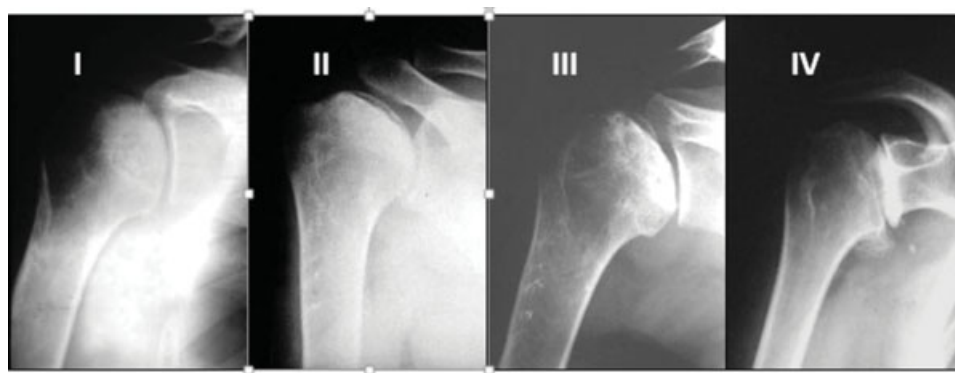
When opting for surgical treatment of osteonecrosis, depending on the degree of involvement of the joint surface, the most common indication is arthroplasty.<sup>2,5,6</sup> The decision on the choice between partial and total arthroplasty is generally based on the state of the cartilage of the glenoid cavity during surgery. Neer classified the disease into 4 stages: in stage 3 of Neer, there is collapse of the subchondral bone of an area of the humeral head; the cartilage in this region is irregular and may come loose. The use of partial shoulder arthroplasty is recommended at this stage. In stage 4, in which there is also involvement of the articular surface of the glenoid cavity, total arthroplasty is usually indicated. However, if there is rotator cuff tendon injury, concentric arthrosis, and/or if the surgeon deems that the glenoid cavity bone stock is very poor, a partial arthroplasty is always an option<sup>6</sup> (► Fig. 1).

The literature shows that the use of partial arthroplasty for the surgical treatment of osteonecrosis is effective for pain

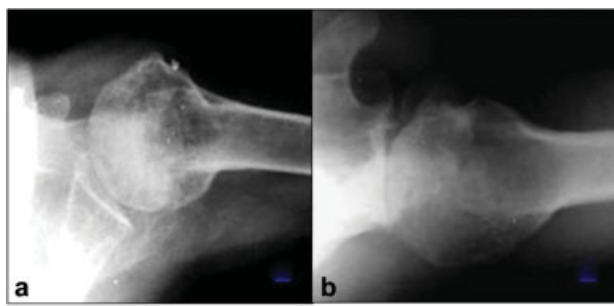
relief, for increased shoulder mobility, and patient satisfaction, even when compared to total arthroplasty results.<sup>2,4,6,7</sup>

Pollock et al,<sup>8</sup> in 1996, in a clinical evaluation study, obtained good results with the use of partial arthroplasty in concentric arthroses (when the humeral head remains centered in the glenoid cavity), as well as total arthroplasty in eccentric arthroses (in which there is incongruity of the humeral head, leading to uneven glenoid deterioration, and, eventually, the posterior subluxation of the humeral head) (► Fig. 2). In 2001, our group evaluated 21 patients with humeral head osteonecrosis who underwent total and partial arthroplasty performed at our medical service, with a mean follow-up of 37 months. In this study, it was concluded that total or partial arthroplasty is a good procedure for pain relief and joint function recovery of these patients.<sup>9</sup>

However, few studies have compared the long-term results of total arthroplasty with hemiarthroplasty in osteonecrosis cases. Gadea et al,<sup>10</sup> in 2012, showed a 94% survival rate of arthroplasty over a 10-year follow-up. The authors concluded that partial shoulder arthroplasty is a reliable indication in cases of humeral head osteonecrosis, regardless of etiology. However, in the same study, the authors highlighted the fact that, despite similar functional results, it was observed that the “survival” rate was higher when total prosthesis was performed.<sup>10</sup>



**Fig. 1** Radiographic aspect of the different stages of humeral head osteonecrosis, according to the Neer classification.<sup>6</sup>



**Fig. 2** Concentric-type (a) and eccentric (b) humeral head osteonecrosis, according to Pollock et al.<sup>8</sup>

The development of erosion of the glenoid cavity is a known complication of partial shoulder arthroplasty, being the main cause of unfavorable evolution in the medium and long term, resulting in pain, progressive loss of range of motion, decreased shoulder function and consequently increased patient dissatisfaction rates.<sup>4,11-14</sup> Herschel et al<sup>11</sup> showed that the glenoid cavity developed some degree of visible erosion on radiographic examination in 89% of the operated patients, after a mean follow-up of 51 months.

The aim of this study is to verify if, over 10 years, the functional results of our patients who underwent partial arthroplasty due to osteonecrosis were maintained, if they had erosion progression, and if their clinical results correlate with the radiographic findings found in the current exams.

## Casistry and Methods

Between December 1988 and February 2008, 27 partial arthroplasties were performed on 27 shoulders of 25 patients to treat osteonecrosis.

All patients with humeral head osteonecrosis were included in our study, regardless of etiology or degree of involvement, who underwent partial arthroplasty and completed a minimum follow-up of 10 years postoperatively. Patients who did not meet the above criteria were excluded from the study.

From the 27 shoulders, we could reevaluate 13, with follow-up ranging from 10 to 26 years (average 16.8 years). Twelve patients (14 shoulders, 2 had bilateral partial arthroplasty) were excluded: 5 because they could not be located and 7 because they died, not completing a 10-year follow-up (► **Table 1**).

The age of the patients at the last assessment ranged from 42 to 92 years (mean: 71 years). Six (46.15%) patients were male and 7 (53.85%) female. In 8 (61.54%) situations, the dominant side was affected.

Regarding the etiology, we had 8 (61%) shoulders with posttraumatic necrosis, 3 (23%) shoulders with idiopathic necrosis, 1 shoulder (7.7%) due to sickle cell anemia, and 1 shoulder (7.7%) due to dysbarism.

The degree of joint involvement was assessed by staging of Ficat and Enneking,<sup>15</sup> modified by Neer,<sup>6</sup> consisting of 10 (77%) cases of stage III necrosis, and 3 (23%) in stage IV. (► **Fig. 1**) All cases in stage IV were considered as concentric arthrosis.<sup>8</sup>

All patients underwent partial deltopectoral access arthroplasty. All arthroplasties had a cemented humeral shaft, and the models used were, in seven cases, the Neer II model (Memphis, Tennessee, US), and in six cases, the Eccentra model (São Paulo, SP, Brazil).

Postoperatively, the patients were immobilized for 6 weeks in a sling of the “Velpeau” type. Physiotherapy started with pendular and external to neutral rotation exercises, passively, from the 1<sup>st</sup> postoperative day. The active movements are introduced from the 6<sup>th</sup> week.

To measure the degree of joint mobility, we used the method of the American Academy of Orthopedic Surgeons (AAOS).<sup>16</sup>

**Table 1** Clinical data of patients

Case	Age (y)	Gender	Dom	Etiology	Neer (stage)	Prosthesis type	Follow-up (y)
1	59	F	–	Posttraumatic	III	Neer II	27
2	73	F	–	Idiopathic	III	Neer II	24
3	74	M	+	Dysbarism	III	Neer II	23
4	57	M	–	Idiopathic	III	Eccentra	20
5	92	F	+	Posttraumatic	IV	Neer II	19
6	68	M	+	Posttraumatic	III	Eccentra	18
7	74	M	–	Posttraumatic	III	Neer II	15
8	62	M	+	Posttraumatic	III	Eccentra	13
9	72	M	–	Posttraumatic	III	Eccentra	13
10	79	F	+	Posttraumatic	IV	Neer II	12
11	42	F	+	Sickle cell anemia	III	Eccentra	12
12	88	F	+	Idiopathic	IV	Neer II	10
13	85	F	+	Posttraumatic	III	Eccentra	10

Source: Institution Medical Archives.

Abbreviations: DOM, dominance; F, female; M, male; y, year.

For the functional evaluation of the patients, we used the University of California, Los Angeles (UCLA) method.<sup>17</sup>

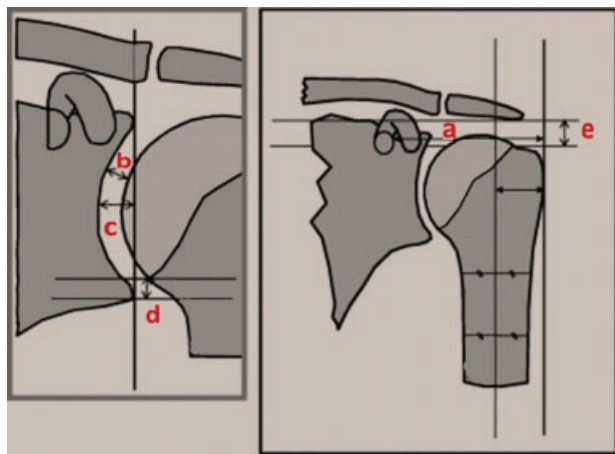
All patients underwent imaging reevaluation. Shoulder radiographs were performed in the corrected frontal, axillary and supraspinatus tunnel positions. In corrected frontal radiography, we measured some parameters based on the method published by Ohl et al<sup>18</sup>:

- **lateral glenohumeral offset:** defined as the distance between the lateral margin of the greater tubercle and the base of the coracoid process;
- **glenohumeral joint space:** defined as the region where the joint space is narrower between the prosthesis and the glenoid;
- **glenoid cavity depth:** measured between the center of the glenoid and a line passing between the apex and the lower margin of the glenoid;
- **proximal humerus migration:** defined as the distance between a horizontal line passing through the lower margin of the glenoid and a horizontal line through the humeral head implant;
- **subacromial space:** determined by the distance separating the upper limit of the greater tubercle and the lower margin of the acromion (►Fig. 3).

The degree of erosion of the glenoid cavity was evaluated on the shoulder radiograph, frontal corrected incidence, using the method proposed by Sperling et al<sup>19</sup> and Herschel et al,<sup>11</sup> in 2007, being graduated as follows:

- **Absent (grade I);**
- **Mild (grade II),** erosion in the subchondral bone;
- **Moderate (grade III),** medialization of subchondral bone with hemispheric deformation of the glenoid;
- **Severe (grade IV),** complete hemispheric deformation of the glenoid with superior bone loss at the base of the coracoid process.

For the sample of 13 patients, frequency distributions were initially calculated, some descriptive statistical tests



**Fig. 3** Illustration showing the different radiographic parameters used: (a) lateral glenohumeral offset, (b) joint space, (c) glenoid cavity depth (GC), (d) proximal migration (pM), (e) subacromial space.

and Boxplot graphs were constructed to illustrate the comparison between the initial situations (1 PO year) and the follow-up (10 PO years), as well as to identify possible discrepant observations.

As the sample was considered homogeneous, it allowed the use of the Student t-test and the nonparametric Mann-Whitney test.<sup>20</sup>

A significance level of 5% was adopted, and hypotheses with descriptive levels (*p*-values) lower than this value were rejected. The analyzes were performed using the Minitab, v.17 statistical program (Minitab LLC., State College, PA, USA).<sup>20</sup>

The study protocol was approved by the institutional ethics committee.

## Results

After evaluating the 13 operated patients, we compared the range of motion at 1 year postoperatively (PO1y) with that found in the evaluation after 10 years (PO10y). The values are illustrated in ►Table 2, which shows us that there was gain in all directions of movement, with an average increase of 5° elevation, 2° lateral rotation and two medial vertebral levels. The values obtained presented a significance level of 5%.

The UCLA scale mean<sup>17</sup> in PO1y was 24 (17-30) and in PO10y was 24.5 points (ranged from 14 to 34), showing that UCLA<sup>17</sup> did not change after 10 years of postoperative follow-up.

In the follow-up of PO1y patients, we had 4 good results (30.8%), 6 reasonable or fair results (46.2%), and 3 (23.1%) patients with poor results. When we compared these results with those of PO10y patients, we found excellent results in 1 case (7.7%), good in 5 (38.5%), reasonable or fair in 3 (23.1%) and poor in 4 patients (30.8%). Regarding the degree of satisfaction, 4 (30.8%) patients were dissatisfied at PO1y, whereas only 2 (15.4%) were dissatisfied at PO10y.

Regarding the radiographic evaluation of the degree of erosion evaluated by the method proposed by Sperling et al<sup>19</sup> and Herschel et al,<sup>11</sup> there was a mean increase of one stage in the wear of the glenoid cavity, during the follow-up, that is, in the mean of PO1y, the patients had an erosion classified as stage II, and, now, in the PO10y, the erosion found was classified as stage III. The full evaluation is in the ►Table 3.

In corrected frontal radiography, using the method proposed by Ohl et al,<sup>18</sup> we obtained the following results: decreased lateral glenohumeral offset, glenohumeral joint space and subacromial space. There was increased glenohumeral cavity depth and proximal humeral head migration, illustrated in ►Table 4. All with statistical significance (*p* > 0.1).

**Table 2** Mobilidade articular média dos pacientes

Mean	PO 1 y	PO 10 y	<i>p</i> -value
Elevation	100°	105°	<i>p</i> > 0.100
External rotation	34°	36°	<i>p</i> > 0.100
Internal rotation	L3	L1	<i>p</i> > 0.100

Source: Institution Medical Archives.

Abbreviations: PO, postoperative, y, years.

**Table 3** Radiographic measurement of the degree of erosion of the glenoid cavity at 1 year and at 10 years postoperatively evaluated by the method proposed by Sperling et al<sup>19</sup>

Grade	PO 1 y n (%)	PO 10 y n (%)
I	01 (08)	–
II	10 (77)	01 (08)
III	01 (08)	09 (69)
IV	01 (08)	03 (23)

Source: Institution Medical Archives.

Abbreviations: PO, postoperative, y, years; n, number.

**Table 4** Evaluation of the radiographic parameters of the shoulder found by the method proposed by Ohi et al<sup>18</sup>

	PO 1 y (mm)	PO 10 y (mm)	PO 1 y–PO 10 y (mm)
Lateral glenohumeral offset	67.3	63.6	3.7
Glenohumeral joint space	2.07	1.15	0.92
Glenoid cavity depth	4.1	8.53	-4.38
Proximal migration	4.42	6.31	-1.88
Subacromial space	8.07	5.38	2.69

Source: Institution Medical Archives.

Abbreviations: PO 1 y, values found one year after surgery; PO 10 y, values found at follow-up after a minimum of 10 years; PO 1 y–PO 10 y, difference between both.

## Discussion

With a minimum follow-up of 10 years, we obtained increased shoulder mobility in all directions and a mean UCLA<sup>17</sup> of 24.5 (regular), that is, a half-point gain compared to the PO1y evaluation. By analyzing separately the increase in glenoid cavity depth (4.3 mm on average), and the decrease in glenohumeral joint space (average 0.9 mm), which were the most evident radiographic alterations, we observed that there was no correlation directly proportional to the UCLA result,<sup>17</sup> which remained around 24.

According to Gadea et al<sup>10</sup> and Smith et al,<sup>21</sup> it is recognized that partial arthroplasty may result in erosion of the glenoid cavity, which is the main cause of clinical deterioration and revision for total arthroplasty. In a study by Herschel et al,<sup>11</sup> 89% of patients developed some degree of erosion of the glenoid cavity, visible on radiographic examination, within a median follow-up of 31 months, but only 10% had indication for surgical revision. The same can be observed in the study by Sperling et al,<sup>19</sup> in which, with 7 years of mean follow-up, only 24% of patients underwent a reoperation, erosion of the glenoid cavity being the most common cause of surgery (90%).

In the present study, we found that all patients had some degree of visible erosion on radiographic examination after a minimum PO10y follow-up. Despite the radiographic evolution found, we obtained satisfactory functional results, with a survival rate of 84.7% of arthroplasties after an average time of 16 years. Cerciello et al<sup>22</sup> found a 72% incidence of glenoid cavity erosion, associated with symptomatology in 6 to 72% of the cases, which supports the results found in our work that erosion is not always associated with symptoms, and, when they exist, they may not be disabling (► Fig. 4).

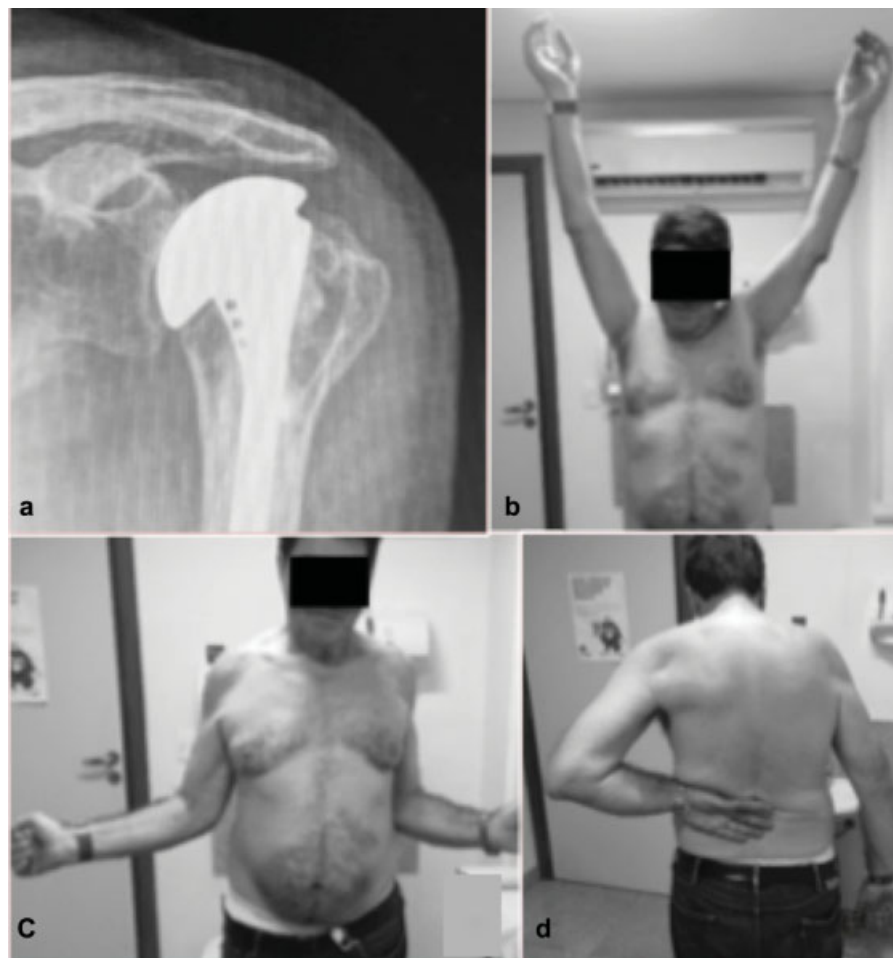
When asked about satisfaction with the surgical outcome, 11 (84.7%) patients were satisfied with the result at the last evaluation (at PO10y), despite the degree of alteration found on radiographic examinations. We believe this is due to a clinical and functional adaptation of patients when performing their daily activities, and, therefore, despite radiographic deterioration, patients no longer feel more incapacitated than before. And as satisfaction is one of the parameters evaluated in the UCLA criteria,<sup>17</sup> this directly affects its result.

Only 2 (15.4%) patients were really dissatisfied with their results. These 2 presented, in the radiographic examination of PO10y follow-up, a severe erosion of the glenoid cavity, classified as grade IV of Sperling et al.<sup>19</sup>

In the first case, the patient presented idiopathic osteonecrosis, affecting the dominant limb. She had grade IV osteonecrosis and concentric arthrosis in the preoperative evaluation. A partial Neer arthroplasty was performed. At PO10y, the patient had 15 points on the UCLA scale,<sup>17</sup> with the range of motion of 80°, 20°, gluteus with pain, and functional disability. Hemiarthroplasty revision procedure for total arthroplasty was indicated. Currently, the patient is in the 5th year after revision, with controlled pain, and range of motion of 80°, 40°, sacrum (20° lateral rotation gain).

The other case is the youngest patient in our series (45 years old). The etiology of necrosis is secondary to sickle cell anemia. The patient is at 12 years postoperatively, with a 14-point UCLA score,<sup>17</sup> range of motion 90°, 0°, L4. At 1 year postoperatively, the patient had a UCLA<sup>17</sup> of 24, with 80°, 20°, gluteus. The operated limb is the dominant limb, but in the contralateral limb the patient also has osteonecrosis of the humeral head, classified as grade II, a fact that is making it very difficult to perform activities of daily living. Therefore, despite the small loss of range of motion during follow-up, we believe that contralateral involvement is contributing to its dissatisfaction and difficulty in adapting. She is in outpatient follow-up in our group, with referral for surgical treatment on the contralateral side, but due to private problems she does not want to have surgery at the moment.

Of the 7 patients who presented unsatisfactory results in the PO10y follow-up, we could observe that prosthesis type Neer II was used in 5 of them; however, from a statistical point of view ( $p > 5\%$ ), there was no difference when using the prosthesis Eccentra and Neer II considering UCLA<sup>17</sup> and the range of motion between the PO1y and PO10y follow-ups.



**Fig. 4** Patient at 13 postoperative years of partial arthroplasty for posttraumatic osteonecrosis. (a) radiographic examination shows decreased glenohumeral joint space and erosion of glenoid cavity. Patient with 34 points in the University of California, Los Angeles (UCLA) classification, with good joint mobility: (b) elevation, (c) lateral rotation and (d) medial.

## Conclusion

The study shows us that the functional results of our patients who underwent partial arthroplasty due to humeral head osteonecrosis were maintained over 10 years. Progression of glenoid cavity erosion was observed; however, the clinical results in 85% of the patients did not correlate with the deterioration of the radiographic aspects found in the current exams.

### Conflict of Interests

The authors declare that there are no conflict of interests.

## References

- Loebenberg MI, Plate AM, Zuckerman JD. Osteonecrosis of the humeral head. *Instr Course Lect* 1999;48:349–357
- Feeley BT, Fealy S, Dines DM, Warren RF, Craig EV. Hemiarthroplasty and total shoulder arthroplasty for avascular necrosis of the humeral head. *J Shoulder Elbow Surg* 2008; 17(05):689–694
- Hernigou P, Flouzat-Lachaniette CH, Roussignol X, Poignard A. The natural progression of shoulder osteonecrosis related to corticosteroid treatment. *Clin Orthop Relat Res* 2010;468(07):1809–1816
- Schoch BS, Barlow JD, Schleck C, Cofield RH, Sperling JW. Shoulder arthroplasty for post-traumatic osteonecrosis of the humeral head. *J Shoulder Elbow Surg* 2016;25(03):406–412
- Parsch D, Lehner B, Loew M. Shoulder arthroplasty in nontraumatic osteonecrosis of the humeral head. *J Shoulder Elbow Surg* 2003;12(03):226–230
- Neer CS. Glenohumeral arthroplasty. *In: Shoulder reconstruction*. Philadelphia: W.B. Saunders; 1990:143–227
- Orfaly RM, Rockwood CA Jr, Esenyel CZ, Wirth MA. Shoulder arthroplasty in cases with avascular necrosis of the humeral head. *J Shoulder Elbow Surg* 2007;16(3, Suppl):S27–S32
- Pollock R, Glasson JM, Djurasovic M, et al. Hemiarthroplasty for glenohumeral osteoarthritis in patients with an intact rotator cuff: results correlated to degree of glenoid wear. *In: AAOS Twelfth Open Meeting, Atlanta GA, February 25, 1996*
- Checchia SL, Santos PD, Miyazaki AN, et al. Osteonecrose da cabeça do úmero: resultados das artroplastias. *Rev Bras Ortop* 2001;36(12):29–36
- Gadea F, Alami G, Pape G, Boileau P, Favard L. Shoulder hemiarthroplasty: outcomes and long-term survival analysis according to etiology. *Orthop Traumatol Surg Res* 2012;98(06): 659–665
- Herschel R, Wieser K, Morrey ME, Ramos CH, Gerber C, Meyer DC. Risk factors for glenoid erosion in patients with shoulder hemiarthroplasty: an analysis of 118 cases. *J Shoulder Elbow Surg* 2017;26(02):246–252

- 12 Schoch BS, Barlow JD, Schleck C, Cofield RH, Sperling JW. Shoulder arthroplasty for atraumatic osteonecrosis of the humeral head. *J Shoulder Elbow Surg* 2016;25(02): 238–245
- 13 Mansat P, Huser L, Mansat M, Bellumore Y, Rongières M, Bonneville P. Shoulder arthroplasty for atraumatic avascular necrosis of the humeral head: nineteen shoulders followed up for a mean of seven years. *J Shoulder Elbow Surg* 2005;14(02): 114–120
- 14 Cofield RH. Total shoulder arthroplasty with the Neer prosthesis. *J Bone Joint Surg Am* 1984;66(06):899–906
- 15 Satterlee CC. Osteonecrosis and other non-inflammatory degenerative diseases of the glenohumeral joint including Gaucher's diseases, sickle cell diseases, hemochromatosis and synovial osteochondromatosis. In: AAOS Instructional Course Lectures. RosemontIL1997: 233–240
- 16 Hawkins JR, Bokor DJ. Clinical evaluation of shoulder problems. In: Rockwood CA, Matsen FA, editors. *The shoulder*. Philadelphia: Saunders; 1990:149–177
- 17 Ellman H, Kay SP. Arthroscopic subacromial decompression for chronic impingement. Two- to five-year results. *J Bone Joint Surg Br* 1991;73(03):395–398
- 18 Ohl X, Nérot C, Saddiki R, Dehoux E. Shoulder hemi arthroplasty radiological and clinical outcomes at more than two years follow-up. *Orthop Traumatol Surg Res* 2010;96(03):208–215
- 19 Sperling JW, Cofield RH, Schleck CD, Harmsen WS. Total shoulder arthroplasty versus hemiarthroplasty for rheumatoid arthritis of the shoulder: results of 303 consecutive cases. *J Shoulder Elbow Surg* 2007;16(06):683–690
- 20 Montgomery DC, Runger GC. *Estatística aplicada e probabilidade para engenheiros*. 6a. ed. Rio de Janeiro: LTC; 2016
- 21 Smith RG, Sperling JW, Cofield RH, Hattrup SJ, Schleck CD. Shoulder hemiarthroplasty for steroid-associated osteonecrosis. *J Shoulder Elbow Surg* 2008;17(05):685–688
- 22 Cerciello S, Morris BJ, Visonà E, et al. No relationship between critical shoulder angle and glenoid erosion after shoulder hemiarthroplasty: a comparative radiographic study. *Arch Orthop Trauma Surg* 2017;137(07):919–923