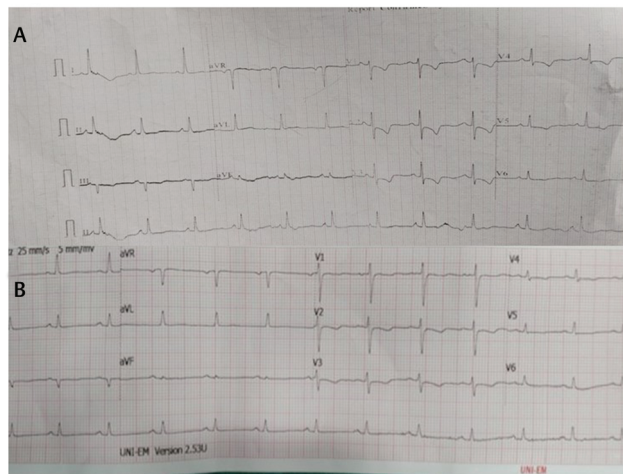

**Fig. 2** (A) Preoperative ECG showing ST depression in lead II, V1–V5. (B) Postoperative ECG showing normalization of ECG changes. ECG, electrocardiogram.

vasopressors were required in the intraoperative period and patient was hemodynamically stable throughout the surgery except for the ECG changes. Postoperative elective ventilation was planned in view of massive blood loss, prolonged surgery, and cerebral edema. Patient was weaned and extubated on first postoperative day (POD). Patient was followed up for 7 days. Serial 12-lead ECG was recorded on POD 1–7, which revealed gradual normalization of ST-T changes and T wave inversions. ► **Fig. 2B** shows the ECG on the 7th day, which depicted complete resolution of abnormal ECG changes. The commonly reported findings are ST elevation with T inversion; however, in our case, we found ST depression and T inversion. The ECG findings were not associated with any signs and symptoms but as a part of screening, Trop T and 2D echo were done. Trop T was negative and echocardiography was normal. As the patient was stable hemodynamically and had no complains of chest pain and stable condition postoperatively, she was not subjected to serial Trop T, serial 2D echo, or invasive cardiac angiogram. Invasive cardiac angiogram should be reserved for cases of abnormal echocardiography showing regional motion abnormalities. Currently, there are no guidelines particularly for neurosurgical patients; however, some studies have impressed upon

the use of ECG, serum biomarkers, and echocardiography for preoperative evaluations.<sup>4</sup> The American College of Cardiology (ACC)/American Heart Association (AHA) task force has reserved invasive tests such as cardiac angiogram for grossly abnormal echocardiograph like regional wall motion abnormalities or abnormal septal motions which were absent in our case. In absence of abnormalities in echocardiography, no further testing is recommended.<sup>5</sup>

From this report we want to emphasize that neurological insult has a bearing on ECG which can have manifestations or may remain subtle. In our case, the ECG changes started resolving postoperatively and complete normalization was seen by the end of first week. ECG changes in neurosurgical patient can be due to organic heart disease or secondary to neurological insult. The later tend to resolve with treatment of neurological insult. Cardiac status of the patient should be evaluated from relevant history, clinical examination, biomarkers, and echocardiography. Early treatment of neurological insult should help in resolution of ECG changes. Documentation of persistence/resolution of such ECG changes may be helpful while evaluating the patient in future.

#### Conflict of Interest

None declared.

#### Reference

- 1 Manikandan S. Heart in the brain injured. *J Neuroanaesth Crit Care* 2016;3:5:12–S154.
- 2 Yogendranathan N, Herath HM, Pahalagamage SP, Kulatunga A. Electrocardiographic changes mimicking acute coronary syndrome in a large intracranial tumour: A diagnostic dilemma. *BMC Cardiovasc Disord* 2017;17(1):91
- 3 Bhagat H, Narang R, Sharma D, Dash HH, Chauhan H. ST elevation—an indication of reversible neurogenic myocardial dysfunction in patients with head injury. *Ann Card Anaesth* 2009;12(2):149–151
- 4 Lieb K, Selim M. Preoperative evaluation of patients with neurological disease. *Semin Neurol* 2008;28(5):603–610
- 5 Fleisher LA, Fleischmann KE, Auerbach AD, et al. 2014 ACC/AHA guideline on perioperative cardiovascular evaluation and management of patients undergoing noncardiac surgery: executive summary: a report of the American College of Cardiology/American Heart Association Task Force on Practice Guidelines. *Circulation* 2014;130(24):2215–2245



Correspondence

## Intraoperative Predissection Aneurysm Rupture: No Less than a Catastrophe!

Nayani Radhakrishnan<sup>1</sup> Rajendra S. Chouhan<sup>2</sup> Indu Kapoor<sup>2</sup> Charu Mahajan<sup>2</sup>

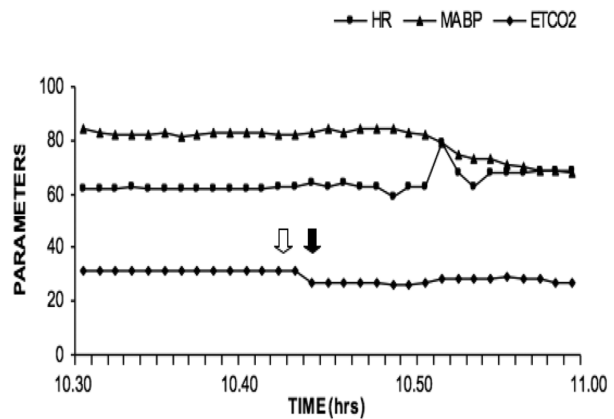
<sup>1</sup>Department of Anaesthesia and Critical Care, Army Hospital Research and Referral, New Delhi, India

<sup>2</sup>Department of Neuroanaesthesiology and Critical Care, All India Institute of Medical Sciences (AIIMS), New Delhi, India

**Address for correspondence** Charu Mahajan, MD, DM, Department of Neuroanaesthesiology and Critical Care, Neurosciences Centre, All India Institute of Medical Sciences (AIIMS), New Delhi 110029, India (e-mail: charushrikul@gmail.com).

Anesthetic management for clipping of intracranial aneurysm may be complicated by intraoperative rupture at various surgical stages. Sudden increase in transmural pressure (TMP) caused by either sudden increase in mean arterial pressure (MAP) or decrease in intracranial pressure (ICP) may be responsible for it. Acute hyperventilation causing intraoperative aneurysm rupture has not been reported earlier, even though such a concern exists theoretically.

A 45-year-old man, weighing 60 kg, presented with history of headache, vertigo, and transient loss of consciousness, for the past 3 days. Computerized tomography scan of brain demonstrated subarachnoid hemorrhage (SAH) in interhemispheric fissure. Cerebral digital subtraction angiography revealed anterior communicating artery aneurysm. He had no other systemic illness and all routine investigations were normal. Patient was scheduled for left pterional craniotomy and aneurysm clipping. In the operation theater, noninvasive monitoring was started with 5-lead electrocardiography, automated blood pressure, and pulse oximetry. Anesthesia was induced with fentanyl (2 µg/kg) and thiopentone (5 mg/kg). Xylocard (1.5 mg/kg) was administered to attenuate the pressor response and tracheal intubation was facilitated with rocuronium (1 mg/kg). Anesthesia was maintained with isoflurane in oxygen and nitrous oxide (1:2) mixture along with intermittent boluses of fentanyl and vecuronium. Mechanical ventilation was adjusted to maintain end-tidal carbon dioxide (EtCO<sub>2</sub>) around 32 mm Hg. Invasive blood pressure, central venous pressure, and nasopharyngeal temperature were continuously monitored. After craniotomy, the dura appeared slightly tense. Various causes likely to increase ICP were ruled out; for example, hypercarbia (EtCO<sub>2</sub> 32 mm Hg, PaCO<sub>2</sub> 33 mm Hg), hypoxia (SpO<sub>2</sub> 99%), higher concentration of volatile anesthetic (minimum alveolar concentration [MAC]: 1.1), high airway pressure (18 mm Hg) or central venous pressure (CPV) (8 mm Hg), light anesthesia, head down positioning, or excessive rotation of the neck were ruled out. The patient was hemodynamically stable till this stage. By this time, mannitol (1 g/kg) infusion had already been administered over approximately 30 minutes. There was not much improvement even after switching off nitrous oxide, so minute ventilation was increased in an attempt to achieve moderate hypocarbia. Over the next minute, EtCO<sub>2</sub> decreased from 32 mm Hg to 27 mm Hg. At this point, the surgeons informed that the dura had become dark in color and the brain had become "stony hard." During this period, there was no change in blood pressure (► Fig. 1). The surgeons suspected aneurysm rupture and decided to proceed with the surgery. After opening the dura, there was profuse bleeding, thereby blinding the surgeon. Left frontal lobectomy was performed to achieve



**Fig. 1** Record of heart rate (HR), mean arterial blood pressure (MABP), and end-tidal carbon dioxide (EtCO<sub>2</sub>) at 1-minute interval during the episode of aneurysm rupture.

adequate and urgent exposure. Systolic blood pressure was maintained around Hg by administration of crystalloids, colloids, and blood. The ruptured aneurysm was successfully clipped following temporary clip application on left internal carotid artery for 20 minutes. Total estimated blood loss was approximately 3.5 L, which was adequately replaced. Rest of the intraoperative period was uneventful. Postoperatively, the patient was electively ventilated overnight in the neurointensive care unit. The patient was extubated on the first postoperative day and rest of his hospital stay was unremarkable. Patient was discharged on postoperative day 8 with Glasgow Coma Scale score of 15 with slight weakness in right lower limb.

Intraoperative aneurysm rupture is described at three specific periods, that is, early or predissection (7%), during dissection (48%), and during clip application (45%).<sup>1</sup> Aneurysm rupture in early or predissection period is mostly due to sudden acute increase in TMP gradient. We excluded all factors which could contribute to raised ICP before resorting to hyperventilation, the effect of which was immediate. This might have increased TMP, resulting in aneurysm rupture. Various factors such as stress response during endotracheal intubation, pin fixation, vibrations of power instruments during craniotomy, change in ICP by mannitol, and various aneurysmal factors have been implicated in early intraoperative rupture of aneurysms.<sup>1,2</sup> In our patient, rupture seems to have occurred after craniotomy as it turned stony hard only after hyperventilation. There are reports of adenosine being successfully used to manage inadvertent intraoperative aneurysmal rupture during dissection or clipping

phase.<sup>3</sup> But, whether it is safe or has a beneficial role during predissection phase, is not clear. This patient belonged to a good SAH grade and theoretical concerns of hyperventilation have been clearly defined.<sup>4</sup> Yet, to achieve relaxed brain, we resorted to hyperventilation as a quick maneuver to facilitate surgical exposure. However, prompt aneurysm obliteration together with maintenance of normotension during the procedure resulted in good outcome of the patient.

In conclusion, we reiterate the theoretical teaching that during aneurysm surgery, hyperventilation should not be instituted acutely in good-grade patients to decrease ICP, especially before dural opening. If intracranial pressure is to be decreased then utmost care should be taken not to suddenly increase the TMP gradient.

#### Conflict of Interest

None declared.

#### References

- 1 Batjer H, Samson D. Intraoperative aneurysmal rupture: incidence, outcome, and suggestions for surgical management. *Neurosurgery* 1986;18(6):701–707
- 2 Rosenørn J, Westergaard L, Hansen PH. Mannitol-induced rebleeding from intracranial aneurysm. Case report. *J Neurosurg* 1983;59(3):529–530
- 3 Luostarinen T, Takala RS, Niemi TT, et al. Adenosine-induced cardiac arrest during intraoperative cerebral aneurysm rupture. *World Neurosurg* 2010;73(2):79–83, discussion e9
- 4 Guy J, McGrath BJ, Borel CO, Friedman AH, Warner DS. Perioperative management of aneurysmal subarachnoid hemorrhage: Part 1. Operative management. *Anesth Analg* 1995;81(5):1060–1072



Correspondence

## Dry Spinal Tap

Bessie Kachulis<sup>1</sup> Apostolos J. Tsiouris<sup>2</sup> Priscilla Nelson<sup>1</sup> Irene Stadnyk<sup>1</sup>

<sup>1</sup>Department of Clinical Anesthesiology, Weill Cornell Medicine, New York, New York, United States

<sup>2</sup>Department of Clinical Radiology, Weill Cornell Medicine, New York, New York, United States

*J Neuroanaesthesiol Crit Care*:2021;8:82–83

Spinal catheter placement may be challenging for the anesthesiologist, as it is performed blindly using a landmark-based technique. Understanding the patient's spine anatomy, optimal patient position, and clinical experience contribute to successful placement.<sup>1</sup> Spinal deformities, congenital spinal stenosis, chronic degenerative disease, and obesity increase the difficulty of placement.

The position of the needle and catheter in the subarachnoid space is confirmed clinically by the presence of free-flowing cerebrospinal fluid (CSF). The absence of CSF is considered a failed attempt to access the thecal sac. This could be contributed to needle misplacement, needle blockade, previous spinal surgery, or low-CSF pressure.<sup>2</sup>

We experienced a situation where a lumbar spinal drain placement was attempted under general anesthesia in the

**Address for correspondence** Bessie Kachulis, MD, Department of Clinical Anesthesiology, Weill Cornell Medicine, 525E 68th Street Box 124, New York, NY 10065, United States (e-mail: kachuli@med.cornell.edu).

lateral position, using a standard spinal drain kit. The patient was a female in her late fifties with normal body habitus undergoing surgery for thoracoabdominal aneurysm repair. Spinal drain was placed for spinal cord protection. Initially, the needle was suspected to be in the correct location, based on the anatomic landmarks, a “give sensation,” and a very small amount of fluid which filled the spinal needle to the hub. No free-flowing CSF was noted. Unfortunately, confirmation of correct spinal drain catheter placement by clinical standards was impossible, since there was drainage, even with aspiration. The catheter was removed and subsequent trials to access CSF by other experienced anesthesiologists were unsuccessful. A neuroradiologist was consulted, and the catheter was placed fluoroscopically. Correct positioning of the needle and then the catheter was confirmed by contrast

**Published online**  
August 26, 2020

**DOI** <https://doi.org/10.1055/s-0040-1715358>  
**ISSN** 2348-0548.

©2020. Indian Society of Neuroanaesthesiology and Critical Care. This is an open access article published by Thieme under the terms of the Creative Commons Attribution-NonDerivative-NonCommercial-License, permitting copying and reproduction so long as the original work is given appropriate credit. Contents may not be used for commercial purposes, or adapted, remixed, transformed or built upon. (<https://creativecommons.org/licenses/by-nc-nd/4.0/>). Thieme Medical and Scientific Publishers Pvt. Ltd. A-12, 2nd Floor, Sector 2, Noida-201301 UP, India