

CASE REPORT

Obstructive Jaundice: A Late Presentation of Blunt Abdominal Trauma of Extrahepatic Biliary Tract Treated Endoscopically

Mallikarjun Patil, Keyur A Sheth, Adarsh CK

Department of Gastroenterology, St John's Medical College, Sarjapura Road, Bangalore, India

ABSTRACT

Common bile duct (CBD) injuries from blunt abdominal trauma are rare. The diagnosis is often more difficult with incomplete injuries that result in a delayed presentation. We present a case of CBD injury due to trauma with delayed presentation. Magnetic resonance cholangiopancreatography demonstrated the nature of extrahepatic bile duct and was treated successfully with endoscopic stent placement. (*J Dig Endosc* 2013;4(1):16-18)

Key Words: Obstructive jaundice - Common bile duct stricture - Cholestatic hepatitis - Endoscopic retrograde cholangiopancreatography

Introduction

Extrahepatic bile duct is located deep within the abdomen and is well protected by liver, ribs and mesentery. Obviously, injury of the extrahepatic biliary ducts following blunt abdominal trauma is quite rare. Extrahepatic biliary tract injuries occur in 3 – 5% of all abdominal injuries, especially from penetrating trauma.^{1,2} We report a case of stricture of the suprapancreatic portion of the common bile duct who presented with cholestasis 5 months after blunt abdominal trauma.

Case Report

A 45-year-old male patient presented to us with jaundice associated with itching for 8 days. He had no abdominal pain, vomiting, fever or melena. Jaundice was not preceded by prodromal symptoms. He is diabetic for last 1 year and had controlled blood sugars on metformin. He had blunt abdominal trauma 5 months back due to road traffic accident. He had gangrenous segment of proximal half of transverse mesocolon surrounded by a large hematoma 15x15 cm along with hemoperitoneum and hemothorax.

Resection of transverse colon with ascending colon colostomy and drainage of hemoperitoneum and hemothorax was done. On follow up, colostomy reversal was done. On this admission he was hemodynamically stable, afebrile, icteric and scratch marks were seen. Systemic examination was normal. Laboratory parameters revealed haemoglobin of 14.1gm/dl (normal 13-18gm/dl), leucocyte count of 4700/mm³ (normal 4000-11000/mm³), and platelet count of 1.95laks/mm³ (normal 1.5-4 lakh/mm³). Prothombin time was normal as control. Liver biochemical tests showed total bilirubin of 8.99 mg/dl with conjugated bilirubin of 6.94 mg/dl, aspartate aminotransferase 58 IU/L (normal 15-37 IU/L), alanine aminotransferase 107 IU/L (normal 30-65IU/L), alkaline phosphatase 320 IU/L (normal 50-136 IU/L) and gamma glutamyl transferase 1340 IU/L (normal

Reprints requests and correspondence:

Dr. Mallikarjun Patil,
Associate Professor,
Department of Gastroenterology,
St. John's Medical College, Sarjapura Road, Bangalore, India
Ph No. 080-22065239; Fax No: 080-25520499
Email: drmalli_arjun@yahoo.co.in

15-85 IU/L). His serum amylase and lipase were within normal limits.

His ultrasonography of abdomen revealed hepatomegaly with dilatation of intrahepatic biliary ducts (IHBD) and proximal CBD suggestive of mid CBD stricture. There was no evidence of pancreatitis. Magnetic resonance cholangiopancreatography (MRCP) showed dilatation of both IHBD and proximal CBD with abrupt cut-off of the suprapancreatic portion of the CBD suggestive of CBD stricture (Figure 1). An endoscopic retrograde cholangiography (ERC) was performed; cholangiogram revealed a narrowing of the mid CBD with ductal dilatation above the narrowed portion (Figure 2), suggestive of post traumatic biliary stricture. Endoscopic biliary sphincterotomy using a pull-type papillotome was performed. Brushing and biopsy of the narrowed part were taken. Dilatation of stricture was done using 5,7 and 10Fr schoendra dilators. A 10Fr plastic stent, 7 cm in length was placed in CBD (Figure 3). The

cytology and biopsy results were negative for malignancy. He was asymptomatic post-procedure with decrease in total bilirubin levels. At 1 month, his liver biochemical tests were normal. At 3 months, cholangiography performed was normal and the biliary stent was removed after observing normal passage of contrast dye (Figure 4).

Discussion

CBD injuries from blunt abdominal trauma are rare. In all abdominal trauma victims, extrahepatic biliary ducts (EHD) tract injuries occur in 3% to 5%, out of which 85% are due to penetrating wounds and 15% due to blunt trauma. Among the blunt trauma injuries, gall bladder alone constitutes 85%. Injury of the EHD after blunt trauma is a relatively rare entity, since the bile ducts are located deep within the abdomen and are protected by the ribs, liver and mesentery. The diagnosis is more difficult with incomplete injuries since

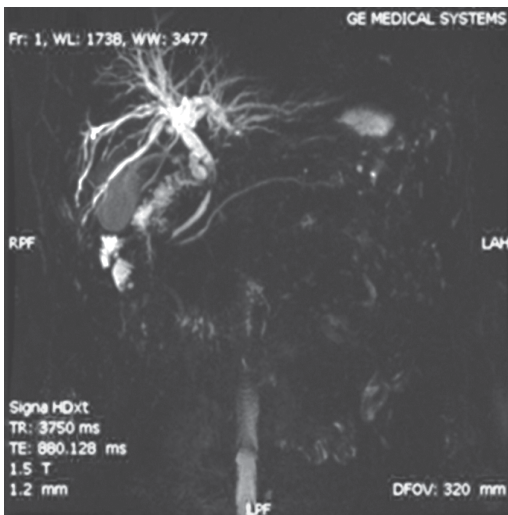


Figure 1: MRCP showing CBD stricture

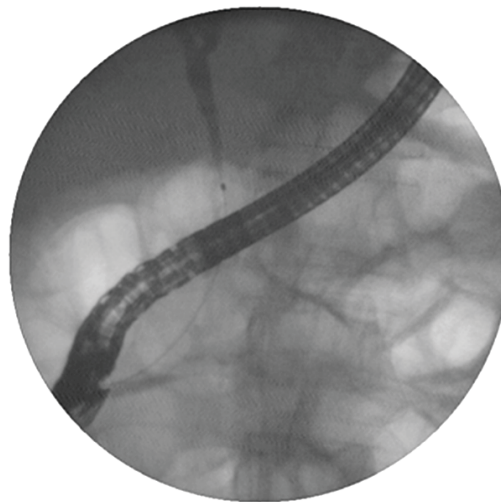


Figure 2: ERC showing CBD stricture

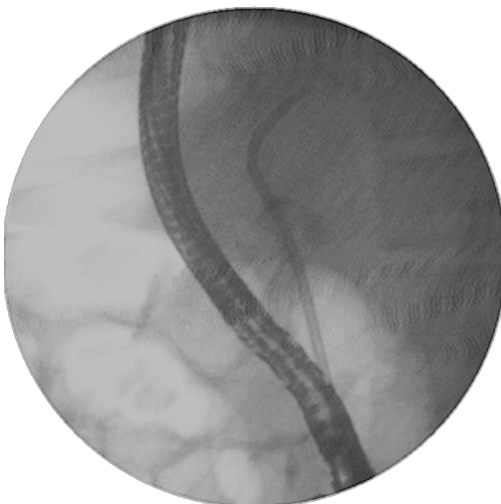


Figure 3: ERC showing CBD stenting

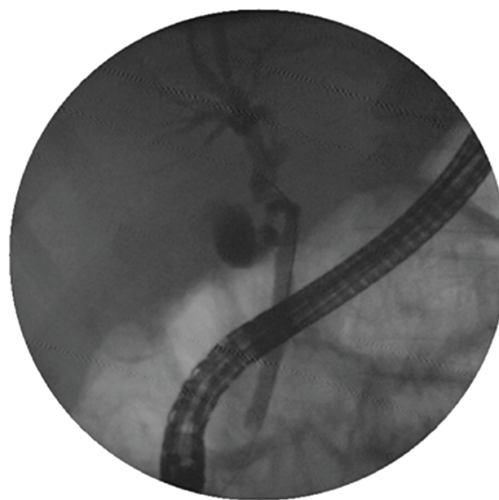


Figure 4: ERC showing resolution of CBD stricture

they result in a delayed presentation, days to months post injury.¹

The EHD lacerations have typical clinical course of initial injury followed by shock which usually lasts for only few hours. This phase is followed by asymptomatic period of varying days which finally leads to progressive painless jaundice or abdominal distension due to bile ascites in some cases.² Peritoneal findings like severe abdominal pain, guarding and rigidity are usually absent. As compared to rupture or complete division, the clinical presentation is often delayed owing to the subtle nature of initial injury. A small tear with subsequent bile leakage may not be diagnosed initially clinically or with laparotomy. As noted in our case, this injury was not observed at initial laparotomy despite mobilization of the head of the pancreas and duodenum.

The pathophysiology causing injury to the EHD is unknown, but the following have been documented: 1) extrinsic compression of the ductal system on the vertebral column 2) the transmitted rise in intra-ductal pressures causing "blow-out" of the duct due to external compression of the gallbladder 3) tearing of the ductal system at the junction of its fixed and mobile portions.² On the basis of their location, proposed mechanisms of EHD strictures after blunt trauma can be categorised into suprapancreatic and intrapancreatic. In suprapancreatic EHD strictures the proposed mechanisms are: 1) ductal tear and local inflammation which is followed by fibrosis and stricture formation 2) bile duct blood supply disruption and 3) bile duct compression by an intramural or extrabiliary hematoma. In intrapancreatic EHD strictures the possible mechanisms include posttraumatic pancreatitis with swelling of the pancreatic head, leading to compression of the intrapancreatic portion of the CBD; which usually resolves as the swelling subsides.³ We postulate that in our case, duct compression by extrabiliary hematoma might have played role in stricture formation.

Laboratory evaluation usually reveals cholestatic pattern on liver biochemical tests, but is frequently misleading because of the multiple other causes of jaundice following major abdominal trauma. This includes resolving haematomas, haemolysis from multiple blood transfusions, biliaryomas and drug toxicity. This misleading causes usually leads to delay in diagnosis and treatment. The findings on abdominal imaging are nonspecific which includes a suprapancreatic or intrapancreatic biliary stricture. We propose MRCP to be the initial investigation of choice. ERCP should be used as therapeutic rather than diagnostic tool in patients with EHD strictures. ERCP would be technically more challenging and prone to complications due to prior laparotomy or intraabdominal sepsis.

A history of blunt abdominal trauma can aid in confirming the diagnosis. Typical findings of cholestatic pattern on liver biochemical tests, imaging showing suprapancreatic biliary stricture and benign findings on brushings confirms

the diagnosis. However, other differential diagnosis to consider includes liver lacerations, hematomas, abscesses and vascular injuries, which may all result from blunt abdominal trauma and lead to jaundice. Anesthetic toxicity, viral hepatitis, drug toxicity and operative stress on pre-existing liver disease should be considered as potential causes. Acute acalculous cholecystitis must also be considered since it is known to occur in both traumatized and surgical patients.³

The treatment options for an extrahepatic biliary leak have broadened. In some cases, definitive nonoperative interventions may be indicated to provide durable and definitive biliary drainage, which requires intact bilioenteric continuity. Most often this is indicated with a small bile leak, which is detected postoperatively and treated with stent placement. Short biliary strictures (less than 2cm in length) may also be appropriate for a trial of nonoperative therapy like balloon dilation and stenting. In operative repair, the options include primary repair over a T tube and bilioenteric diversion. A durable repair depends on principles like creation of a tension-free, mucosa-to-mucosa anastomosis with healthy, nonischemic bile duct. Endoscopic therapy for biliary stricture following blunt abdominal trauma is associated with good long-term outcome and low morbidity. Hence, endoscopic stenting is the treatment of choice for biliary strictures following blunt abdominal trauma and surgery is indicated only if endoscopic intervention fails.^{3,4}

Conclusions

This report describes the delayed presentation of extrahepatic bile duct injury in a 47-year-old case. Patient presented with features of deep cholestasis 5 months following blunt abdominal trauma. While this injury was overlooked at initial presentation of trauma indicating difficulty in identifying all injuries in patients with multiple injuries. Use of non-invasive imaging tools is quite useful in recognition of bile duct injuries and endoscopic treatment has resolved the problem.

References

1. Balzarotti R, Cimbanassi S, Chiara O, Zabbialini G, Smadja C. Isolated extrahepatic bile duct rupture: a rare consequence of blunt abdominal trauma. Case report and review of the literature. *World J Emerg Surg* 2012;7:16.
2. Burt TB, Nelson JA. Extrahepatic biliary duct trauma - A spectrum of injuries. *West J Med* 1981;134:283-9.
3. Kang DO, Kim TH, You SS, Min HJ, Kim HJ, Jung WT, Lee OJ. Successful endoscopic treatment of biliary stricture following mesenteric tear caused by blunt abdominal trauma. *World J Gastroenterol* 2008;14:2277-9.
4. Haney C, Pappas T. Management of Common Bile Duct Injuries. *J Min Access Surg* 2005;1:53-58.

Source of support: Nil; Conflict of interest: none declared