

## ORIGINAL ARTICLE

**Direct Laryngoscopy Using a Videogastroscope : A New Technique**Vijant Singh Chandail, Vinu Jamwal, J Paul Kanotra<sup>1</sup>Postgraduate Department of Medicine and <sup>1</sup>Department of ENT Acharya Shree Chander College of Medical Sciences & Hospital (ASCOMS), Sidhra, Jammu, India**ABSTRACT**

**Background and objectives:** Although indirect laryngoscopy is commonly used method for evaluation of laryngeal disorders in outpatient Ear, Nose and Throat Department (ENT) but proper and accurate diagnosis is not possible in every patient. The direct laryngoscopy using fiberoptic- or video- laryngoscopy has been shown to be a valuable tool in the examination of laryngeal and supraglottic anatomy and pathology. Our goal was to develop a new diagnostic method wherein direct laryngoscopy can be performed by videogastroscope which unlike fiberoptic- or video- laryngoscopy, is readily available at most of the centres.

**Methods:** Between May 2009 and December 2009, 1462 consecutive patients underwent indirect laryngoscopy for evaluation of laryngeal disorders at ENT outpatient department. Fifty-two (93.6%) consecutive patients who had unsuccessful, inconclusive or incomplete examination underwent direct laryngoscopy with videogastroscope.

**Results:** The study group consisted of 39 males and 13 females with mean age of  $34.8 \pm 11$  years (range 14 to 58 years). The following abnormalities were found in vocal cords in 31 (59.6%) patients: cancer in 8 patients; leukoplakia, 6; cases, nodules, 6; palsy, 5; epitheloid granuloma, 2; submucosal hemorrhages, 2; and polyp in 2.

**Conclusions:** Direct laryngoscopy using videogastroscope is safe, feasible and highly accurate for the diagnosis of laryngeal disorders. (*J Dig Endos* 2011;2(1):6-8)

**Keywords:** Laryngoscopy - Videogastroscope - Flexible laryngoscope - Vocal cord - Laryngeal examination

**Introduction**

Routinely indirect laryngoscopy is the initial diagnostic tool for evaluation of the disorders of the larynx. But an Ear, Nose and Throat (ENT) surgeon has to resort to methods of direct laryngoscopy in certain situations where the laryngeal examination is unsuccessful, incomplete or unsatisfactory. Direct laryngoscopy can be accomplished by rigid-, fiberoptic- or video-laryngoscope. With the exception of videolaryngoscope, all other techniques suffer from inherent limitations of maneuverability, narrower field of vision and documentation. Laryngeal endoscopy is a most useful and effective method of evaluation and documentation of patients with laryngeal disorders presenting to the ENT outpatient department. It is of great value for making accurate

diagnosis and planning proper treatment. Direct laryngoscopy can be accomplished with either a flexible fiberscope or videolaryngoscopy. The fiberoptic laryngoscopy is performed using a flexible laryngoscope, with a working channel that allows aspiration of the secretions that would otherwise obscure the vision and carry a risk of aspiration.<sup>[1,2]</sup> There are limitations of fiberoptic

Reprints requests and correspondence:

Dr. Vijant Singh Chandail, MD;DM

Lecturer, Medicine

Government Medical College, Jammu, India

10, Jai Niwas; Amphalla; Jammu; J&K; India Pin- 180001

e-mail: vijantchandail@yahoo.co.in

Received: 26th Sep 2010

Accepted: 12th Dec 2010

laryngoscopy because it requires nasal anesthesia, scope insertion is done through the nasal route which may not be comfortable for most of the patients, and is difficult to perform in patients with severely deflected nasal septum (DNS) and hypertrophied turbinates. The technique of using a gastroscope for performing laryngoscopy is exciting but has been limited in the past because of the large diameter of most of the gastroscopes.[3] With the advent of slim gastroscopes, laryngoscopy can be readily performed with gastroscope. Furthermore the gastroscope provides four-way movement, an excellent ability to suck blood and secretions under direct vision, and a magnified and digital view of the structures. Moreover the fiberoptic- or video- laryngoscope is not available at all the hospitals or day care centres. We propose a method where in laryngoscopy can be done by videogastroscope which is readily available at most of the centres.

## Methods

This was a prospective study conducted jointly by the departments of Medicine and ENT; ASCOMS Sidhra; Jammu, India between May 2009 and December 2009. All consecutive patients with suspected laryngeal disorders underwent indirect laryngoscopy outpatient ENT department. Patients in whom the indirect laryngoscopy was incomplete, inconclusive or not possible because of either an overhanging or large epiglottis, uncooperative patient or failure to visualise the anterior most part of the vocal cords, were referred to the department of Medicine for undergoing direct laryngoscopy with videogastroscope. Patients were excluded in whom proper examination was not possible due to strong gag reflex. The procedure was done after obtaining written informed consent from the patients. Premedication was done with 15% lidocaine topical aerosol spray in order to anesthetize the oropharynx and hypopharynx. Laryngoscopy was performed by a Gastroenterologist using a gastroscope (Olympus GIF- V70 Japan; insertion diameter of 9.2mm; 2.8mm channel) with the ENT surgeon also simultaneously visualising the procedure.

The gastroscope was introduced with the patient in left lateral position with simultaneous visualization of the uvula, posterior one-thirds of the tongue, aryepiglottic folds, and valleculae. Then the gastroscope was positioned just above the larynx to visualize the oropharynx, pyriform fossae, true and false vocal cords and their movements. All abnormal findings were recorded. The biopsy was taken wherever indicated either during the same procedure, or subjecting the patient to rigid laryngoscopy if it was not possible to perform biopsy using the gastroscope. The diagnosis was confirmed with histopathology reports.

## Results

During the study period, a total of 1462 patients underwent indirect laryngoscopy in the department of ENT.

Of them 52 patients (3.6%) were referred for direct laryngoscopy with videogastroscope. and constituted the study group. There were 39 males and 13 females with mean age of  $34.8 \pm 11$  years and range of 14 to 58 years. The indications for laryngoscopy included hoarseness of voice, foreign body

**Table 1: Abnormal findings in 31 patients**

Abnormal findings	Number of cases
Vocal cord growth	8
Vocal cord leukoplakia	6
Vocal cord nodules	6
Vocal cord palsy	5
Vocal cord epitheloid granuloma	2
Vocal cord submucosal hemorrhages	2
Vocal cord polyp	2

sensations in throat, hemoptysis, and dysphagia. The abnormalities were seen in 31 of 52 patients (59.6%) (Table 1). The abnormalities included vocal cord growth in 8 patients (Figures 1 and 2); vocal cord leukoplakia in 6 patients (Figure 3); vocal cord nodules in 6 patients (Figure 4); vocal

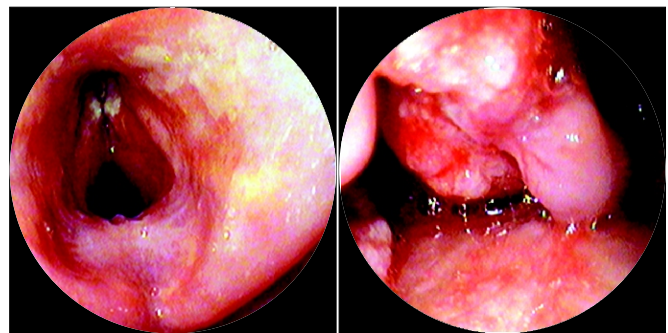


Figure 1: Vocal cord growth

Figure 2: Vocal cord growth

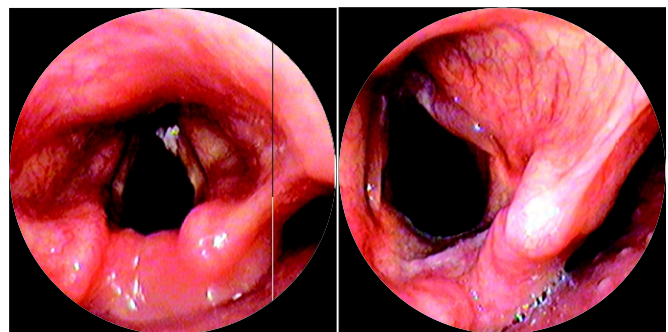


Figure 3: vocal cord leukoplakia

Figure 4: Vocal cord nodule

cord palsy in 5 patients; vocal cord epitheloid granuloma in 2 patients (Figure 5); vocal cord submucosal hemorrhages in 2 patients and vocal cord polyp in 2 patients (Figure 6 and 7). No complications were reported.

All these findings were confirmed histopathologically by biopsy.

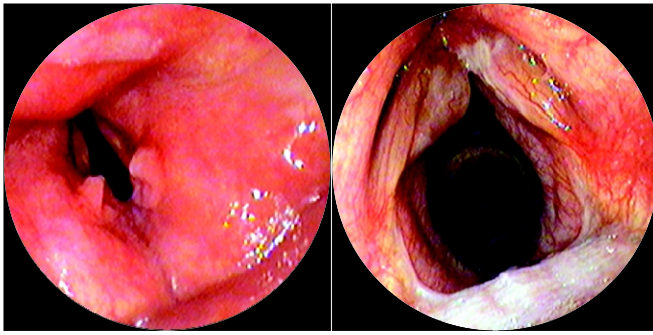


Figure 5: Vocal cord epitheloid Figure 6: vocal cord polyp granuloma

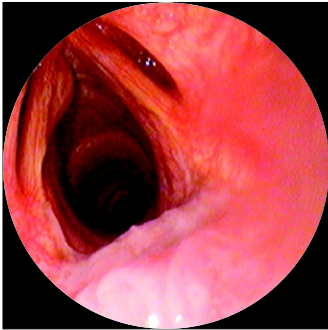

Figure 7: Vocal cord polyp

## Discussion

Our study confirmed that videogastroscope is a most useful and effective method for direct laryngoscopy. Videogastroscope can be safely and effectively used to visualise the laryngeal anatomy. Though there is paucity of data on the use of videogastroscope for laryngoscopy, but our study revealed that videogastroscope was helpful in for making accurate diagnosis in additional 31 cases in whom the ENT surgeon was unable to visualize the whole of the larynx because of limitations. A variety of abnormalities including cancers, nodules, polyps, leukoplakia and granulomas were identified which would have been missed otherwise or would have required an additional procedure using rigid, fiberoptic or video laryngoscopy. Moreover there were no complications associated with the procedure and all the 52 patients tolerated the procedure well and did not report any discomfort as they were adequately anesthetized. The gastroscope was highly useful for visualising the laryngeal anatomy. Although we will not advocate gastroscope as a substitute for fiberoptic

laryngoscope, but it can be used to perform laryngoscopy at centres where fiberoptic laryngoscopes are not available.

Laryngeal endoscopy has been shown to be useful in accurate diagnosis and treatment of laryngeal disorders.[4,5] A large number of studies have established that the use of the video laryngoscope eases tracheal intubations in patients with expected difficult intubations. The view of the laryngeal entrance is significantly improved, with a decreased number of optimizing manoeuvres and in less time. Overall, these improvements of the conditions for tracheal intubations result in a significantly higher success rate of tracheal intubations.[6-8]

## Conclusion

In conclusion, videogastroscope is a safe, feasible and effective tool for direct laryngoscopy. It should be employed for undertaking laryngeal examination in centres where facilities for fiberoptic laryngoscopy or videolaryngoscopy are not available.

## References

1. Schindler O, Ruoppolo G, Schindler A. Deglutologia. Torino: Ed. Omega; 2001.
2. Bastian RW. Videoendoscopic evaluation of patients with dysphagia: an adjunct to the modified barium swallow. *Otolaryngol Head Neck Surg* 1991;104:339-50.
3. Naganoab H, Yoshifukubc K, Kuronoc Y. A useful procedure for observing the cervical esophagus via the hypopharynx. *Auris Nasus Larynx* 2010;37:713-9.
4. Schindler A, Capaccio P, Ottaviani F. Videoendoscopic surgery for inaccessible glottic lesions. *J Laryngol Otol* 2005; 119:899-902.
5. Eller R, Ginsburg M, Lurie D, Heman-Ackah Y, Lyons K, Sataloff R. Flexible laryngoscopy: a comparison of fiber optic and distal chip technologies. Part 1: vocal fold masses. 2008;22:746-50.
6. Hhhh Kaplan MB, Hagberg CA, Ward DS, et al. Comparison of direct and video-assisted views of the larynx during routine intubation. *J Clin Anesth* 2006;18:357-62.
7. Kaplan MB, Ward DS, Berci G. A new video laryngoscope-an aid to intubation and teaching. *J Clin Anesth* 2003;14:620-6
8. Enomoto Y, Asai T, Arai T, Kamishima K, Okuda Y. Pentax-AWS, a new videolaryngoscope, is more effective than the Macintosh laryngoscope for tracheal intubation in patients with restricted neck movements: a randomized comparative study. *Br J Anaesth* 2008;100:544-8.

Source of support: Nil; Conflict of interest: none declared