

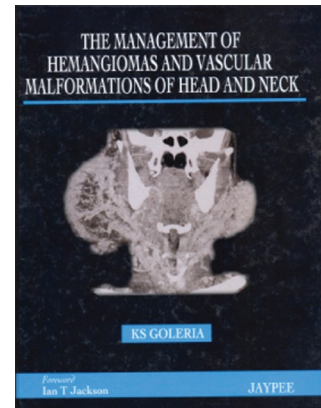
Book Review

The Management of Haemangiomas and Vascular Malformations of the Head and Neck

K. S. Goleria

Edition 2011

Jaypee Brothers Medical Publishers (P) Ltd.
Total no. of pages 221



The Management of Haemangiomas and Vascular Malformations of the Head and Neck is a unique book on a very difficult clinical problem, the management of which has evolved over the years into an excellent example of multidisciplinary management. Prof. K. S. Goleria, the principal author of this book, who has contributed 6 out of its 10 chapters, has poured into them all his experience and knowledge in order to produce a perfect elixir of wisdom and sagacity. It is very easy to look back into the clinical days gone by and recount how individual cases were managed. But in this book, the author has done much more; he has succeeded in formulating guidelines for investigating and principles for treating these lesions depending on two very definite parameters – size of the vascular channels and the intensity of blood flow in them – and thus given a road map to make life easy for future adventurers to tread these difficult woods.

In the very first chapter, the author catches the imagination of the readers by a very practical “management-oriented classification.” The author very wisely suggests that as these lesions owe their identity to the presence of various channels, it is the behaviour of the dominant channels that decides the behaviour

of a particular lesion, which in turn is dependent upon their location in the vascular tree, their size and the rate of flow through them. This then goes on to decide both the investigative modalities to identify these lesions and the therapeutic modalities they would respond to, such as lasers, radio frequency (RF), embolisation and surgery.

The second chapter on imaging has been authored by Dr. Srinivas Desai and he has shown how modern imaging techniques like ultrasound, Doppler, CT, MRI, angiography and DSA can readily differentiate the various types of vascular malformations and haemangiomas into four clinically identifiable management oriented groups – the small channel high flow lesions (congenital haemangioma of infancy or CHI), small channel low flow lesions (capillary, lymphatic, venule combination or CLVC), large channel low flow lesions (vascular malformations or VM) and large channel high flow lesions (arterio-venous malformations or AVMs). The author has also depicted how a combination of high and low flow lesions can be delineated on MRI with serpiginous flow voids suggesting arterial malformation and soft tissue infiltration typical of venous malformation. The chapter has excellent photographs of investigations showing each of the four types of lesions and the use of imaging controlled RF has been shown to be quite precise and safe by the author.

In the third chapter on CHI, the small channel high flow lesions, Dr. Goleria describes their biological behaviour – manifestation, proliferation, involution, post involution – and suggests a management strategy. The fact that

Access this article online

Quick Response Code:



Website:
www.ijps.org

they regress spontaneously and only on rare occasions warrant urgent intervention with steroids, surgery or both has been beautifully depicted through various case studies with stunning photographic records.

The fourth chapter on CLVC, the small channel low flow vascular malformations, shows how these lesions are present at birth and keep proliferating steadily. The author is of the opinion that lasers best treat the capillary malformations in childhood before keratinisation sets in; if not done so, local hypertrophy and hyperplasia occur, and in later life, skin replacement remains the only viable option. The author prefers surgical ablation for macrocystic lymphatic malformations, and for small channel lymphatic malformations, he has opted for periodic ablation with RF suprapulse for surface lesions and RF cautery, either alone or CT guided, for improving precision and reducing surgical exposure in deeper and visceral lesions.

Dr. Nirmala Subramanian is the author of the fifth chapter, "Haemangiomas and vascular malformations of the orbit," and she opines that the orbit has its own special concerns which are anatomical, functional and aesthetic. Newer imaging has improved diagnostic accuracy in this region, and when intervention is mandatory, it should be early in order to avoid preventable complications of vision and aesthetics. Surgical approaches to intraorbital lesions by anterior superior orbitotomy, anterior inferior transconjunctival orbitotomy and lateral orbitotomy have been very precisely illustrated in this chapter.

The sixth chapter, "Lasers in haemangiomas and vascular malformations," is written by Dr. Shrirang G. Pandit and he has advocated the modality because it causes photocoagulation resulting in thrombosis of the channels and involution of the lesions with less morbidity and minimal scarring. The target chromophores – haemoglobin, oxy-haemoglobin, melanin and water – get hit by lasers, and the heat energy thus produced coagulates blood, chars vessel walls and produces thrombosis, showing the best effects in small channel low flow lesions. The chapter has a brief description on laser physics, laser terminology, laser types, and their application in isolation and with RF. Aftercare of patients and laser safety are also briefly described.

The seventh chapter, "Venous malformations – the large channel low flow lesions," is again authored by

Dr. Goleria and he emphasises the importance of a correct diagnosis of the predominant component of the lesion in order to avoid surprises like profuse bleeding perioperatively. Very sagaciously, the author advises that in venous malformations, the input must be ligated before the output and the dissection should be in a centripetal fashion. Sclerotherapy has been advocated for small and residual lesions.

Dr. Anil Karpurkar has authored the eighth chapter, "Vascular malformations of the brain," and in it he has elaborated their clinical presentations, diagnosis and treatment. Pial AVM and AVF, dural AVM, developmental venous anomalies, cavernomas, capillary telangiectasias and cerebro-facial arterio-venous metameric syndrome (CAMS) – all these find a mention in this chapter. Excellent representative angiograms and CT scans, and precision of the offered information are the hallmark of this chapter.

Dr. Goleria has authored the last two chapters in this book, i.e. "Arterial and arterio-venous malformations" and "Steal phenomenon." The author has shown how these large channel high flow lesions grow relentlessly and treating them by blocking the main blood vessels without treating the nidus spells doom as it results in a severe regrowth with multiple new feeders. Ablation of the feeders along with the nidus by embolisation, surgery or a combination of both is a must for results to be lasting and recurrence free. The author explains how the nidus, which is a fast flow system involving both arteries and veins, a conglomeration of many A-V fistulae, is the cause of "steal," which in turn promotes the nidus. Hence, the only way to treat AVM is to totally eliminate the nidus.

The book has an exiting collection of case reports with stunning clinical photographs, angiograms, CT and MR images. Individual cases are vividly described with history, clinical examination, investigations, management and follow-up. The authors have, from time to time, highlighted the expected complications and their management in great detail.

The book boasts of a very crisp foreword penned by Mr. Ian T. Jackson and was released in September this year during the Annual Conference of the Association of Plastic Surgeons of India in Coimbatore. The 221-page book is hardbound and of single volume, and has been published by Jaypee Brothers Medical Publishers (P)

Ltd. New Delhi. It is a must for every plastic surgery library and is an ideal reference book for all head and neck surgeons and plastic surgeons. The author's passion for the subject is matched only by his brilliance of thought process and clarity of articulation. I can assure that every

reader will have a wiser perspective of this difficult problem after going through the pages of this book.

Surajit Bhattacharya

Editor, Indian Journal of Plastic Surgery

E-mail: surajitbh@yahoo.co.in