

Fate of hair follicles in Abbe flap

Sir,

Plastic surgeons have used the Abbe flap quite extensively to replace the Philtrum and for reproduction of a central fullness and pout in correction of secondary deformity of bilateral cleft lip. In the normal lip, in males, there are hair follicles pointing downwards, but when the flap turns through 180° the hair follicles start pointing upwards. This fact has been referred to in the text books. However, whether gravity will help in changing the direction of hair follicles is a question not answered anywhere in the literature. Occasionally, in personal communications some colleagues have asserted that it may not happen, but none had a physical evidence to support the claim.

In a female patient and in patients who shave the moustache this does not pose a problem, but this question becomes relevant when dealing with patients who wish to have a moustache for reasons, religious, and otherwise. A review of literature did not reveal an answer to this question.

Three years ago in our department, an Abbe flap was done for a patient of bilateral cleft lip who was a resident of Middle East and wanted to keep his moustache. This patient turned up for follow-up after 3 years and the hair follicles are maintaining their original direction and there is a gross discrepancy in the hair follicles in the middle and two sides of the upper lip which is quite obvious on close inspection [Figure 1]. This however did not bother the patient.

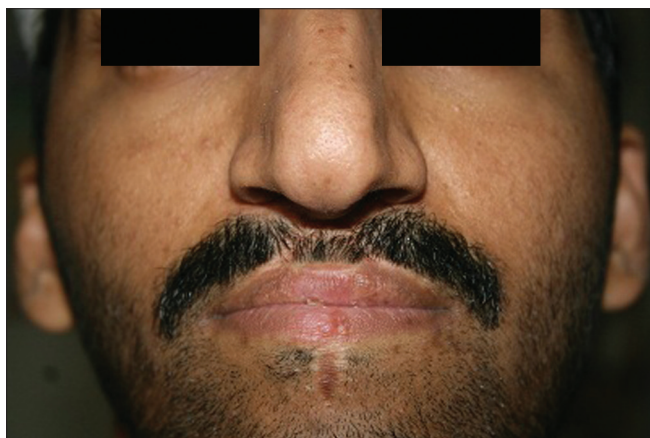


Figure 1: Showing the discrepancy in the direction of hair follicles in the Abbe flap and the upper lip

J. Rajesh, Gopalakrishna Annavarapu

Department of Plastic Surgery, Deccan College of Medical Sciences, Hyderabad, India

Address for correspondence:

Dr. J Rajesh, Department of Plastic Surgery Deccan College of Medical Sciences, Kanchan Bagh, Hyderabad - 500 058, A.P., India.
Email: rajesh999_99@yahoo.com

Access this article online

Quick Response Code:



Website:

www.ijps.org

DOI:

10.4103/0970-0358.90862