

Original Article

Incidence of agenesis of palmaris longus in the Andhra population of India

K. Devi Sankar, P. Sharmila Bhanu, Susan P. John

Department of Anatomy, Narayana Group of Medical Institutions, Nellore, Andhra Pradesh, India

Address for correspondence: Dr. K. Devi Sankar, H30/7, 1st Cross Road, TNHB Colony, Durga Nagar, Sanatorium, Chennai-600 047, India.
E-mail: lesanshar009@gmail.com

ABSTRACT

Background: The knowledge of Palmaris longus (PL) is a growing interest for its wide role in reconstructive plastic surgeries as a donor tendon for transfer or transplant. The prevalence of the PL agenesis has been well-documented by many authors in different ethnic groups or populations. Many conventional tests for determining the presence of the PL has been described, but lamentably there are many discrepancies in confirming its presence or absence. Slight modifications of the prevailing methods can still give authenticate results. **Aim:** This prospective study was conducted to determine the incidence of unilateral and bilateral agenesis of PL and its association with sex and side of the limb in the Andhra population of India. **Materials and Methods:** A total of 942 subjects of both sexes belonging to 18-23 years were used to access the PL using various tendon examination techniques including our modified Schaeffer's test. The data collected were analyzed by Pearsons χ^2 test using SPSS software. **Results:** Overall agenesis of muscle in both sexes was 264 (28.0%), out of which 40.2% was seen in females and 14.7% in males with the ratio of 3:1. The unilateral agenesis was seen in 70.5% and bilateral agenesis in 29.5% subjects. The left side agenesis was seen in 51.6% and right side in 48.4% subjects. **Conclusions:** The prevalence of bilateral and unilateral agenesis was more common on left side with a greater likelihood in the female subjects. The proposed technique could bring better results in all subjects and can be implemented in manual examination of PL.

KEY WORDS

Muscle agenesis; palmaris longus; tendon anomalies; tendon graft

INTRODUCTION

Palmaris longus (PL) is a thin, tendinous superficial flexor of forearm, functionally more active in non-human primates.^[1] In humans, PL is a weak flexor of

the hand at wrist, tenses the palmar aponeurosis^[2] and is one of the most variable muscles in the body. The variation includes unilateral or bilateral agenesis, duplication or in the site of insertion. Although the function is very less, PL receives the attraction of the surgeons for its use in reconstructive plastic and hand surgery as tendon graft, in lip augmentation or escalation,^[3] ptosis correction^[4] and also in some facial paralysis management.^[5]

According to classical textbooks of anatomy and surgery, the agenesis of PL was seen in 15% of general population, but it is not applicable to all populations and varies among

Access this article online	
Quick Response Code: 	Website: www.ijps.org
	DOI: 10.4103/0970-0358.81448

ethnic groups.^[6,7] The incidence of PL agenesis in different ethnic groups shows significance in association with the sex and side of the limb; however, some remain controversial.^[8]

The aim of this study is to determine the incidence of unilateral and bilateral agenesis of PL and its association with sex and side of the limb in the Andhra population of India.

MATERIALS AND METHODS

A group of 942 first and second year medical, dental and paramedical students (450 boys and 492 girls) of age group 18-23 years from Narayana Group of Medical Institutions,

Nellore, Andhra Pradesh, India were randomly used for this study. Those who are having any deformities or injury in the upper extremity were strictly excluded from the present study. In this present study, the prevalence of presence or absence of PL was determined by series of tendon examination techniques described by Schaeffer's test,^[9] Thompson's fist,^[10] Mishra's 1st test,^[11] Pushpakumar's two finger sign^[12] [Figure 1a-d] and our modified Schaeffer's technique [Figure 2].

In our modified Schaeffer's technique, the subjects were asked to oppose the thumb against the little finger and simultaneously flex the hand at wrist joint. If present, PL appears as a prominent tendon medial to tendon of flexor carpi radialis (FCR) in the middle of the lower part of the front of forearm, just above the wrist. If not clearly seen, a slight extending/resistance force was applied to the middle three fingers. Still if it is not visible it was taken as absent in that subject. The results were statistically analyzed by Pearson χ^2 test using SPSS 12.0 statistical software.

RESULTS

In a sample of 942 students (450 males and 492 females), a

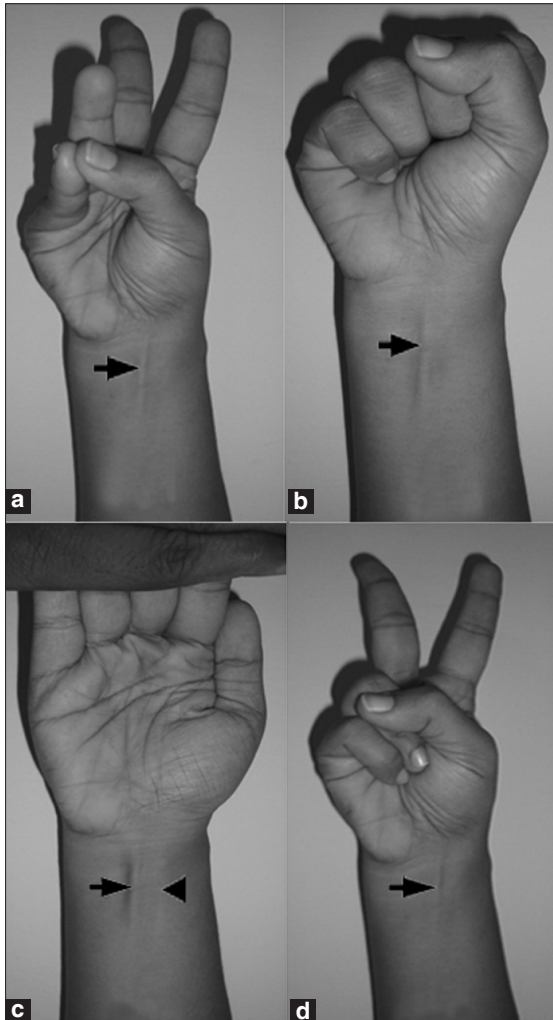


Figure 1: (a) Schaeffer's test – opposition of thumb to little finger with flexion at wrist. Arrow – Palmaris longus tendon, (b) Thompson's test – opposed thumb over clenched fist with flexion at wrist. Arrow – Palmaris longus tendon, (c) Mishra's 1st test – hyperextension of fingers at metacarpo-phalangeal joint with flexion at wrist. Arrow – Palmaris longus tendon, Arrow head – Flexor carpi radialis tendon, (d) Pushpakumar's test – extension of index and middle finger with opposed thumb over medial two fingers. Arrow – Palmaris longus tendon

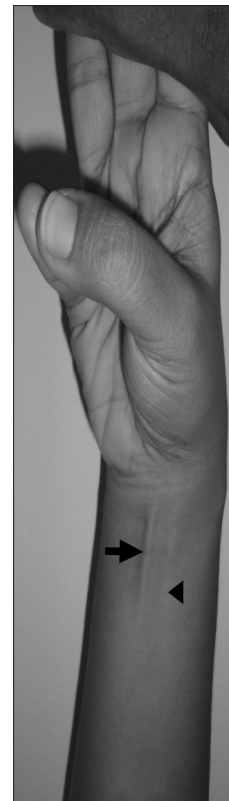

Figure 2: Modified Schaeffer's test - opposed thumb against little finger with flexion at wrist and extending pressure applied to middle three fingers. Arrow – Palmaris longus tendon, Arrow head – Flexor carpi radialis tendon

total of 264 PL agenesis was seen of which 198 were females (40.2%) and 66 were males (14.7%). Unilateral agenesis was seen in 186 (70.5%) and bilateral in 78 (29.5%) subjects. The left-side agenesis was seen in 72 females (52.2%) and 24 males (50.0%) with the total of 96 (51.6%) subjects. The right-side agenesis was observed in 90 (48.4%) subjects; of which 66 (47.8%) were females and 24 (50.0%) were males. Out of 78 (29.5%) bilateral agenesis, 60 (30.3%) were females and 18 (27.3%) were males [Table 1].

DISCUSSION

Palmaris longus is an active muscle in non-human primates used for prehensile progression from tree to tree. PL is found to be present in orangutan, but is variably absent in chimpanzee and gorilla.^[1] Phylogenitically, PL is classified as a retrogressive muscle in the human body^[13] i.e., a short muscle belly proximally with long tendon distally.^[14] Subjected to numerous evolutionary influences, the muscle may be absent, double or with anomalous insertions. Very rarely the PL shows proximally the tendon and distally the muscle belly.^[15] The agenesis of PL in human appears to be

hereditary but its genetic transmission is not clear.^[16]

Identification of PL is very important to clinicians for its tendon to be used as a graft in various surgical procedures and during administration of medicine/corticosteroids in carpal tunnel to relieve pain due to carpal tunnel syndrome/ arthritis^[17] and in median nerve wrist block.^[18]

According to the literature there are various methods^[9,10,12,18,19] to identify the tendon of PL, each having its own identifying techniques. The most commonly and traditionally followed method is Schaffer’s test.^[9] Next to Schaffer’s test, Mishra’s 1st test^[11] is widely supported because of its appliance in those patients with median nerve palsy also, in whom the opposition of thumb is not possible.^[7,20,21] The techniques of Schaeffer’s test,^[9] Thompson’s fist,^[10] Mishra’s 1st test,^[11] Pushpakumar’s two finger sign^[12] have been used in this study to demonstrate the presence or absence of PL. Even though these clinical tests mentioned mostly provides correct information of the presence or absence of the tendon, sometimes a weakly developed tendon which is present can be mistaken as absent. To avoid this, a final

Table 1: Gender wise distribution of Palmaris longus agenesis and its lateralization

Gender	No agenesis (%)	Agenesis	Unilateral agenesis (%)	Bilateral agenesis (%)	Left sided agenesis (%)	Right sided agenesis (%)
	n = 942		n = 264		n = 186	
Male	384 (85.3)	66 (14.7)	48 (72.7)	18 (27.3)	24 (50.0)	24 (50.0)
Female	294 (59.8)	198 (40.2)	138 (69.7)	60 (30.3)	72 (52.2)	66 (47.8)
Total	678 (72.0)	264 (28.0)	186 (70.5)	78 (29.5)	96 (51.6)	90 (48.4)
	Pearson Chi-Square value = 76.226; df = 1; P < .0001		Pearson Chi-Square value = .218; df = 1; P < .382		Pearson Chi-Square value = .067; df = 1; P < .463	
	OR = 3.918, 2.853 - 5.382 (95% CI)		NS		NS	

df = degrees of freedom, OR = Odds ratio, 95% CI = 95% confidence interval, NS = Not significant

Table 2: Distribution of agenesis of Palmaris longus (PL) on different populations of the world

S.no.	Different populations	Percentage of agenesis of PL (%)	Authors
1	North American Caucasians	24	Troha <i>et al</i> ^[5]
2	Pennsylvania	23	Wehbe ^[16]
3	Northern Ireland	25	Thomposn <i>et al</i> ^[24]
4	Gaziantep Turkish Population	63.9	Ceyhan and Mavt ^[22]
5	Korean population	0.6	Ceyhan and Mavt, ^[22]
6	Uganda	1.02	Igbigbi PS ^[27]
7	Chinese	4.6	Sebastin <i>et al</i> ^[7]
8	Malaysian population	9.3	Roohi <i>et al</i> ^[28]
9	Indian Delhi population	17.2	Sudhir <i>et al</i> ^[6]
10	Indian Dravidian population	26	Pai <i>et al</i> ^[29]
11	Nigeria	30	Mbaka and Ejiwunmi <i>et al</i> ^[30]
12	Harare (Zimbabwe)	1.5	Hope Gangata ^[20]
13	Turkish population	26.6	Ozkan Kose <i>et al</i> ^[21]
14	South Indian Andhra Pradesh	28.0	Present Authors

confirmation of the presence or absence of the muscle was made with a slightly modified form of the Schaffer's test in the present study. This method is more specific than the Mishra's 1st test^[11] in all the subjects, that even in obese subjects especially women we could identify and palpate the tendons of PL and FCR successfully.

The overall prevalence of unilateral and bilateral agenesis of PL irrespective of the gender was found to be 28% in this study which is a higher when compared to other studies [Table 2]. Cehyan and Mavt^[22] reported 63% in Gaziantan Turkish population seems to be the highest incidence of PL agenesis but recent investigation in Turkish population the agenesis was found to be only 26%.^[21]

The present study was undertaken to evaluate the incidence of PL agenesis and to impart for any association with the sex and side of the subjects according to the results obtained. From the literature, PL agenesis in different races and ethnic groups was found to be more common in females, predominantly on the left side. However, controversial findings have also been reported that PL agenesis is more frequent on right side and more in males than females.^[23]

In the present study, incidence of agenesis of PL was more in females (40.2%), frequently seen on left side (52.2%) and the overall incidence in relation to gender and body side was statistically not significant which coincides with most of the previous reports.^[9,10,22,24]

The long tendon of PL is the first choice of the surgeons frequently been grafted^[25] because of its length, diameter and easy availability, which when harvested does not produce any functional deformity.^[5] As evolutionary changes made PL a retrogressive degenerating muscle, its position and size can be altered or completely may be absent. Even though there are several techniques of tendon examination physically, fallacy of presence of the muscle as absent may happen rarely. To avoid this, ultrasonography or MRI methods may be used for examination which gives accurate confirmation of PL agenesis.^[26] But investigation in huge population it may not be applicable and the only feasible way of evaluating the presence or absence of PL is the clinical testing as used in many previous studies.

In summary of the present study, the clinical examination of PL agenesis in AP population using our modified Schaeffer's test and other tests in a total of 942 subjects revealed an overall incidence of 28.0%. The present investigation adds to the literature and reaffirms with the other studies that the

agenesis is race dependent and not usually significant with the side and gender.

REFERENCES

1. Vanderhooft E. The frequency and relationship between the palmaris longus and Plantaris tendons. *Am J Orthop* 1996;25:38-41.
2. Ito MM, Aiko M, Kida MY, Ishii S, Kumaki K, Tanaka S. Length and width of the tendinous portion of the palmaris longus: A cadaver study of adult Japanese. *J Hand Surg Am* 2001;26:706-10.
3. Davidson BA. Lip augmentation using the palmaris longus tendon. *Plast Reconstr Surg* 1995;5:1108-10.
4. Naugle TC Jr, Faust DC. Autogeneous palmaris longus tendon as frontalis suspension material for ptosis correction in children. *Am J Ophthal* 1999;127:488.
5. Troha F, Baibak G J, Kelleher J C. Frequency of the palmaris longus tendon in North American Caucasians. *Ann Plast Surg* 1990;25:477-8.
6. Kapoor SK, Tiwari A, Kumar A, Bhatia R, Tantuway V, Kapoor S. Clinical relevance of palmaris longus agenesis: Common anatomical aberration. *Anat Sci Int* 2008;83:45-8.
7. Sebastin SJ, Lim AY, Wong HB. Clinical assessment of absence of the palmaris longus and its association with other anatomical anomalies: A Chinese population study. *Ann Acad Med Sing* 2006;35:249-53.
8. Sebastin SJ, Lim AY, Bee WH, Wong TC, Methil BV. Does the absence of the palmaris longus affect grip and pinch strength? *J Hand Surg Br* 2005;30:406-8.
9. Schaeffer JP. On the variations of the palmaris longus muscle. *Anat Rec* 1909;3:275-8.
10. Thompson JW, McBatts J, Danforth CH. Hereditary and racial variations in the musculus palmaris longus. *Am J Phys Anthropol* 1921;4:205-20.
11. Mishra S. Alternative tests in demonstrating the presence of palmaris longus. *Indian J Plast Surg* 2001;34:12.
12. Pushpakumar SB, Hanson RP, Carroll S. The 'two finger' sign: Clinical examination of palmaris longus (PL) tendon. *Br J Plast Surg* 2004;57:184-5.
13. Reimann AF, Daseler EH, Anson BJ, Beaton LE. The palmaris longus muscle and tendon; A study of 1600 extremities. *Anat Rec* 1944;89:495-505.
14. Koo CC, Roberts AH. The palmaris longus tendon: Another variation in its anatomy. *J Hand Surg Br* 1997;22:138-9.
15. Oommen, Rajarajeshwari A. Palmaris longus: Upside down. *J Anat Soc India* 2002;51:232-3.
16. Wehbe MA. Tendon graft donor sites. *J Hand Surg Am* 1992;17:1130-2.
17. Tallia AF, Cardone DA. Diagnostic and therapeutic injection of the wrist and hand region. *Am Fam Physician* 2003;67:745-50.
18. Salam GA. Regional anesthesia for office procedures: Part II, Extremity and inguinal area surgeries. *Am Fam Physician* 2004;69:896.
19. Bhattacharya V, Raveendra Reddy G. The palmaris longus tendon-rationality of the finger manoeuvres. *Br J Plast Surg* 2005;58:419-21.
20. Gangata H. The Clinical Surface Anatomy Anomalies of the palmaris longus muscle in the Black African population of Zimbabwe and a proposed new testing technique. *Clin Anat* 2009;22:230-5.
21. Kose O, Adanir O, Cirpar M, Kurklu M, Komurcu M. The prevalence of absence of the palmaris longus: A study in Turkish population. *Arch Orthop Trauma Surg* 2009;129:609-11.

22. Ceyhan O, Mavt A. Distribution of agenesis of the palmaris longus muscle in 12-18 years old age groups. *Indian J Med Sci* 1997;51:156-60.
23. Machado AB, DiDio LJ. Frequency of the musculus palmaris longus studied *in vivo* in some Amazon Indians. *Am J Phys Anthropol* 1967;27:11-20.
24. Thompson NW, Mockford BF, Cran GW. Absence of the palmaris longus muscle: A population study. *Ulster Med J* 2001;70:22-4.
25. Park S, Shin Y. Results of long-term follow-up observations: Blepharoptosis correction using the palmaris longus tendon. *Aesth Plast Surg* 2008;32:614-9.
26. Schuurman AH, Van Gils AP. Reversed palmaris longus muscle on MRI: Report of four cases. *Eur Radiol* 2000;10:1242-4.
27. Igbigbi PS, Ssekitoleko HA. Incidence of agenesis of the palmaris longus muscle in Ugandans. *West Afr J Anat* 1998;6:21-3.
28. Roohi SA, Choon-Sian L, Shalimar A, Tan GH, Naicker AS. A Study on the absence of palmaris longus in a multiracial population. *Malaysian Ortho J* 2007;1:126-8.
29. Pai MM, Prabhu LV, Nayak SR, Madhyastha S, Vadgaonkar R, Krishnamurthy A, *et al.* The palmaris longus muscle: Its anatomic variations and functional morphology. *Roma J Morpho Emb* 2008;49:215-7.
30. Mbaka GO, Ejiwunmi AB. Prevalence of palmaris longus absence: A study in the Yoruba population. *Ulster Med J* 2009;78:90-3.

Source of Support: Nil, **Conflict of Interest:** None declared.