

Original Article

A new incision for unilateral cleft lip repair developed using animated simulation of repair on computer

A. K. Sahay, R. Bharat

Department of Burns and Plastic Surgery, Tata Main Hospital, Jamshedpur, Jharkhand, India

Address for correspondence: Dr. Anurag Sahay, 6 KD Flats Kadma Farm Area, Kadma, Jamshedpur, India.
E-mail: anuragkrishnasahay@hotmail.com

ABSTRACT

Background: Unilateral cleft lip repair continues to leave behind some amount of dissatisfaction, as a scope for further improvement is always felt. Most surgeons do not like to deviate from the standard Millard's/ triangular techniques, or their minor modifications, as no one likes to experiment on the face for fear of unfavourable outcomes. The computer can be utilized as a useful tool in the analysis and planning of surgery and new methods can be developed and attempted subsequently with greater confidence.

Aim: We decided to see if an improved lip repair could be developed with the use of computers.

Materials and Methods: Analysis of previous lip repairs was done to determine where an improvement was required. Movement of tissues, by simulating an ideal repair, using image warping software, on digital images of cleft lip was studied in animation sequences. A repair which could reproduce these movements was planned.

A new incision emerged, which had combined the principles of Millard's and Randall / Tennyson repairs, with additional features. The new method was performed on 30 cases.

Conclusions: The results were encouraging as the shortcomings of these methods were minimized, and the advantages maximized.

KEY WORDS

Cleft-lip, computer, simulation

INTRODUCTION

Millard's lip repair^[1] and the triangular flap repair^[2] have been the commonly used cleft lip repair techniques as they are easy to learn and produce fair results. Millard's technique addresses the upper part of the lip and the philtral region quite well, but becomes difficult as the repair approaches the vermilion. In the case of triangular flap repairs it is the other way around and the scar within the philtrum is the most objectionable feature of this repair.^[3] Neither of these repairs therefore produces fully desirable results and the quest for modifications

continues.^[4] With the aid of computers,^[5,6] it is possible to simulate repairs and we have arrived at a new method, which we believe is an improvement over the existing techniques

MATERIALS AND METHODS

We perform over 500 cleft repairs every year, using Millard's and triangular flap techniques and keep on getting valuable feedback from our cases.

The suggestions given by our patients, for an ideal result

are similar to ours *viz*:

1. A good philtral concavity
2. A prominent philtral ridge
3. Symmetrical nostrils
4. Cleft ala level with the normal side.
5. Scar free philtrum
6. Unbroken or a smooth rounded cupid's bow
7. Good nasal sills.^[7]

We therefore began to analyse our previous repairs on the computers. The conclusions which followed were a revision of facts already known. The computer analysis however served to give a clearer visual understanding, followed by a better insight into the planning of incisions.

The outlines of the hemi philtrum from the normal side were reflected onto the cleft/repared side [Figure 1].

- A) It was observed that a significant amount of skin was needed in the philtrum, which was coming from the lateral lip. In Millard's repairs; this was at the upper part and in triangular repairs this occurred at the lower end.
- B) Both produced tight repairs, resulting in obliteration of the philtral concavity and philtral ridge, except in the very narrow clefts.
- C) The suture line of the lateral lip to the medial lip was lying far too medial, within the philtral region and a symmetrical philtrum had not been produced in either of these repairs.

We felt that it would be best if:

1. Skin is brought into the philtral region, but not from the lateral lip.
2. The philtrum is entirely made up of skin from the medial lip, which could be achieved by placing the incision as far laterally as possible, next to the vermilion border.
3. The incision in the lateral part of the cleft could also be placed next to the vermilion border to give sufficient skin for producing a philtral ridge

Analysis of ideal simulated animated repairs

With these observations in mind, an animated repair was simulated on the computer using morphing software; we used Squirlz Morph Warping Software (free software). Fusion of the proposed union lines near the vermilion borders of both sides of the cleft was studied in 30 cases. We were able to visualise not only the changes in

dimensions, but also the vectors along which this was occurring. We divided the same into 3 components for the planning of lip repair. Unlike the planning from the beginning, to the end result of cleft lip repair, on pen and paper, planning with an understanding of the vectors along which the simulated repair was seen to occur in the animation, was the unique feature of this method. Figure 2 shows the start, middle and end of animated simulation which were as follows:

1. Vertical elongation of tissues in the cleft region was the first component and of variable extent.
2. Turning downwards of the vermilion borders of both medial and lateral elements was the second component observed in all cases of simulation.
3. The ala, nasal sill and the lateral lip moved as one unit in the animation, along with the movement of the columella toward the line of fusion. They also turned downwards, in this 3rd component of the repair.

Planning of incisions based on study of simulation

A repair which could address all of these components individually should produce better results. An incision was therefore designed, for subsequent cases, as follows; [Figures 3-4].

A) On the medial lip element, an inferiorly based flap (C1) is raised from over the alveolus and the lower contiguous membranous nasal septal area of the cleft side. The width of this flap is equal to the width of the philtral ridge from the centre of the philtrum on the normal side. The length of this inferiorly based flap extends above the short vertical height of the lip here, making it approach Y, which is closer to the vertical height of the lip Y on the normal side. Tissue raised from this region is actually skin and extends 3 to 4 mm behind the columella and adjacent alveolus [Figure 4]. The incision is turned towards the columellar base, not going beyond the mid point, with fish tailing. This flap fits into the gap created by the large downwards displacement of the lip on the medial side of the cleft, consequent to the fishtailed incision (C2). It also serves to lengthen, by pushing up, the short columella on the cleft side [Figure 5]. This component of the lip repair was omitted in cases where difference in length was minimal. [This flap is comparable to the C flap of Millard's, but is based inferiorly].

B) On the lateral lip element a small muco-cutaneous triangular flap (B1), extending beyond the cupid's bow marking, half on skin and half on mucosa with the

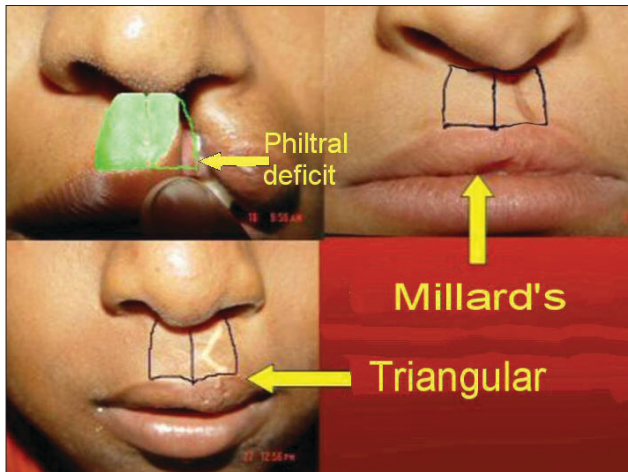


Figure 1: Outlines of the hemi philtrum from the normal side reflected onto the cleft/repared side

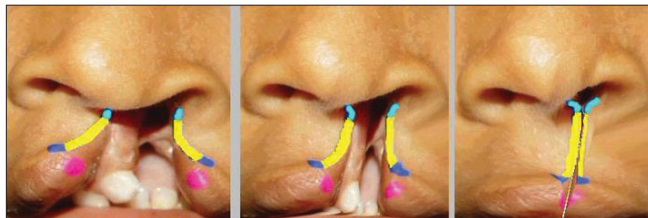


Figure 2: Simulated repair on computer, start, middle and end of animation sequence. Yellow: Showing vertical elongation. Deep blue: downwards turn at vermilion border. Light blue: horizontal downward turning movement in the columellar and alar region, with the ala sill and lip moving as one unit

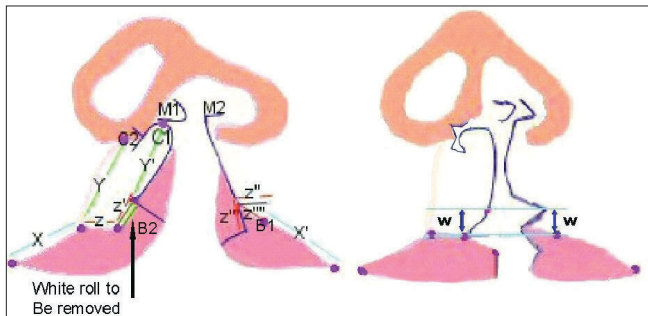


Figure 3: Diagram of planned incisions and movement of flaps

vermilion border going through its apex, each side of the triangle of width equal to half that of the cupid's bow (Z). The base includes a width of skin W equal to the difference in length W compared to the normal side. This triangle is turned downwards achieving both lengthening and downward turn. On the medial lip element, from the cupid's bow landmark to the centre of the cupid's bow (B2) the vermilion border is incised deeply and opened, a 1mm strip of the white roll is removed from there. This will accommodate the previous triangle B1 achieving a downward turn and add tissue to augment the central tubercle of the lip. In this way, the cupid's bow peak coming from the cleft side of the lip, stays far away from

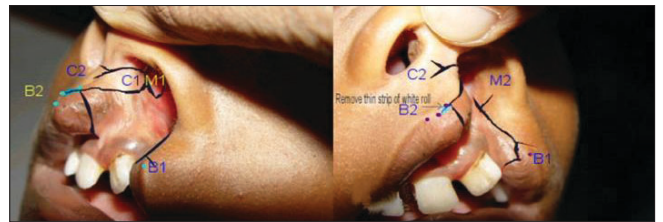

Figure 4: Marking of incisions on the patient

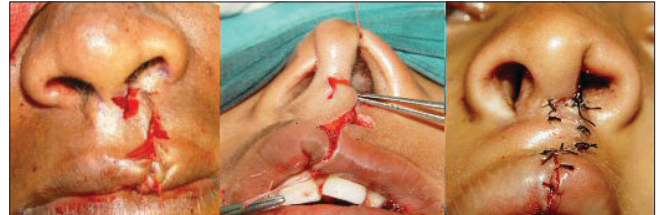

Figure 5: Note the large downward displacement of C1 flap into the gap of fishtailed incision. This transposition accentuates the philtral concavity. The Suture line is also shifted laterally

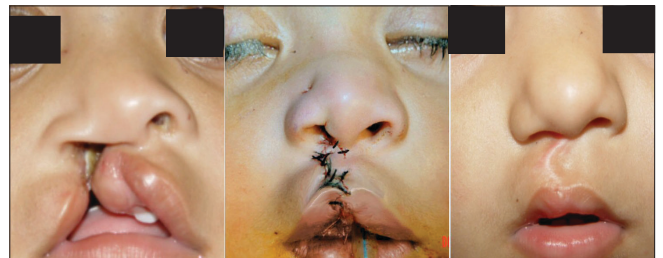


Figure 6: Preoperative, after repair and early post operative result in a wide cleft

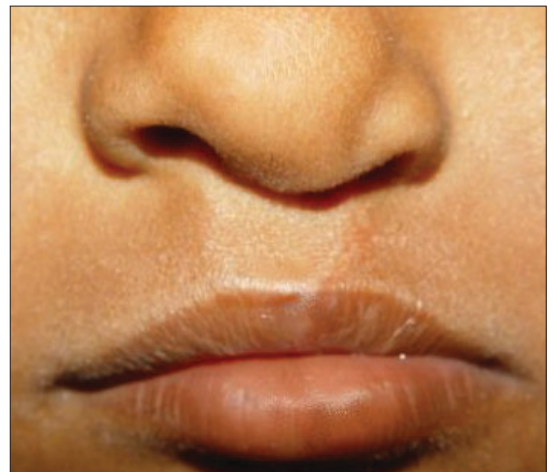

Figure 7: Late result in another wide cleft

the suture lines, it remains rounded and is not interrupted by scarring seen in other methods of repair. This was done in all cases as the animation showed a downward rotation in all cases. (This is comparable to the triangular flap shifted inferiorly, such that the triangular tissue introduced is half skin, half vermilion and a triangular scar is not introduced into the philtral region). This flap

is different from the Millard's white roll flap, as it is not a small flap, but a measured flap extended to reach the centre of the cupid's bow. Alignment of the mucocutaneous junction occurs at the centre of the cupid's bow. C) A small incision (M2) is made and opened above the nasal sill to make an easily adjustable advancement flap, which is sutured to the medial lip in symmetry and level with the normal side. The resultant defect in the mucosa is filled by a septal flap marked as (M1). This component of the lip repair is required in cases with prominent alar webs and when there is a need to make the ala more mobile to adjust the alar level and symmetry.

In all our repairs alar mucosa and cartilage were freely mobilised en masse away from the overlying nasal skin and repositioned through intranasal trans-septal mattress sutures in symmetry with the alar cartilage of the normal side. Straddling sutures for alar webs were also used.

We subsequently performed this repair in 30 cases and the results showed the summation of advantages over both Millard's and triangular repairs.

CONCLUSION

This method of lip repair developed with the aid of computers, contains elements of the Millard's and triangular flap methods of cleft lip repair. The incisions have been modified to overcome the drawbacks in these repairs, but include many of their principles to take advantage of both of these techniques. It has produced encouraging results. We have been able to achieve the following:

1. Transposition of skin into the philtral region from the lower membranous septum / adjacent alveolus. Less lateral lip skin was used and skin from the philtrum was left undisturbed.
2. Lateral shifting of suture lines produce better

symmetry with the normal side philtral ridge.

3. Accentuation of the philtral concavity due to addition of extra skin and less tension after suturing.
4. Unbroken rounded cupid's bow as suturing at the vermilion border is shifted towards the centre of the lip.
5. Augmentation of the central tubercle, as repair of the vermilion shifts towards the centre of the lip with downwards turned flaps, adding tissue from both lip elements.
6. Better equality of nasal apertures, nasal sills and alar level were observed, as more flexibility was possible for adjustment of the ala with the proposed incisions.

We feel that this repair is amenable to further fine-tuning.

REFERENCES

1. Millard Dr Jr. Rotation advancement principle in cleft lip closure. *Cleft Palate J* 1964;12:246-52.
2. Randall P. A triangular flap operation for the primary repair of unilateral clefts of the lip. *Plast Reconstr Surg* 1959;23:331.
3. Lazarus DD, Hudson DA, van Zyl JE, Fleming AN, Fernandes D. Repair of unilateral cleft lip: A comparison of five techniques. *Ann Plast Surg* 1998;41:587-94.
4. Fisher DM. Unilateral cleft lip repair: An anatomical subunit approximation technique. *Plast Reconstr Surg* 2005;116:61-71.
5. Cutting C, Olikier A, Haring J, Dayan J, Smith D. Use of three-dimensional computer graphic animation to illustrate cleft lip and palate surgery. *Comput Aided Surg* 2002;7:326-31.
6. Montgomery K, Sorokin A, Lionetti G, Schendel S. A surgical simulator for cleft lip planning and repair. *Stud Health Technol Inform* 2003;94:204-9.
7. Christofides E, Potgieter A, Chait L. A long term subjective and objective assessment of the scar in unilateral cleft lip repairs using the Millard technique without revisional surgery. *J Plast Reconstr Aesthet Surg* 2006;59:380-6.

Source of Support: Nil, **Conflict of Interest:** None declared.