

# Conservative reconstruction of the smile by orthodontic, bleaching, and restorative procedures

Renato Herman Sundfeld<sup>1</sup>  
 Lucas Silveira Machado<sup>1</sup>  
 Fernanda Garcia de Oliveira<sup>1</sup>  
 Eduardo Almada Santos<sup>2</sup>  
 Isabel Cristina Prado Torres Lugato<sup>3</sup>  
 Daniel Sundfeld Neto<sup>4</sup>

## ABSTRACT

The following is a clinical case report of a patient whose chief complaint was the presence of generalized spacing in the maxillary anterior segment following orthodontic treatment. After meticulous clinical analyses and discussions of the clinical procedures to be adopted, dental bleaching was performed in both arches with 10% hydrogen peroxide (Opalescence Trèswwhite Supreme 10% Hydrogen Peroxide - Ultradent Products, Inc., South Jordan, USA) after the conclusion and stabilization of orthodontic treatment. Then, the orthodontic appliance was removed and the diastemas in the maxillary anterior teeth were closed with Amelogen Plus (Ultradent Products, Inc., South Jordan, USA) resin composite. It was observed that the association of orthodontic, bleaching, and restorative procedures was capable of restoring dental shape, function, and esthetics, allowing the patient to smile without hesitation. (Eur J Dent 2012;6:105-109)

Key Words: Orthodontics; diastema; dental bleaching; composite resin.

- <sup>1</sup> Discipline of Restorative Dentistry, Araçatuba Dental School, São Paulo State University, Araçatuba, Brazil.
  - <sup>2</sup> Department of Pediatric and Community Dentistry, Araçatuba Dental School, São Paulo State University, Araçatuba, Brazil.
  - <sup>3</sup> Orthodontic Trainee at the Araçatuba School of Dentistry, São Paulo State University, Araçatuba, Brazil.
  - <sup>4</sup> Discipline of Dental Materials, Piracicaba Dental School-Campinas University, Piracicaba, Brazil
- Corresponding author: Dr. Renato Herman Sundfeld  
 Faculdade de Odontologia de Araçatuba – Departamento de Odontologia Restauradora – UNESP Rua José Bonifácio 1193, CEP - 16015-050, Araçatuba - São Paulo - Brazil  
 E-mail: sundfeld@foa.unesp.br

## INTRODUCTION

Considerable advancements in communication technology have made a significant contribution to the patient's knowledge, expectations, and demands regarding the esthetic possibilities that this profession has to offer. As a result, professionals have improved their knowledge and qualifications to perform the most varied and innovative forms of dental treatment. Consistent with this survey, multidisciplinary treatment has become increasingly necessary and common in dental offices, particularly for the resolution of more complex clinical cases.<sup>1-6</sup>

A clinical condition that can lead to making this association is related to the presence of interproximal spaces, which detract from the esthetic appearance of the patient's teeth to a large extent. Due to this possibility and with the intention of obtaining satisfactory esthetics, professionals can use conservative esthetic procedures, including dental bleaching and adhesive restorations, or even a combination of them.<sup>7</sup> It is important to point out that contemporary adhesive esthetic dentistry has, among other things, enabled the obtainment of esthetic adhesive restorations strongly bonded to the dental structure, particularly when they are made in tooth enamel. Nevertheless, there is a need for a well-formulated plan and well-qualified professional to perform such restorations.

Our aim was to present a clinical protocol for the esthetic reconstruction of a patient's smile after the conclusion and stabilization of an orthodontic treatment. For this purpose, dental bleaching with 10% hydrogen peroxide and diastema closure with direct resin composite were performed.

### CLINICAL CASE

The 23-year-old patient presented with generalized spacing in the maxillary anterior segment following orthodontic treatment. It was observed that after the leveling and aligning of the teeth, according to the correct position of the canines, premolars, and molars, it was not possible to obtain closure of the diastemas because it characterized a model of positive discrepancy. Specifically, the perimeter of the dental arch was larger than the sum of the mesio/distal diameters of the teeth. Therefore, these spaces were closed with resin composite (Figure 1).

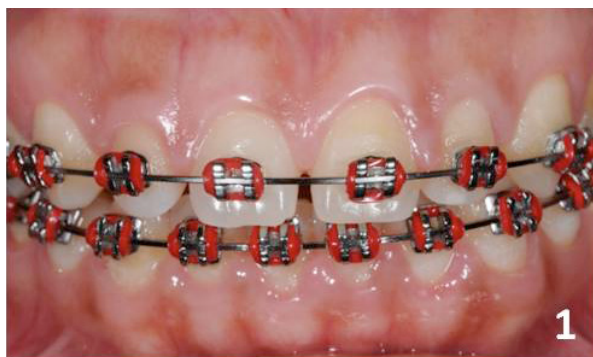

Figure 1. After conclusion and stabilization of orthodontic treatment.

The orthodontic, bleaching, and restorative procedures were performed at the post-graduation clinic of a dental office at the Araçatuba School of Dentistry – UNESP, after the conclusion and establishment of an orthodontic treatment (i.e., prior to removal of the orthodontic appliance in the maxillary and mandibular arches). In-office dental bleaching was performed in the maxillary and mandibular arches with the application of 10% hydrogen peroxide (Opalescence Tréswhite Supreme 10% Hydrogen Peroxide - Ultradent Products, Inc., South Jordan, USA) (Figure 2). The bleaching procedures complied with the clinical sequence presented in Table 1.

Eight consecutive bleaching treatments were performed over eight days. Immediately after dental bleaching 7 topical applications of 2% neutral pH sodium fluoride gel were accomplished, for 4 minutes, with one application per day.<sup>6</sup>

After obtaining the desired color and waiting for a period of seven days,<sup>8,9</sup> the orthodontic appliances were removed from the maxillary and mandibular arches (Figure 3) so that the diastemas between the maxillary anterior teeth could be closed with Amelogen Plus composite resin (Ultradent Products, Inc., South Jordan, USA). The resin composite was applied to the tooth enamel surface after prophylaxis with pumice stone and water using a Robinson-type brush (KG Sorensen Ind. & Com., Alphaville, São Paulo, Brazil). Then, the appropriate resin composite shade was selected by performing absolute isolation. Complete isolation was achieved using rubberdam (Meidex, São José dos Campos, São Paulo, Brazil). The teeth to be reconstructed were etched with 37% phosphoric acid (Dentsply - De Trey GmbH, Konstanz, Germany) on the entire dental clinical

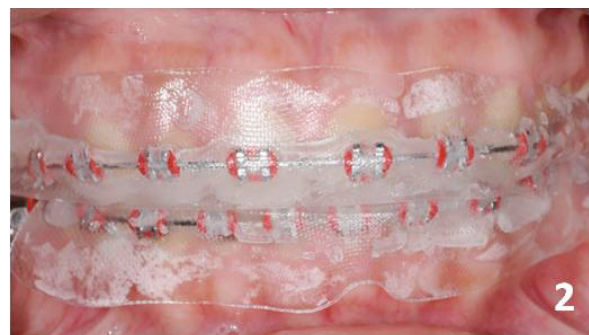


Figure 2. Performing dental bleaching with Opalescence Tréswhite Supreme (10% Hydrogen Peroxide - Ultradent Products, Inc., South Jordan, USA).

crown for 30 seconds. Immediately after washing and drying the etched dental enamel, two layers of the adhesive system Adper Single Bond 2 (3M ESPE Dental Products St. Paul, MN, USA) were applied and subsequently light polymerized for 10 seconds using an Ultralux halogen light appliance (Dabi Atlante, Ribeirão Preto, São Paulo, Brazil) with a power of 450mW/cm<sup>2</sup>. Amelogen Plus resin composite (Ultradent Products, Inc., South Jordan, USA) in dentin shades A1 and A2 and enamel shade EN was used with a metal spatula, polyester strip, and wooden wedge in the proximal regions of teeth that were reconstructed. Light polymeriza-

tion was performed for 20 seconds for each layer inserted and with the aforementioned light polymerizing appliance (Figure 4).

Marginal excesses were removed and the incisal height was adjusted with the use of a diamond tip 1190 F (KG Sorensen Ind. & Com., Alphaville, São Paulo, Brazil) (Figure 5). Occlusal adjustment was performed, as well as in working and non-working excursions, and in protrusion. During the following session, the margins, shape, and color of restorations were again observed for immediately after the finishing and final polishing were performed with Sof-Lex Pop-On (3M ESPE Dental

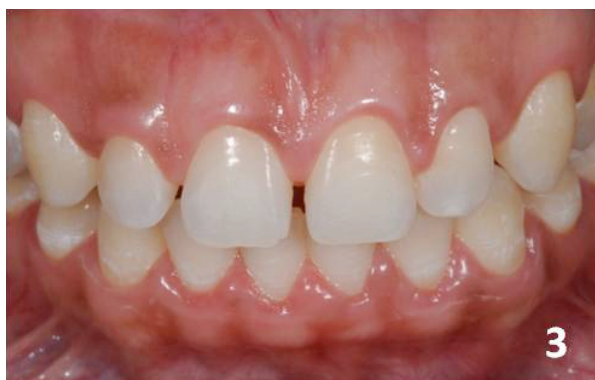

Figure 3. After performing dental bleaching with 10% hydrogen peroxide and removal of the orthodontic brackets.

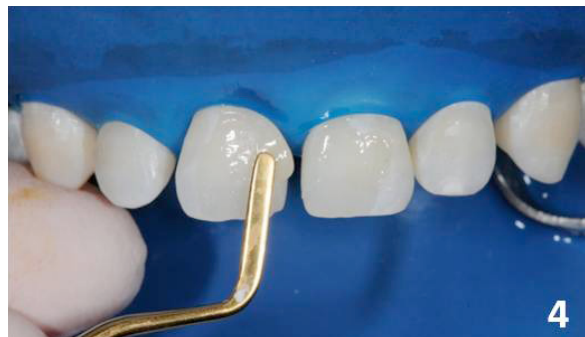

Figure 4. Insertion of Amelogen Plus composite resin (Ultradent Products, Inc., South Jordan, USA).

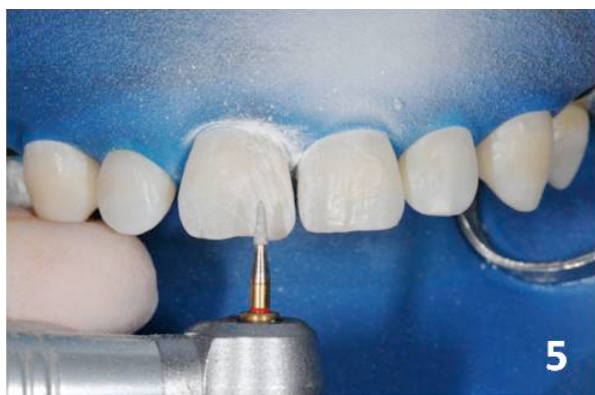


Figure 5. Finishing the composite resin restoration with the application of a 1190 F diamond tip (KG Sorensen Ind & Com, Alphaville, São Paulo, Brazil).

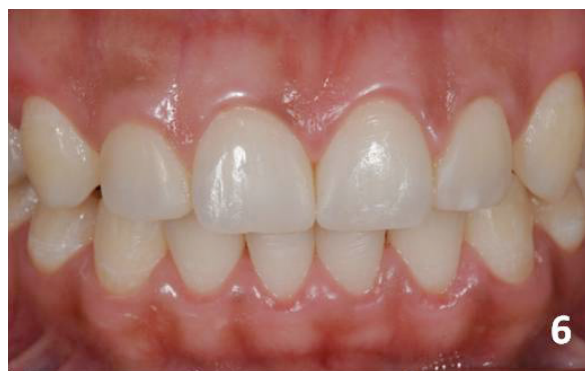

Figure 6. After finishing the restoration.

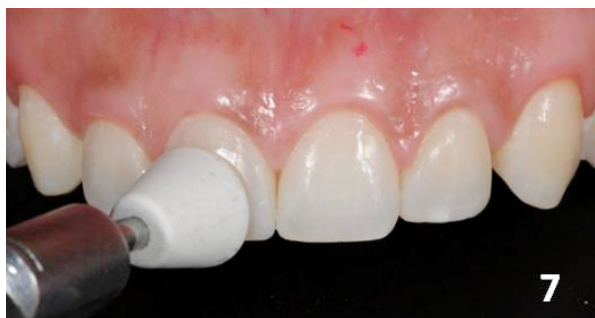

Figure 7. Polishing the restoration with a tip for polishing Jiffy Polisher Cups (Ultradent Products, Inc., South Jordan, USA).

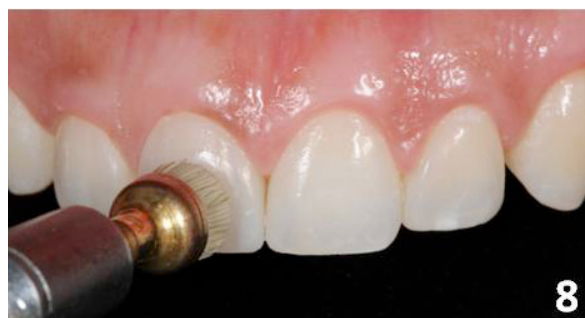

Figure 8. Polishing the restoration with a tip for polishing Jiffy Composite Polishing Brushes (Ultradent Products, Inc., South Jordan, USA).

Products St. Paul, MN, USA). Abrasive discs were used for resin composite finishing and polishing tips, with a tip for polishing Jiffy polisher cups (Ultradent Products, Inc., South Jordan, USA) and Jiffy composite polishing brushes (Figures 6, 7, 8). Figures 9 and 10 show the final result.

## DISCUSSION

Closure of diastemas in the anterior region demands a careful approach and adequate planning by the professional to include multidisciplinary concepts in order to achieve a satisfactory result.<sup>2</sup>

As Mendonça et al,<sup>2</sup> we found that the orthodontic objectives related to the correct position of the molars, premolars, and canines further, vertical and horizontal overlaps were achieved within the normal range. At this time, clinical reasoning must prevail. If we are faced with adequate occlusion from the static and dynamic aspects and there are still diastemas to be closed, the most advantageous solution for the patient is obtained by means of restorative resources.

Due to the fact that the patient presented yellowed dental elements, dental bleaching with 10% hydrogen peroxide was proposed. This was performed after tooth movement and orthodontic stabilization; however, the brackets were not yet

removed from the teeth. This clinical management enabled the closing of the diastemas with resin composite immediately after the removal of the orthodontic brackets, since the dental elements already had the ideal color to the achievement of the restorations.

The manner in which the bleaching product was presented and inserted into the dental arch promoted its adaptation to the teeth and permitted the orthodontic brackets to bond to them, as well as allowing a whitening effect in only 8 days, with one application per day. We observed no dental sensitivity arising from its use. Another option for teeth whitening is the in-office bleaching with hydrogen peroxide at higher concentrations. However, we decided upon the protocol we used because the bleaching of the final result was considerably faster. We utilized topical fluoride after bleaching because we believed that this clinical procedure could promote the remineralization of dental enamel.<sup>7</sup>

To achieve the desired dental esthetics, the golden proportion could be used to construct the dental harmony with regard to the size and shape of the teeth involved in the diastema.<sup>1,2,10</sup> Moreover, the choice of an effective restorative material for direct use must be made using certain criteria so

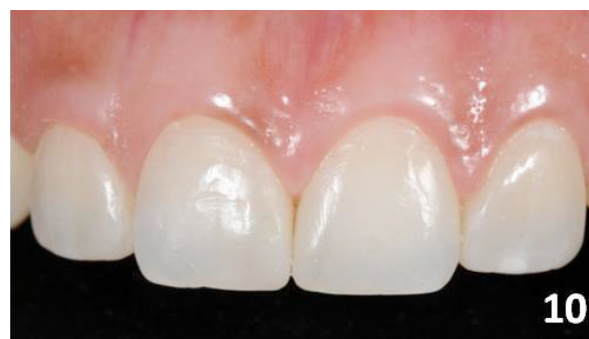
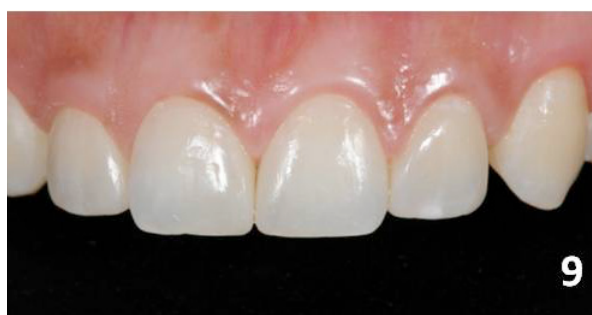
Figure 9 and 10. Final composite resin restorations.

Table 1. Clinical procedures for dental bleaching with Opalescence Tréswhite Supreme (10% Hydrogen Peroxide - Ultradent Products, Inc., South Jordan, USA).

Bleaching Product Application in the Dental Office
1. After prophylaxis with pumice stone and water, if necessary, protect exposed dentinal tissue with a conventional or self-etching adhesive system before applying the hydrogen peroxide-based bleaching material.
2. Apply the molded tray that contains the bleaching product to the dental arch to be bleached, adapting it well to the teeth. Instruct the patient to apply suction to it and to fix it against the teeth to be bleached.
3. Remove the molded tray and use the fingers to press the plastic tray that holds the bleaching product to make it fit better against the teeth to be bleached.
4. Use the bleaching product for a period of 60 minutes
5. After this time, remove the plastic tray that holds the bleaching product and rinse the mouth with water.
6. If necessary, the professional can repeat the process in the dental office on the following day for the same period of time (i.e., 30 to 60 minutes).
7. While the volunteer is undergoing treatment, s/he should avoid sweets, foods that contain any type of coloring agent (e.g., coffee, soda, grape or currant juice), and acidic fruits (e.g., orange, lemon) by the end of bleaching.



that we can safely and satisfactorily establish the new mesio/distal dimensions and widths, as well as the color, texture, and strength of the dental elements involved.<sup>1,2,3,5,7</sup>

The choice of direct restorations with resin composite over other indirect restoration options was made primarily due to the fact that the treatment used was more affordable and did not involve any wear of dental structure. In addition, it is work more inexpensive.<sup>1,2,11</sup> It is worth considering that the clinical success of anterior resin composite restorations is directly related to the use of an extremely accurate technique. Adhesive system penetration into the dental enamel surface depends not only on the efficacy of acid etching, but also on the surface cleanliness of the enamel and the conditions of operative field isolation. In this case, priority was given to absolute isolation. However, if this cannot be done, relative isolation may be used, provided that it is carefully performed. Once the enamel surface has been etched, if it is contaminated by saliva or oral humidity, it interferes with tag formation by reducing its number and size, thus affecting retention of the resinous material on the etched surface.<sup>12,13</sup>

The composite resin used was Amelogen Plus (Ultradent Products, Inc., South Jordan, USA), which is a direct restorative composite developed for restoring anterior and posterior teeth. Among other attributes, it presents smooth surface after finishing and polishing. Performing adequate occlusal adjustment in both habitual maximum intercuspidation and working and nonworking excursion and protrusion movements will undoubtedly contribute to the longevity of the restorations performed.<sup>1</sup> Periodic controls of the orthodontic conditions established and restorations performed must be made by visits to the professional responsible for the treatment provided.<sup>1,2</sup>

## CONCLUSION

We can affirm that the association of orthodontic, bleaching, and restorative procedures was capable of restoring dental shape, function, and esthetics and contributed to our patient's esthetic appearance.

## REFERENCES

1. Garcia AR, Sundfeld RH, de Alexandre RS. Reestablishment of occlusion with prosthesis and composite resin restorations. *Bull Tokyo Dental Coll* 2009;50:91-96.
2. Mendonça MR, Koyama NS, Machado LS, Guedes APA, Oliveira FG, Sundfeld Neto D, Sundfeld RH. Associação de procedimentos ortodônticos e restauradores na recuperação do sorriso de um paciente adolescente. *Dent Bras* 2009;1:14-16.
3. Sundfeld RH, Croll TP, Rahal V, De Alexandre RS, Briso AL, Sundfeld Neto D. Smile restoration by use of enamel microabrasion associated with tooth bleaching. *Compend Contin Educat Dent* 2008;29:2-9.
4. Sundfeld RH, Rahal V, Croll TP, De Alexandre RS, Briso AL. Enamel microabrasion followed by dental bleaching for patients after orthodontic treatment-case reports. *J Esthet Restor Dent* 2007;19:71-77.
5. Furuse AY, Franco EJ, Mondelli J. Esthetic and functional restoration for an anterior open occlusal relationship with multiple diastemata: a multidisciplinary approach. *J Prosthet Dent* 2008;99:91-94.
6. Sundfeld RH, Croll TP, Briso AL, De Alexandre RS, Sundfeld Neto D. Considerations about enamel microabrasion after 18 years. *Am J Dent* 2007;20:67-72.
7. Sundfeld RH, Rahal V, Croll TP, De Alexandre RS, Briso AL. Enamel microabrasion followed by dental bleaching for patients after orthodontic treatment-case reports. *J Esthet Restor Dent* 2007;19:71-77.
8. Da Silva Machado J, Cândido MS, Sundfeld RH, De Alexandre RS, Cardoso JD, Sundfeld ML. The influence of time interval between bleaching and enamel bonding. *J Esthet Restor Dent* 2007;19:111-119.
9. Sundfeld RH, Briso AL, De Sá PM, Sundfeld ML, Bedran-Russo AK. Effect of time interval between bleaching and bonding on tag formation. *Bull Tokyo Dent Coll* 2005;46:1-6.
10. Levin EI. Dental esthetics and the golden proportion. *J Prosthet Dent* 1978; 40:244-252.
11. Almog D, Sanchez Marin C, Proskin HM, Cohen MJ, Kyrkanides S, Malmstrom H. The effect of esthetic consultation methods on acceptance of diastema-closure treatment plan: a pilot study. *J Am Dent Assoc* 2004;135:875-881.
12. Komatsu J, Russo M. Restaurações estéticas em dentes anteriores sem preparo cavitário convencional: estudo clínico. *Rev Assoc Paul Cir Dent* 1979;33:386-392.
13. Komatsu J, Russo M, Takayama S, Holland Junior C, Sasaki T, Quintella LA. Influência da contaminação do esmalte dental descalcificado pelo ácido na retenção de restaurações de resinas compostas. *Rev Assoc Paul Cir Dent* 1980;34:476-479.