

# Multiple Hereditary Osteochondromatosis: A Case Report

Çiğdem Küçükesmen<sup>a</sup>, DDS, PhD

Buğra Özen<sup>b</sup>, DDS, PhD

Mustafa Akçam<sup>c</sup>, DDS, PhD

## ABSTRACT

**Objectives:** Common carious lesions owing to vomiting are not widespread in children. In this case, we aimed to report an 11-years-old male patient with common carious lesions due to repeated vomitings, chewing and eating difficulty and retarded growth with Multiple Hereditary Osteochondromatosis (MHO).

**Case Report:** An 11-years-old boy was referred to Department of Pediatric Dentistry in Faculty of Dentistry because of eating difficulty owing to common carious lesions. It was seen that the patient growth was generally retarded in extra-oral examination. Some exostoses were also present on the extremities. It was learned that he was previously diagnosed as MHO in Faculty of Medicine. Nausea and vomiting have been commonly occurring after taking of Didronat. Chewing and eating difficulty and inadequate nutrition were present because of bad oral hygiene, carious lesions and remained roots. Growth was negatively affected by malnutrition and MHO.

**Results:** Diet recommendations were given and oral hygiene behaviors were rearranged. Preventive, surgical, restorative and prosthetical dental applications were applied for dental treatments. (Eur J Dent 2007;1:183-187)

**Key Words:** Bisphosphonates; Bone tumor; Chondrosarcoma; Multiple hereditary exostoses; Hereditary multiple osteochondromatosis.

## INTRODUCTION

Multiple Hereditary Osteochondromatosis (MHO) is an autosomal dominant developmental disorder characterized by the presence of multiple

osseous prominences with cartilage caps, arising most commonly from the metaphysis of long bones.<sup>1-6</sup> However, these exostoses have also been found on the diaphysis of long bones, on flat bones, and/or on vertebrae.<sup>1,5,7</sup> Osteochondromas are the most common benign osseous tumors. Sarcomatous changes have been documented to occur in approximately 1-5% of affected patients<sup>1-5,8</sup> and defective endochondral ossification is likely to be involved in the formation of osteochondrosarcomas. Data indicated that most chondrocytes involved in the growth of osteochondromas can proliferate, and that some of them exhibit bone-forming cell characteristics.<sup>9</sup>

Cervical spinal cord compression resulting from osteochondroma is a rare and extremely serious complication of MHO.<sup>7,10</sup> Some symptoms as myelopathy and paralysis may develop. Neurosurgical approach should be recommended in order to

- <sup>a</sup> Assistant Professor, Department of Pediatric Dentistry, Faculty of Dentistry, Suleyman Demirel University, Isparta, Turkey.
- <sup>b</sup> Specialist Doctor, Ottoman Oral-Dental Health Department, Ankara, Turkey.
- <sup>c</sup> Associated Professor, Department of Pediatrics, Faculty of Medicine, Suleyman Demirel University, Isparta, Turkey.
- Corresponding Author: Dr. Cigdem Kucukesmen Süleyman Demirel University, Department of Pediatric Dentistry, Faculty of Dentistry, 32260 Cunur, Isparta, Turkey.  
Phone : +90 537 415 11 10 Fax : +90 246 237 06 07  
E-mail : kucukesmencigdem@gmail.com

achieve a spinal cord decompression, which usually results in excellent functional recovery<sup>7</sup> and it usually has a favorable outcome provided surgical decompression is performed before major neurological damage develops.<sup>10</sup>

Osteochondromas may contribute to altered osseous growth and growth plate of long bones. This altered discrepancy of limb-length or angular deformities and may lead to decreased range of motion, impaired function and possibly to premature osteoarthritis. Also, local muscle, tendon or nerve irritations can cause symptoms of secondary pain.<sup>1,11-13</sup>

For local irritations and/or esthetic reasons, corrective or reconstructive surgery and excision of the exostosis may be performed.<sup>1,12,14,15</sup> Treatment should aim not only at surgical resection of the masses but also at prevention of deformities.<sup>16</sup> But, it was also reported that the risk of an abnormal scarring with keloid formation after osteochondroma excision in MHO patients after surgery.<sup>6</sup> However if a malignancy suspected, complete surgical excision is the preferred treatment.<sup>8</sup> Otherwise, if a spinal cord compression is present, patient may get an excellent recovery without neurologic defects after surgery.<sup>7</sup>

Rarely, multiple osteocartilaginous nodules in temporomandibular joint space and associated joint dysfunction because of synovial osteochondromatosis are reported.<sup>17-21</sup>

In this case report, an 11-years-old male patient with generalized carious lesions caused by vomiting, bad oral hygiene and his chewing and eating difficulty, and retarded growth affected by inadequate nutrition and MHO are presented.

## CASE REPORT

An 11-years-old male patient was referred to Department of Pediatric Dentistry of Faculty of Dentistry due to severe carious lesions and eating difficulty. The patient growth was generally retarded. Some exostoses and shape anomalies were present on the extremities and vertebral column. In anamnesis, his mother reported that, he was diagnosed as MHO at early childhood at one of Faculty of Medicine. Mother had not got any serious problem during pregnancy and there was not kinship between mother and father. The baby had a normal body shape after birth, but the several deformities and outgrowth of the bones had begun

to occur at the age of 2. When the MHO was diagnosed, the medical treatment was started immediately. The patient has been treating with Vitamin D (Devit-3 oral drop, 400 IU/day, daily use), Calcium (Calcimed Fort effervescent tablet, 500 mg/day, daily use) and Etidronate disodium (Didronat-PMO tablet, 400 mg/day, to be used in a scheme once a day for 15 days following an interruption duration of 2.5 months) to prevent from osteoporosis. His mother reported that, he had severe gastrointestinal symptoms such as nausea and vomiting with every intaking periods of Didronat. He had also more carious lesions. The chewing and eating difficulties and an inadequate nutrition were present. There was a general physical weakness. Growth was negatively affected by MHO and malnutrition.

His height was 124 centimeters and his weight was 21 kilograms. The growth of body was seen retarded according to other children in the same age. Several skeletal deformities were present on extremities and vertebrae. The right and left forearms, wrists and shoulders, right shank and patella and left side of thorax were affected by disease (Figures 1 and 2). Mental retardation was not present.

Oral hygiene was very poor. In clinical and radiographical examinations, there were severe carious lesions on 11, 21, 12, 22, 31, 41, 32, 42, 73, 83 numbered teeth and remained roots were present from 74, 75, 36, 46 numbered teeth. 16 and 26 numbered teeth were not present. It was learned that, they were more previously extracted caused by severe carious lesions and pain. It was seen that, the rotation of the 23, 24 and 25 numbered teeth was abnormal in panoramic radiography and they were not shown in oral cavity yet. Wide plaque layers were present on the surfaces of the teeth and roots (Figures 3 and 4).

An effective tooth-brushing method was shown. The oral hygiene behaviours were rearranged. Essential diet recommendations were given and a topical fluoride gel was applied. The patient was prescribed with a chlorhexidine gluconate solution to reduce the levels of pathogen microorganisms before dental treatment. All remained roots with excessive carious lesions were then extracted (74,75,36,46 numbered teeth).

The carious lesions on 11,21,12,22,31,41,32,42 ,73,83 numbered teeth were cleaned with a high speed, water-cooled dental torque (KaVo Super

Torque, Germany) and teeth were then restored with a composite resin and a total-etch adhesive system (Charisma composite resin, Heraeus-Kulzer, Germany, Single Bond adhesive system, 3M, USA).

A consultation with Department of Orthodontics was made for patient. With two clinical considerations together, to make removable partial dentures for providing a sufficient chewing function immediately and observation of oral condition with frequently dental visits were approved for treat-

ment. Impressions of the both arches were then taken, and removable partial dentures were made for both dental arches (Figure 5). Regularly dental visits were recommended to the patient and observation of oral condition with frequently dental controls were approved for future treatment.

## DISCUSSION

Osteochondromatosis, also known as osteochondilaginous exostosis is the most frequent benign bone tumor of the skeletal system.<sup>1-5,22</sup> Osteochondroma may occur in some short bones and may develop endochondral ossification despite its preference for long bones.<sup>22</sup> Affected individuals exhibit bilateral deformities and multiple osteochondromas in the hands, wrists, legs and feet. The forearms and wrists are the most common influenced sites. These deformities include relative shortening of the ulna, bowing of the radius, ulnar deviation of the distal aspect of the radius, wrist and hand.<sup>5,11-14</sup> In this case, all these deformities and multiple osteochondromas were present in defined locations. However, rarely reported mul-

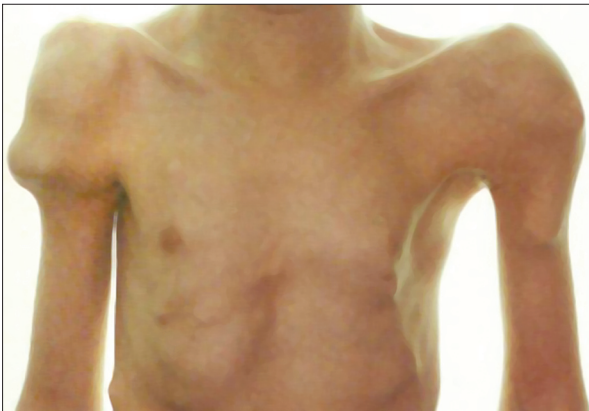

Figure 1. The clinical view of the shoulders and left side of the thorax.

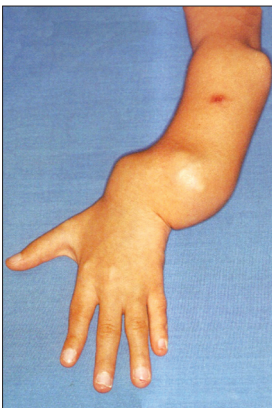

Figure 2. The clinical view of the subacromial extremities.

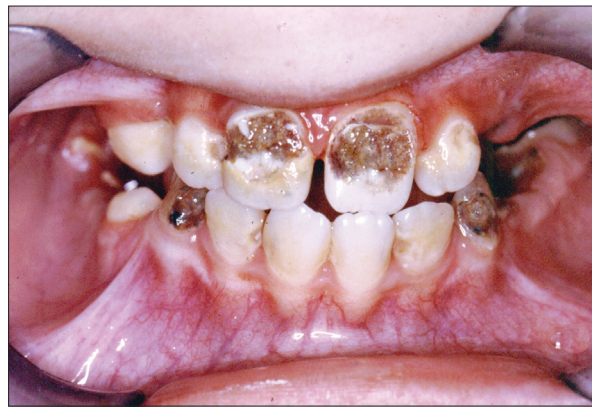

Figure 3. The intra-oral clinical view of the patient.

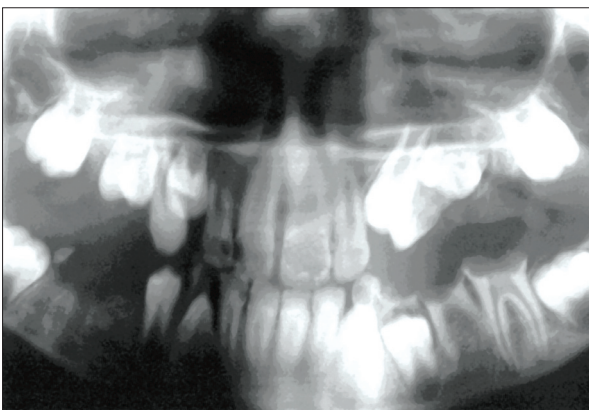


Figure 4. The intra-oral radiographical view of the patient.

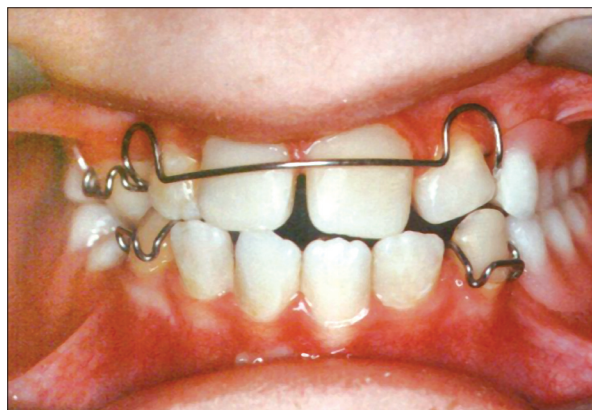

Figure 5. The intra-oral clinical view of the patient after prosthetic dental treatment.

multiple osteocartilaginous nodules in temporomandibular joint space at Synovial Osteochondromatosis<sup>17-20</sup> were not present in our case.

Patil et al<sup>23</sup> reported that the males were predominantly affected with Osteochondromatosis such as in our case.

Some inhibitor drugs which were called as Bisphosphonates are necessary in the treatment of MHO for reducing bone resorption and improve the bone mineral density (BMD).<sup>24-26</sup> Bisphosphonates are powerful inhibitors of osteoclastic activity<sup>25</sup> and they are synthetic analogs of inorganic pyrophosphate that have a high affinity for calcium.<sup>24,25</sup> They are excreted through the kidneys without metabolic alteration.<sup>25</sup> During bone resorption, they are released from the bone surface and may be reincorporated into newly formed bone or osteoclasts.<sup>24</sup> So, they can play an important role in the treatment of loss of mineral density and significantly increase BMD.<sup>24,27,28</sup> Otherwise, bisphosphonates can cause some gastrointestinal system (GIS) reactions, mucosal ulcerations, exposed devitalized bone etc.<sup>24</sup> They led to compromised oral hygiene of the dentition and local infections. This impaired oral hygiene, in turn, may have facilitated local infection leading to advanced bone necrosis (osteonecrosis),<sup>24,25</sup> and subsequent increased tooth mobility and loss. Past dental history for many of the patients revealed recent tooth extraction.<sup>24</sup>

Didronat (Etidronate disodium) which was used medicament in this case is one of drugs of Bisphosphonates.<sup>29,30</sup> It increases the BMD and bone turnover but may also give rise to some GIS symptoms such as diarrhea, nausea, and vomiting<sup>30</sup> and/or esophageal lesions such as oesophagitis or oesophageal ulceration.<sup>29</sup> Repeating vomitings cause to acidic levels of oral pH in oral cavity and acidic pH helps to starting and developing of the carious lesions on the teeth. If patient does not adequately brushes his/her teeth daily, bad oral hygiene rapidly boosts this condition. Carious lesions cause to loss of the dental structures of the teeth. The chewing and eating difficulties may occur owing to the structural lost in time. Insufficient nutrition may affect growth negatively and quality of life may also decrease.

In our case, adverse GIS effects of Didronat was also caused to bad oral hygiene and some GIS reactions. Therefore, several carious lesions,

loss of teeth and malnutrition were occurred and all these symptoms have been negatively affected the growth and life quality of the child. The preventive and other dental treatments are very important and necessary to obtain a good oral condition and sufficient chewing and eating functions. The improved nutrition may provide a better life quality for the patient. So, necessary dental treatments were made for obtaining these better conditions and patient was also called for regularly dental controls and possible necessary dental treatments in the future.

## CONCLUSION

In this case report, a male patient in 11-years-old was presented with common severe carious lesions caused by repeated vomitings due to the mandatory using of a medicine (Didronat) for MHO and also bad oral hygiene. A multidisciplinary dental treatment had applied to get improvements in the oral and systemic conditions of the patient near medical treatment.

## ACKNOWLEDGEMENTS

Patient's dental treatments were practiced by the first and the second authors at Clinic of Pediatric Dentistry in Faculty of Dentistry of Ankara University during the PhD educations of authors. When preparing the article, it was consulted to the medical info of the third author for assessment of the prognosis of the disease and the the effects of the medicines on disease and body.

## REFERENCES

1. Noonan KJ, Levenda A, Snead J, Feinberg JR, MIH A. Evaluation of the forearm in untreated adult subjects with multiple hereditary osteochondromatosis. *The Journal of Bone & Joint Surgery* 2002;84-A:397-403.
2. Peterson HA. Multiple Hereditary Osteochondromata. *Clin Orthop* 1989;239:222-230.
3. Porter DE, Emerton ME, Villanueva-Lopez F, Simpson AH. Clinical and radiographic analysis of osteochondromas and growth disturbance in hereditary multiple exostoses. *J Pediatr Orthop* 2000;20:246-250.
4. Vanhoenacker FM, Van Hul W, Wuyts W, Willems PJ, De Schepper AM. Hereditary multiple exostoses: from genetics to clinical syndrome and complications. *Eur J Radiol* 2001;40:208-217.
5. Faiyaz-UI-Haque M, Ahmad W, Zaidi SHE, Hussain S, Haque S, Ahmad M, et al. Novel mutations in the EXT1

- gene in two consanguineous families affected with multiple hereditary exostoses (familial osteochondromatosis). *Clin Genet* 2004; 66:144-151.
6. Hosalkar H, Greenberg J, Gaugler RL, Garg S, Dormans JP. Abnormal scarring with keloid formation after osteochondroma excision in children with multiple hereditary exostoses. *J Pediatr Orthop* 2007;27:333-337.
  7. Giudicissi-Filho M, de Holanda CV, Borba LA, Rassi-Neto A, Ribeiro CA, de Oliveira JG. Cervical spinal cord compression due to an osteochondroma in hereditary multiple exostosis: case report and review of the literature. *Surg Neurol* 2006;66 Suppl 3:S7-S11.
  8. Skinner R, Beall DP, Webb HR, Ly JQ, Fish JR. Calcaneal osteochondroma. *Okla State Med Assoc* 2007;100:120-124.
  9. Benoist-Lasselín C, de Margerie E, Gibbs L, Cormier S, Silve C, Nicolas G, et al. Defective chondrocyte proliferation and differentiation in osteochondromas of MHE patients. *Bone* 2006;39:17-26.
  10. Faik A, Mahfoud Filali S, Lazrak N, El Hassani S, Hajjaj-Hassouni N. Spinal cord compression due to vertebral osteochondroma: report of two cases. *Joint Bone Spine* 2005;72:177-179.
  11. Fogel GR, McElfresh EC, Peterson HA, Wicklund PT. Management of deformities of the forearm in multiple hereditary osteochondromas. *J Bone Joint Surg Am* 1984;66:670-680.
  12. Wood VE, Sauser D, Mudge D. The treatment of hereditary multiple exostosis of the upper extremity. *J Hand Surg [Am]* 1985;10:505-513.
  13. Peterson HA. Deformities and problems of the forearm in children with multiple hereditary osteochondromata. *J Pediatr Orthop* 1994;14:92-100.
  14. Pritchett JW. Lengthening the ulna in patients with hereditary multiple exostoses. *J Bone Joint Surg Br* 1986;68:561-565.
  15. Masada K, Tsuyuguchi Y, Kawai H, Kawabata H, Noguchi K, Ono K. Operations for forearm deformity caused by multiple osteochondromas. *J Bone Joint Surg Br* 1989;71:24-29.
  16. Saglik Y, Altay M, Unal VS, Basarir K, Yildiz Y. Manifestations and management of osteochondromas: a retrospective analysis of 382 patients. *Acta Orthop Belg* 2006;72:748-755.
  17. Fujita S, Yoshida H, Tojo I, Wada T, Murakami K, Iizuka T. Synovial chondromatosis of the temporomandibular joint: clinical and immunohistopathological considerations. *Br J Oral Maxillofac Surg* 2004;42:259-260.
  18. Shibuya T, Kino K, Kitamura Y, Takahashi T. Synovial chondromatosis accompanying an ossified articular disk in the temporomandibular joint: a case report. *J Oral Pathol Med* 2003;32: 441-442.
  19. Tojo I, Yamaguti A, Ozaki H, Yoshida H, Fujita S. The expression of fibroblast growth factor receptor-3 in synovial osteochondromatosis of the temporomandibular joint. *Arch Oral Biol* 2004;49:591-594.
  20. Cosentino R, De Stefano R, Selvi E, Frati E, Manca S, Manganeli S, et al. Clinical Picture: A haemophilic patient with synovial osteochondromatosis of the ankle. *The LANCET* 2001;358:2157.
  21. Shivanand G, Jain V, Lal H. Progressive pseudorheumatoid chondrodysplasia of childhood. *Singapore Med J* 2007;48: e151-e153.
  22. Becelli R, Saltarel A, Santamaria S, Mastellone P, Gwanmesia I, Cianfrone F, et al. A case report of osteochondroma of the frontotemporosphenoidal suture. *J Exp Clin Cancer Res* 2004;23:147-151.
  23. Patil S, de Silva MV, Crossan J, Reid R. Chondrosarcoma of the bones of the feet. *J Foot Ankle Surg* 2003;42:290-295.
  24. Migliorati CA, Schubert MM, Peterson DE, Seneda LM. Bisphosphonate-associated osteonecrosis of mandibular and maxillary bone. *Cancer* 2005;104:83-93.
  25. Woo SB, Hellstein JW, Kalmar JR. Systematic review: Bisphosphonates and osteonecrosis of the jaws. *Ann Intern Med* 2006;144:753-761.
  26. Emkey R. Alendronate and Risedronate for the treatment of post menopausal osteoporosis: Clinical profiles of the once-weekly and once-daily dosing formulations. *Med Gen Med* 2004;6:6.
  27. Biermasz NR, Hamdy NA, Janssen YJ, Roelfsema F. Additional beneficial effects of alendronate in growth hormone (GH)-deficient adults with osteoporosis receiving long-term recombinant human GH replacement therapy: a randomized controlled trial. *J Clin Endocrinol Metab* 2001;86:3079-3085.
  28. Biermasz NR, Hamdy NA, Pereira Am, Romijn JA, Roelfsema F. long-term skeletal effects of recombinant human growth hormone (rhGH) alone and rhGH combined with alendronate in GH-deficient adults: a seven-year follow-up study. *Clin Endocrinol* 2004;60:568-575.
  29. Larsen KO, Stray N, Engh V, Sandnes D. Esophageal lesions associated with diphosphonates. *Tidsskr Nor Laegeforen* 2000;120:2397-2399.
  30. Ommaty R. Vademecum. Modern medicine guidebook and ATC Index. 26 th ed. Ankara: Feryal Press, 2004:503-504.