

# Standing Needle Arthroscopy of the Metacarpophalangeal and Metatarsophalangeal Joint for Removal of Dorsal Osteochondral Fragmentation in 21 Horses

Alvaro G. Bonilla<sup>1</sup>

<sup>1</sup>Department of Clinical Sciences, College of Veterinary Medicine, University of Montreal, Saint Hyacinthe, Quebec, Canada

Vet Comp Orthop Traumatol 2019;32:420–426.

Address for correspondence Alvaro G. Bonilla, DVM, MSc, Diplomate ACVS, Department of Clinical Sciences, College of Veterinary Medicine, University of Montreal, Saint Hyacinthe, QC J2S 2M2, Canada (e-mail: aa.garcia.bonilla@umontreal.ca).

## Abstract

**Objective** The aim of this study was to report the technique, experience and outcome of standing arthroscopic removal of dorsal osteochondral fragmentation of the metacarpophalangeal and metatarsophalangeal joint using a 1.2-mm needle arthroscope.

**Study Design** This was a prospective clinical study.

**Materials and Methods** All horses referred for standing arthroscopic removal of dorsoproximal first phalanx fragments or fragments embedded in the distal aspect of the synovial plica were included. Relevant information from the cases was recorded. Follow-up was obtained by a telephone questionnaire.

**Results** Twenty-one horses with a mean age of 4.5 years old were included. Osteochondral fragments removed were from the proximal margin of first phalanx in 18 horses (24 joints), in the synovial plica in 2 horses (2 joints) or free-floating fragment in 1 horse (1 joint). Fifteen out of twenty-one horses were unilaterally affected and 6/21 bilaterally. Fifteen out of twenty-seven affected joints were forelimbs and 12/27 hindlimbs. All articular structures within the dorsal recess of the joint were visible. The arthroscope was deemed easy to use and manoeuvre. Only minor complications occurred during the procedure. Surgery time was 15 to 20 minutes for most patients.

**Conclusions** All fragments were successfully removed and needle arthroscopy allowed a thorough evaluation of the dorsal aspect of the joint. The technique offers an alternative for standing fetlock arthroscopy for surgeons concerned about equipment damage or portability.

## Keywords

- ▶ equine
- ▶ needle
- ▶ standing
- ▶ metacarpophalangeal joint
- ▶ arthroscopy
- ▶ minimally invasive
- ▶ osteochondral fragment

## Introduction

Osteochondral fragmentation of the dorsal aspect of the metacarpophalangeal and metatarsophalangeal joint is commonly diagnosed in different horse breeds and sport disciplines.<sup>1–3</sup> These fragments are traditionally removed via arthroscopy under general anesthesia.<sup>1–4</sup> However, advance-

ments in equine medicine over the last two decades are increasingly leading toward standing orthopaedic procedures.<sup>5,6</sup> In this sense, a standing arthroscopic technique for removal of dorsoproximal first phalanx fragments with excellent results was described previously.<sup>7</sup> Nonetheless, most equine surgeons still perform the technique under general anaesthesia and standing arthroscopy of the

received  
February 15, 2019  
accepted after revision  
March 27, 2019

© 2019 Georg Thieme Verlag KG  
Stuttgart · New York

DOI <https://doi.org/10.1055/s-0039-1688984>.  
ISSN 0932-0814.

metacarpophalangeal and metatarsophalangeal joint has not gained the popularity that other recently developed standing procedures such as sinus surgery, dental surgery and laparoscopy have obtained.<sup>1-3,8-10</sup>

The reasons for this lack of general acceptance for standing arthroscopy of the metacarpophalangeal and metatarsophalangeal joint are unclear. Some factors may be (1) surgeon discomfort from the required kneeling position during the procedure, (2) concerns over damaging the valuable 4-mm arthroscope traditionally used for the standing procedure or (3) lack of training or interest to perform the procedure in a new fashion when the traditional technique under general anaesthesia is performed relatively quickly and is not particularly challenging for the trained surgeon.<sup>7</sup> The last factor may be, in fact, the most relevant out of all of them as equipment damage has never been reported and surgeon discomfort during the short-timed procedure can be minimized by using knee pads or floor mats.<sup>7</sup>

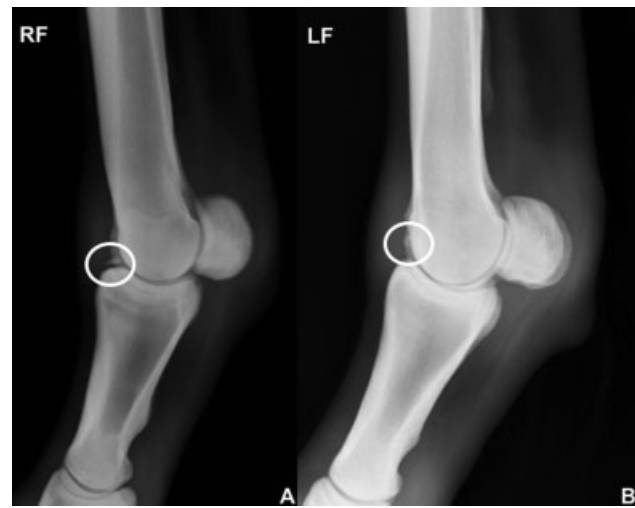
Recently, the use of a reusable but disposable needle arthroscope was described for standing diagnostic arthroscopy of the equine stifle and has since gained popularity.<sup>11</sup> Needle arthroscopes have a small diameter (1.2–1.4 mm), fit through a 2- to 2.5-mm diameter cannula and are easily introduced and manoeuvred in the joint. These arthroscopes were originally conceived to perform in-office knee and shoulder arthroscopy in humans with the goal of reducing cost and simplifying the procedure to obtain a definitive diagnosis.<sup>12,13</sup> The veterinary system for needle arthroscopy is compact and easily portable, and the arthroscope cost is significantly less than the traditional 4-mm arthroscope. Thus, it has the potential to be used as an alternative arthroscope to perform standing arthroscopy of the metacarpophalangeal and metatarsophalangeal joint if visibility within the joint is similar to the standard reported technique.<sup>4</sup> In addition, the lower cost of the needle arthroscope, in the short-term, may facilitate the willingness to perform the standing procedure by surgeons with equipment concerns or lack of familiarity with the technique.

The goals of this clinical prospective study were to report the technique, experience and outcome of standing dorsal osteochondral fragmentation removal of the metacarpophalangeal and metatarsophalangeal joint, using a 1.2-mm needle arthroscope.

## Materials and Methods

All horses that were presented to the University of Montreal Veterinary Teaching Hospital for evaluation and arthroscopic removal of dorsoproximal first phalanx fragments or fragments embedded in the distal aspect of the synovial plica between January 2017 and January 2018 were included in our study (►Fig. 1). Animals with more than two limbs affected were excluded due to surgeon's concern regarding limb movement and contamination during the procedure.

Information collected about each horse included age, sex, breed, sport discipline, severity of lameness, affected limb, limb/s with dorsal fragmentation of the metacarpophalangeal and metatarsophalangeal joint, degree of articular effu-



**Fig. 1** (A) Lateromedial radiograph of the right metacarpophalangeal joint of a horse with a medium sized dorsoproximal first phalanx osteochondral fragment (white circle). (B) Lateromedial radiograph of the left metacarpophalangeal joint of a horse with two medium-sized osteochondral fragments at the level of the distal aspect of the synovial plica (white circle). Ultrasonography confirmed that the fragments were embedded in the synovial plica.

sion (absent to mild, moderate or severe), fragment type (dorsoproximal first phalanx or plica fragment), number and size of fragments (small <3 mm, medium if 3 to 6 mm and large >6mm), location (dorsomedial, dorsolateral or biaxial), fragment attachment (loose, semi-loose [partially attached with fibrous tissue] or well-attached [attached to underlying bone with firm fibrous tissue or bone]), other arthroscopic findings such as synovitis, wear lines and cartilage fibrillation, limb movement during surgery (none, mild movement or knuckling that did not affect surgery, moderate movement or knuckling that made the arthroscope exit the joint and affected surgery), reason for surgery (lameness, future joint health and/or clean radiographs for selling purposes), intra-articular antibiotic medication use and complications during the procedure or hospitalization.

During the arthroscopic procedure, the visibility of the following structures was assessed: the dorsal aspect of the medial and lateral condyles of the third metacarpus/metatarsus (MC3/MT3), the dorsal aspect of the sagittal ridge of the MC3/MT3, the dorsal rim of the first phalanx (P1), dorsal joint capsule attachments to P1 and MC3/MT3 and the dorsal synovial plica.

In all instances, the horses had already been evaluated during clinical or pre-purchase examinations by a veterinarian and were strictly referred for surgery. At our institution, a work-up consisting of physical examination, brief lameness examination, routine radiographic examination of the affected joint and ultrasonography (only in selected cases) were performed before surgery.

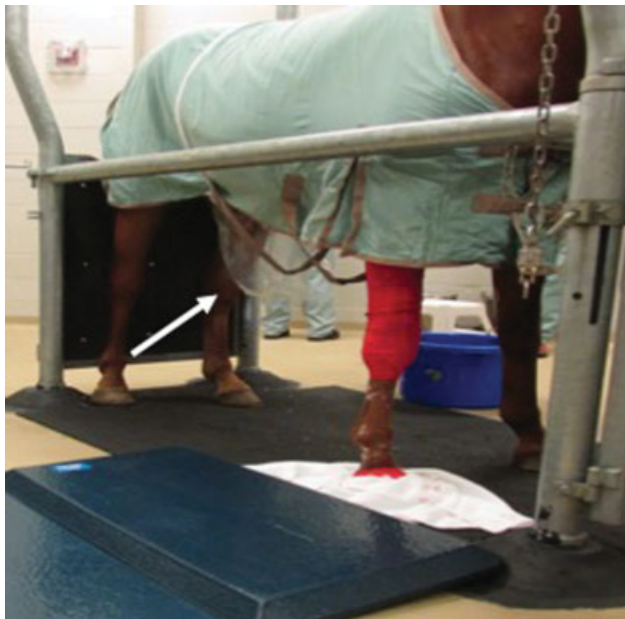Immediately before surgery, the horse was bathed to reduce coat debris, a short-term catheter was placed in either jugular vein and the affected limb was circumferentially clipped from proximal MC3/MT3 to the coronary band. The horse was then covered with a blanket to minimize hair and debris from falling

into the surgical field during surgery and the hoof was covered with a protective elastic bandage (3M Vetrap; 3M, St. Paul, Minnesota, United States). The horse was then sedated with detomidine (0.01 mg/kg intravenously (IV)) and butorphanol (0.01 mg/kg IV), administered phenylbutazone (4.4 mg/kg IV) and entered into standing stocks. Sedation was maintained with a continuous rate of infusion of a 0.05% detomidine/butorphanol solution titrated to effect to obtain a light plane of sedation. Butorphanol was not used during the sedation protocol if any of the affected limb/s were a hindlimb to prevent a deeper plane of sedation and reduce the chance of hindlimb resting during arthroscopy.

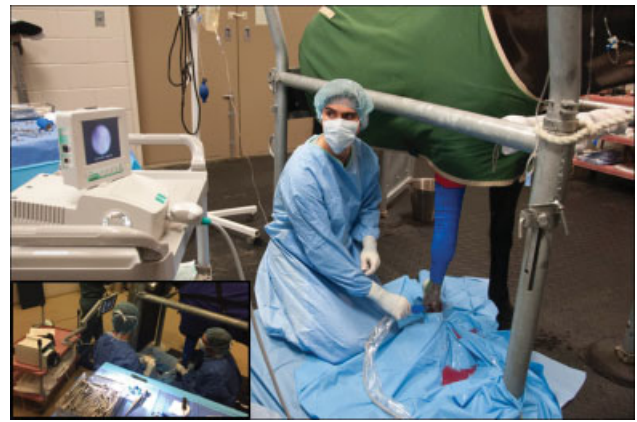A bag attached to a metallic ring and held in place with a roll of gauze around the abdomen of the horse (►Fig. 2) was placed below the prepuce to prevent urine contamination during forelimb surgeries. A urinary catheter was placed in males in a standard fashion for hindlimb surgeries.

Local anaesthesia, limb preparation and draping were performed similarly as previously described.<sup>7</sup> Briefly, intra-articular anaesthesia (30 mL) and an anaesthetic line block at the distal aspect of the MC3/MT3 were performed with 2% mepivacaine hydrochloride after aseptic preparation of the limb. Standard draping of the limb and the surgical field was then performed.

The procedure was performed with the surgeon kneeling on a small soft mat (►Fig. 2) just lateral to the affected limb. The surgeon was always facing cranially regardless of fragment location or limb affected (►Fig. 3). All procedures were performed by one surgeon who had limited experience with needle arthroscopy until the beginning of the study. A 1.25-mm diameter and 65-mm long, needle arthroscope (Biovision Veterinary Endoscopy; LLC, Denver, Colorado, United




**Fig. 2** Sedated horse positioned inside standing stocks. The horse is covered by a blanket and the carpus and antebrachium are bandaged to prevent hair from falling into the surgical field. White arrow depicts the bag placed below the prepuce to collect urine in case of urination. Soft mat to the right of the horse to facilitate the comfort of technicians and surgeons during the procedure.



**Fig. 3** Surgeon performing standing arthroscopy of the right metacarpophalangeal joint of a horse to remove a dorsoproximal first phalanx fragment. The surgeon is kneeling to the right of the horse facing the needle view arthroscopy suite (12 first cases; Biovision) and using a 1.25-mm diameter and 65-mm long needle arthroscope, and a pressure infusion bag to deliver fluids (3 first cases). Note that the screen of the system has been angled away from the surgeon to be depicted in the photograph. There is a bar transversally placed in the stocks in front of the pectoral region to increase the distance between the limb to be operated and the stocks frame. The picture framed on the lower left corner depicts the same procedure while using the next generation needle view arthroscopy suite and a peristaltic pump system to deliver fluids.

States) and the needle view arthroscopy suite (Biovision) (►Fig. 3) were used to perform the procedures. The needle arthroscope was re-sterilized between surgeries using hydrogen peroxide gas sterilization due to the lack of ethylene oxide sterilization (technique recommended by the manufacturer) in our facility.

For the first 10 horses, the arthroscopic cannula (2.2-mm outer diameter and 1.6-mm inner diameter) (►Fig. 4, left) which is commercially available with the needle arthroscopy kit (Biovision Veterinary Endoscopy) was used. However, the small diameter of the cannula limited the intra-articular fluid



**Fig. 4** The 1.25-mm diameter and 65-mm long needle arthroscope in the centre. To the left of the arthroscope and in green, commercially available cannula (2.2 mm) and obturators (blunt and sharp). To the right of the arthroscope and in blue, slightly bigger diameter cannula (2.4 mm) and obturators (blunt and sharp).

pressure that could be obtained after an instrument portal was created. Hence, an alternative route of fluid ingress was deemed necessary in cases requiring large instrument portals or exhibiting marked subchondral bone bleeding after fragment removal and bone debridement. This was obtained by connecting the fluid system to a 16 to 18G needle placed ipsilateral to the arthroscopic portal. For the following 11 horses, a larger diameter cannula (2.4-mm outer diameter and 1.8-mm inner diameter; ▶ Fig. 4, right) provided by the company (Biovision Veterinary Endoscopy) was used and an alternative route of fluid delivery was no longer necessary. An isotonic balanced solution administered via a pressure infusion bag (first 3 horses) or a peristaltic pump system (Masterflex L\|S series, Easy-load II, Cole-Parmer Canada Company, Canada) was used during the procedures.

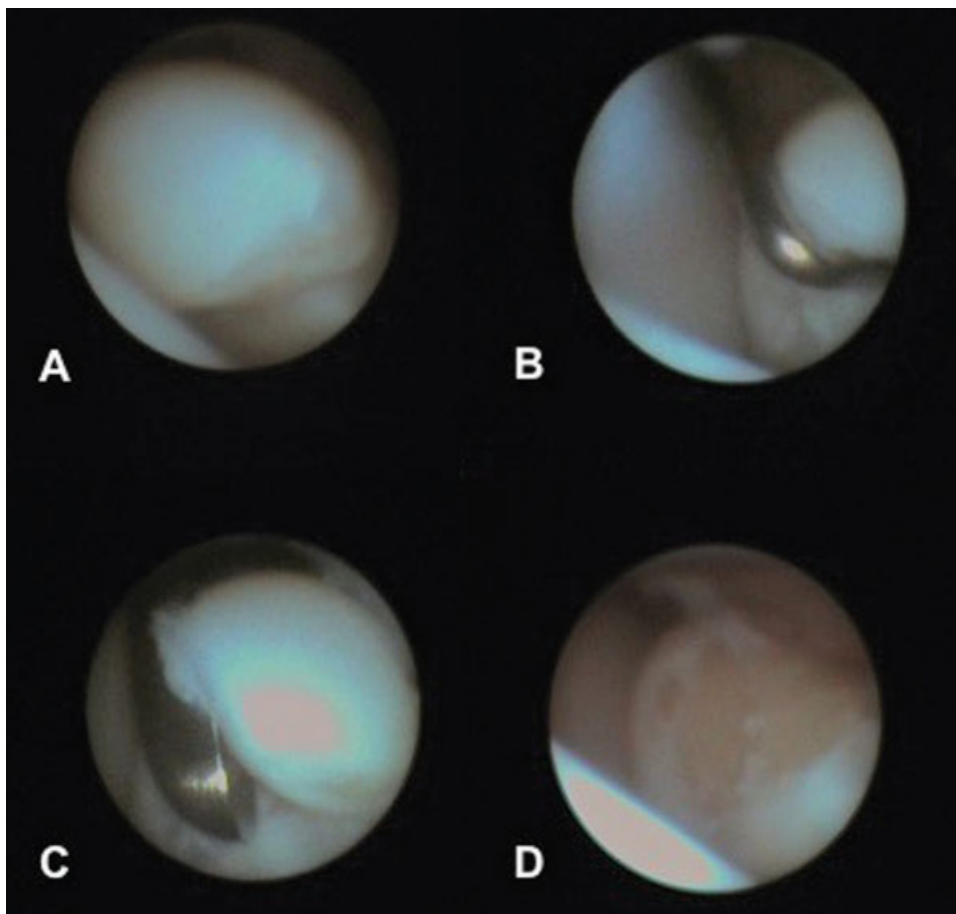
A 3-mm skin stab incision performed with a number 11 blade in the proximal third of the dorsal recess of the joint was placed dorsomedial for dorsolateral fragments or dorsolateral for dorsomedial or biaxial fragments. The cannula and a sharp obturator were then used to penetrate the joint capsule perpendicular to the incision. After joint penetration, the sharp obturator was replaced by a blunt obturator and the cannula was advanced in the horizontal plane. The obturator was then replaced by the needle arthroscope, fluids were connected to

the cannula and routine arthroscopic exploration of the dorsal aspect of the joint was performed.<sup>4</sup> Instrument portals were created ipsilateral to the fragment in a routine fashion. Dorsoproximal first phalanx fragments or fragments embedded in the distal aspect of the synovial plica were removed with Ferris-Smith rongeurs, the fragment bed was debrided with rongeurs for dorsoproximal P1 fragments and last the joint was thoroughly lavaged (▶ Fig. 5). Radiographs were taken intraoperatively to confirm complete removal of the fragment/s. Arthroscopic portals were left unsutured and instrument portals were closed with metric 3 poliglecaprone 25 with a single simple interrupted or cruciate suture pattern. Amikacin or gentamicin was injected into the joint before applying a sterile lower limb bandage. Routine postoperative management and rehabilitation were recommended after surgery for all horses.

Owners were contacted several months after surgery for a follow-up telephone questionnaire. Descriptive statistics of the data collected were performed.

## Results

Twenty-one cases fulfilled the inclusion criteria. These included 8 females and 13 geldings with a mean age of 4.5



**Fig. 5** Arthroscopic images during surgical removal of a large-size dorsoproximal first phalanx (P1) fragment on a right hindlimb. (A) P1 fragment. (B) Fragment elevation with an arthroscopic probe. (C) Fragment removal with Ferris-Smith rongeurs. (D) Fragment bed after surgical debridement. It is worth mentioning that image resolution lowers after images are saved and as the size of the image is artificially increased for presentation or publication purposes.

years (1.7–11 years) and a variety of breeds (12 Warmbloods, 4 Quarter horses, 3 Standardbreds, 1 Frisian and 1 Lusitano). Six horses had not started training yet, nine were in training for different disciplines, two performed in barrel racing, one in dressage, one in racing and two were used for pleasure riding. Eleven horses were not lame, six were 3/5 lame (AAEP scale) in the affected limb (other known problems in the affected limb were present in 2/6) and five horses were lame in another limb other than the limb affected by dorsal fragmentation of the metacarpophalangeal and metatarsophalangeal joint.<sup>14</sup> Reason for surgery was classified as future joint health in eight horses, sale purposes in four and lameness in three horses. A combination of lameness and joint health was the reported reason for surgery in two horses and joint health and sale purposes in another four horses.

Dorsoproximal first phalanx fragments were found in 18 horses (24 joints, 30 fragments), fragments embedded in the distal aspect of the synovial plica in two horses (2 joints, 4 fragments) and a free-floating fragment in one horse (1 joint). Fifteen out of twenty-one horses were unilaterally affected and 6/21 bilaterally. Thirty-five osteochondral fragments were arthroscopically removed from 27 joints: 15/27 forelimbs (9 right and 6 left) and 12/27 hindlimbs (7 right and 5 left). One solitary fragment was removed from 19/27 joints and two from 8/27 joints.

Joint distention was classified as absent to mild in 15/27 joints, moderate in 9/27 and severe in 3/27. Fragment distribution consisted of 26/35 dorsomedially, 4/35 dorsolaterally, 2/35 biaxial and 1/35 fragment was free in the joint. Twenty-three out of thirty-five fragments were well-attached, 11/35 semi-loose and 1/35 was loose. The majority of the fragments had a medium (3–6 mm) size (20/35), 9/35 were small and 6/35 were large. Intra-articular antibiotic medications were injected at the end of arthroscopy in all cases: 17 joints received 250 to 500 mg of amikacin and 10 joints (last 8 horses) received 500 mg of gentamicin. Patient preparation was approximately 45 to 60 minutes, including bathing the animal, while the surgical procedure took 15 to 20 minutes for most patients (14/21, range: 10–60 minutes, mean 24 minutes and median 15 minutes).

Joint visibility was considered equivalent to performing the surgery with a 4-mm arthroscope. The dorsal aspect of both MC3/MT3 condyles, the entire dorsal aspect of the sagittal ridge of MC3/MT3, the dorsal rim of P1, the dorsal joint capsule attachments to P1 and MC3/MT3 and the dorsal synovial plica were visible and evaluated in all cases similarly as when surgery is performed with a 4-mm arthroscope.

Joint health was considered good (lack of abnormalities) in 10/27 joints, mild wear lines or fibrillation was identified in 13/27, moderate wear lines or fibrillation in 2/37 and severe changes, including diffuse cartilage damage, plica enlargement and synovitis, in 2/37 joints (1 horse).

When movement during surgery was assessed, a difference was noted between the first five horses (3/5 moved) and the remaining horses. After horse 5, the protocol was refined by performing the anaesthetic line block strictly proximal to the dorsal recess of the metacarpophalangeal

and metatarsophalangeal joint and by applying a Kimzey splint (Kimzey, Inc., Woodland, California, United States) to the contralateral limb during unilateral hindlimb surgery. This helped to prevent hindlimb resting and therefore movement, during the procedure. For the remaining 16 horses (20 joints), no movement was noted in 17/20, mild in 1/20 joint and moderate in 2/20 joints (2 horses). Persistent skin sensation was the cause in one (horse 19) and prolonged surgery (40 minute) was likely the reason in the second horse (horse 8).

Intraoperative complications included mild fluid extravasation in two horses and subcutaneous needle breakage in one horse that kicked while being regionally blocked. As previously mentioned, horse 19 moved while the instrument portal was performed. Upon reintroduction of the arthroscope into the joint, the arthroscopic image obtained was of slightly lower quality (horse movement did likely damage the scope). Nonetheless, the image quality was still acceptable and the arthroscope was still used in two more procedures. No horses or personnel were injured during the study.

No complications occurred during hospitalization other than a transient fever of unknown origin in one horse that resolved without treatment in 48 hours.

Postoperative follow-up was available for 20/21 of the horses which ranged from 6 months to 18 months after surgery (mean 11.1 months). Performance was not evaluated as many horses were still in training at the time of follow-up. All owners but one reported no complications during the postoperative period. This owner reported mild-to-moderate cellulitis 2 to 3 days after she performed suture removal. Cellulitis resolved 5 days later after prescription of oral antimicrobials by the referring veterinarian. At the time of follow-up, none of the horses were lame and incisions have healed with excellent cosmetic appearance according to the owners.

## Discussion

This report describes the technique, experience and outcome of metacarpophalangeal and metatarsophalangeal joint arthroscopy using a 1.25-mm needle arthroscope in 21 horses with dorsal fragmentation. To our knowledge, this is the first report to describe standing arthroscopic removal of synovial plica fragments. We decided not to perform standing arthroscopic removal for fragments located more proximally in the plica due to technical concerns in the standing patient (i.e. hand/instrument angle needed to remove proximal fragments in the synovial plica is difficult to obtain in the standing patient due to the close distance between the ground and the instrument portal).

As in the human field, equine surgeons are progressively increasing the number of procedures that are performed standing under sedation or in a minimally invasive fashion to reduce the cost and risks associated with general anaesthesia.<sup>5–11,15</sup> There are clear benefits associated with the reported technique and this may encourage more equine surgeons to perform standing metacarpophalangeal and

metatarsophalangeal joint arthroscopy. First, the reported technique allows safe and thorough arthroscopic examination of the dorsal aspect of the metacarpophalangeal and metatarsophalangeal joint. Second, it has not been reported, but it is likely that some surgeons are concerned over damaging the 4-mm arthroscope when standing arthroscopy is first attempted. Hence, this lower value arthroscope could be used by surgeons willing to develop or improve their standing arthroscopic skills. It is worth mentioning that the needle arthroscope is conceived as a disposable instrument and has a limited lifespan. Undoubtedly, this limited lifespan will affect the expense in arthroscopes that a practice will make in the long term. We found that the arthroscopes worked well for five to eight uses which is higher than the three to six uses reported for stifle arthroscopy where the arthroscope may suffer more bending or torqueing.<sup>11</sup> Third, the maneuverability of the needle arthroscope was considered excellent and the learning process was quick and relatively simple. The surgeon who performed the procedures felt prepared to move to live animals after getting familiarized with the technique and the system in two cadaveric pilots. This point may be crucial for those reluctant to move from the surgery under general anaesthesia to a theoretically more challenging standing surgery. The needle arthroscope can be easily introduced into the joint without requiring maximal joint distension, is easily manipulated inside the joint and possibly reduces the risk of iatrogenic damage to the sagittal ridge of the MC3/MT3 due to its small diameter. Finally, the portability of the system opens the door to the possibility of performing standing fetlock arthroscopy in an ambulatory setting which can be attractive for surgeons working on an ambulatory basis.

Despite all the benefits previously mentioned, there are also limitations to the reported technique. The needle arthroscope has a 10-degree lens viewing angle rather than 30-degree (4-mm arthroscope) and the field of view is therefore smaller. This did not affect our ability to explore and evaluate the metacarpophalangeal and metatarsophalangeal joint, but it does require working closer to the area of interest. Also, the quality of the image produced by the system is of diagnostic quality but of lower quality than most modern arthroscopic towers (►Fig. 5). The use of a bigger cannula, as described for the last 11 horses, is strongly recommended if an instrument portal is to be performed (►Fig. 4). It has been previously suggested that standing arthroscopy of the metacarpophalangeal and metatarsophalangeal joint should not be attempted unless the surgeon already masters the technique under general anesthesia.<sup>7</sup> We are in agreement with that statement and we also find of importance that the surgeon is familiar with the needle arthroscope system before attempting the procedure in live animals. The smaller field of view, the lower image quality and the smaller screen of the system require some adaptation for the novel operator.

The majority of the horses included in our study were Warmbloods (12/21) where dorsoproximal first phalanx fragments and fragments embedded in the synovial plica are often removed prophylactically (16/21 of our cases).<sup>2,3</sup> It has been

previously suggested that the horse age and/or size of the fragment may be associated with arthroscopic changes or lameness in Warmbloods.<sup>2,3</sup> Thus, a standing technique that reduces the cost and risks associated with general anaesthesia for fragments removed preventively is of additional benefit.

The described technique provides an alternative method for standing arthroscopy of the metacarpophalangeal and metatarsophalangeal joint in horses and allowed successful removal of dorsal osteochondral fragmentation in 21 horses. We do not suggest that needle arthroscopy should completely replace the use of a standard 4-mm arthroscope for standing arthroscopy of the metacarpophalangeal and metatarsophalangeal joint in all cases. However, needle arthroscopy offers some benefits, such as lower short-term cost in case of damage, excellent maneuverability and easier portability. These advantages could predispose equine surgeons untrained or reluctant to perform standing arthroscopy to be more willing to attempt the technique. In addition, the learning curve to use the system is not steep for an experienced arthroscopist. For all these reasons, we are currently investigating the diagnostic and treatment capabilities of the needle arthroscope in other joints and anatomic locations.

#### Author Contribution

The author contributed to conception of study, study design, data acquisition, and data analysis and interpretation. The author also drafted, revised and approved the submitted manuscript.

#### Funding

No funding was received.

#### Conflict of Interest

The authors declare no financial or other conflicts related to Biovision or this study.

#### Acknowledgments

We would like to thank all the clients and referring veterinarians who supported the use of this technique. Also, thank you to all the personnel from the equine hospital involved during the procedures.

#### References

- Walsh R, Smith MRW, Wright IM. Frequency distribution of osteochondral fragmentation of the dorsoproximal articular surface of the proximal phalanx in racing Thoroughbreds in the UK. *Equine Vet J* 2018;50(05):624–628
- Declercq J, Martens A, Maes D, Boussauw B, Forsyth R, Boening KJ. Dorsoproximal proximal phalanx osteochondral fragmentation in 117 Warmblood horses. *Vet Comp Orthop Traumatol* 2009;22(01):1–6
- Declercq J, Martens A, Bogaert L, Boussauw B, Forsyth R, Boening KJ. Osteochondral fragmentation in the synovial pad of the fetlock in Warmblood horses. *Vet Surg* 2008;37(07):613–618
- McIlwraith CW, Nixon AJ, Wright IM. Diagnostic and surgical arthroscopy of the metacarpophalangeal and metatarsophalangeal Joints. In: *Diagnostic and Surgical Arthroscopy in the Horse*. 4th ed. Edinburgh, NY: Mosby Elsevier; 2014:111–174
- O'Brien T, Hunt RJ. Recent advances in standing equine orthopedic surgery. *Vet Clin North Am Equine Pract* 2014;30(01):221–237

- 6 Gasiorowski JC, Richardson DW. Diagnostic and therapeutic arthroscopy in the standing horse. *Vet Clin North Am Equine Pract* 2014;30(01):211–220
- 7 Elce YA, Richardson DW. Arthroscopic removal of dorsoproximal chip fractures of the proximal phalanx in standing horses. *Vet Surg* 2002;31(03):195–200
- 8 Barakzai SZ, Dixon PM. Standing equine sinus surgery. *Vet Clin North Am Equine Pract* 2014;30(01):45–62
- 9 Rice MK, Henry TJ. Standing intraoral extractions of cheek teeth aided by partial crown removal in 165 horses (2010–2016). *Equine Vet J* 2018;50(01):48–53
- 10 Easley JT, Hendrickson DA. Advances in laparoscopic techniques and instrumentation in standing equine surgery. *Vet Clin North Am Equine Pract* 2014;30(01):19–44
- 11 Frisbie DD, Barrett MF, McIlwraith CW, Ullmer J. Diagnostic stifle joint arthroscopy using a needle arthroscope in standing horses. *Vet Surg* 2014;43(01):12–18
- 12 Halbrecht JL, Jackson DW. Office arthroscopy: a diagnostic alternative. *Arthroscopy* 1992;8(03):320–326
- 13 Voigt JD, Mosier M, Huber B. In-office diagnostic arthroscopy for knee and shoulder intra-articular injuries its potential impact on cost savings in the United States. *BMC Health Serv Res* 2014;14:203
- 14 American Association of Equine Practitioners. Guide for veterinary service and judging of equestrian events. 4th ed. Lexington, Kentucky: American Association of Equine Practitioners; 1991:19
- 15 Senior JM. Morbidity, mortality, and risk of general anesthesia in horses. *Vet Clin North Am Equine Pract* 2013;29(01):1–18