

# Morphological Variations of an Atypical Cleft Hand: A Cadaveric Case Report

Srinivasa Rao Sirasanagandla<sup>1</sup> Mohamed Al Mushaiqri<sup>1</sup> Hussein Saleem Jawad Al Khabori<sup>2</sup>  
Roaa Abdullah Mohsin Al Rashdi<sup>2</sup>

<sup>1</sup>Department of Human and Clinical Anatomy, College of Medicine and Health Sciences, Sultan Qaboos University, Muscat, Al Khoudh, Oman

<sup>2</sup>College of Medicine and Health Sciences, Sultan Qaboos University, Muscat, Al Khoudh, Oman

Address for correspondence Mohamed Al Mushaiqri, Department of Human and Clinical Anatomy, College of Medicine and Health Sciences, P O Box 35, Sultan Qaboos University, Muscat, Al Khoudh 123, Oman (e-mail: mohamed@squ.edu.om).

J Morphol Sci 2019;36:295–298.

## Abstract

Cleft hand is a group of hand deformities in which the central digits of the hand are congenitally absent. The soft tissue variations of cleft hand are rarely described. Hence, we report the anatomic variants of a unilateral atypical cleft hand with the absence of all of the phalanges of the middle finger. The 2<sup>nd</sup> and 3<sup>rd</sup> lumbricals showed a variation in their distal attachment. Both the superficial and deep flexor digital tendons of the missing middle finger were fused and inserted into the palmar surface of the head of the 3<sup>rd</sup> metacarpal bone. The extensor digitorum tendon of the missing finger was inserted on the dorsal surface of the head of the 3<sup>rd</sup> metacarpal bone. The palmar digital nerves of the median nerve of the middle finger formed 2 visible fibrotic masses; radial and ulnar, over the base of the 2<sup>nd</sup> web space. Of these, the radial mass was formed by the fusion of both palmar digital nerves and the common palmar digital artery. The knowledge of soft tissue abnormalities reported here is clinically important to plastic surgeons while restoring the good grasp and pinch of the cleft hand. The occurrence of fibrotic masses reported in the present case is unique, and these masses may cause diagnostic errors during an angiographic procedure.

## Keywords

- ▶ lumbrical
- ▶ cleft hand
- ▶ variation
- ▶ plastic surgeon
- ▶ deformity

## Introduction

Cleft hand is a group of hand deformities in which the central digits of the hand are congenitally absent.<sup>1</sup> This hand deformity is described with many other terms, including split-hand complex, pincer cleft hand, lobster-claw, crab claw hand, and ectrodactyly. However, currently, the term cleft hand is the most widely accepted to refer to this deformity.<sup>1–3</sup> Cleft hand may be associated with other congenital deformities. It is the 5<sup>th</sup> commonest anomaly of the hand. About 2.5% of the children with congenital deformities of the hand have a cleft hand.<sup>4</sup> Cleft hand is classified into two types; typical cleft hand, characterized by a V-shaped cleft, and atypical cleft hand, characterized by a U-shaped cleft.<sup>5</sup> The typical cleft hand affects 1 in 90 thousand births, and 1 in 20 thousand from

the general population. On other hand, the atypical cleft hand affects 1 in 150 thousand births, and 1 in 200 thousand in the general population.<sup>6</sup> The hand deformities are due to chromosomal defects caused by exposure to teratogens and to maternal metabolic diseases during a critical period of the embryonic development.<sup>2</sup> The soft tissue variations of cleft hand are rarely reported in the literature.<sup>7</sup> In the present case, we report the anatomic variants of a unilateral atypical cleft hand in an elderly male cadaver.

## Case Report

During regular dissection classes, we came across a unilateral atypical cleft hand in an elderly male cadaver. It was noted during the summer semester teaching for undergraduate

received  
January 21, 2019  
accepted  
March 28, 2019

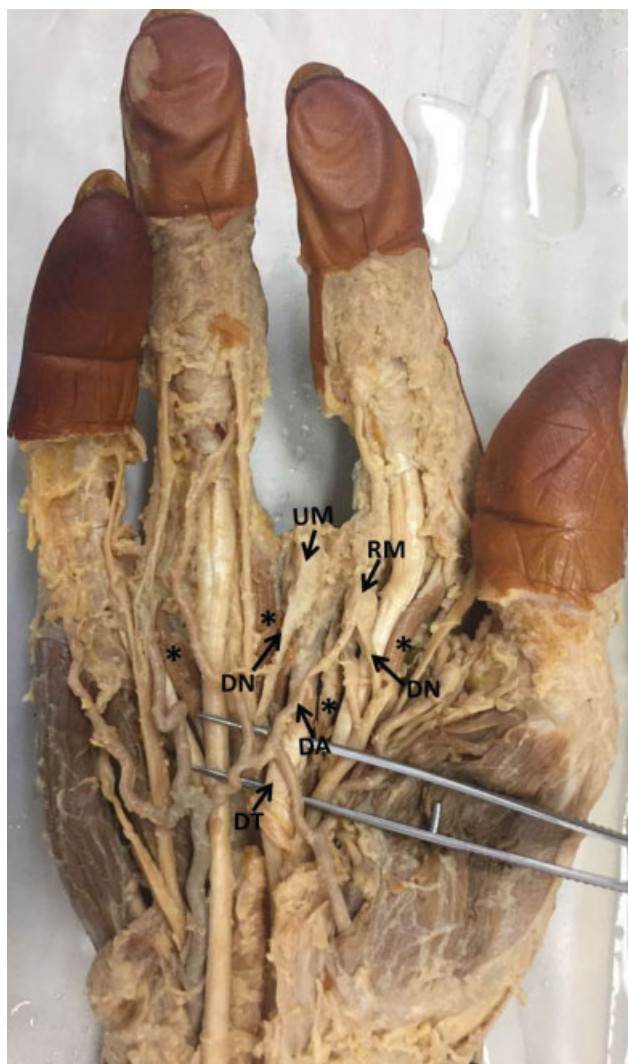
DOI <https://doi.org/10.1055/s-0039-1688808>.  
ISSN 2177-0298.

Copyright © 2019 by Thieme Revinter Publicações Ltda, Rio de Janeiro, Brazil

License terms



medical students in the year of 2018, in the Department of Human and Clinical Anatomy of the College of Medicine of the Sultan Qaboos University, Oman. The cleft hand showed the absence of all of the phalanges of the middle finger. Its metacarpal bone was of normal size and formed the base of the 2<sup>nd</sup> web space. There were no associated malformations or deformities of lower limbs, ears, lips or of the palate. To explore the arrangement of digital tendons and lumbricals, the hand was carefully dissected. There were four lumbricals and no variation was found in their origin. The 1<sup>st</sup> and 2<sup>nd</sup> lumbricals were inserted into the radial and ulnar sides of the extensor digital expansion of the index finger, respectively. The 3<sup>rd</sup> lumbrical close to the base of the 2<sup>nd</sup> web space was divided into 2 unequal slips; the small radial slip was merged with the transverse metacarpal ligament over the head of the 3<sup>rd</sup> metacarpal bone, the larger ulnar slip was inserted into the radial side of the extensor digital expansion of the ring finger. The 4<sup>th</sup> lumbrical was inserted into the radial side of the extensor digital expansion of little finger.

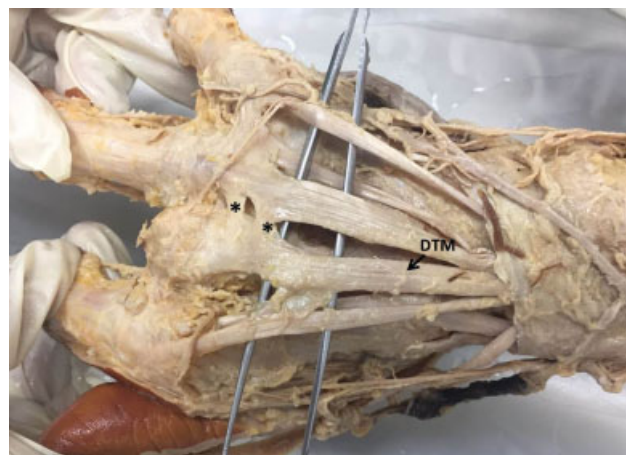


**Fig. 1** Dissection of the right hand showing the distal attachment of four lumbricals (asterisk). Note the insertion of the flexor digital tendons (DT) over the head of the 3<sup>rd</sup> metacarpal bone. The two fibrotic masses: ulnar mass (UM) and radial mass (RM) formed by the fusion of (DN) and (DA) are also seen.

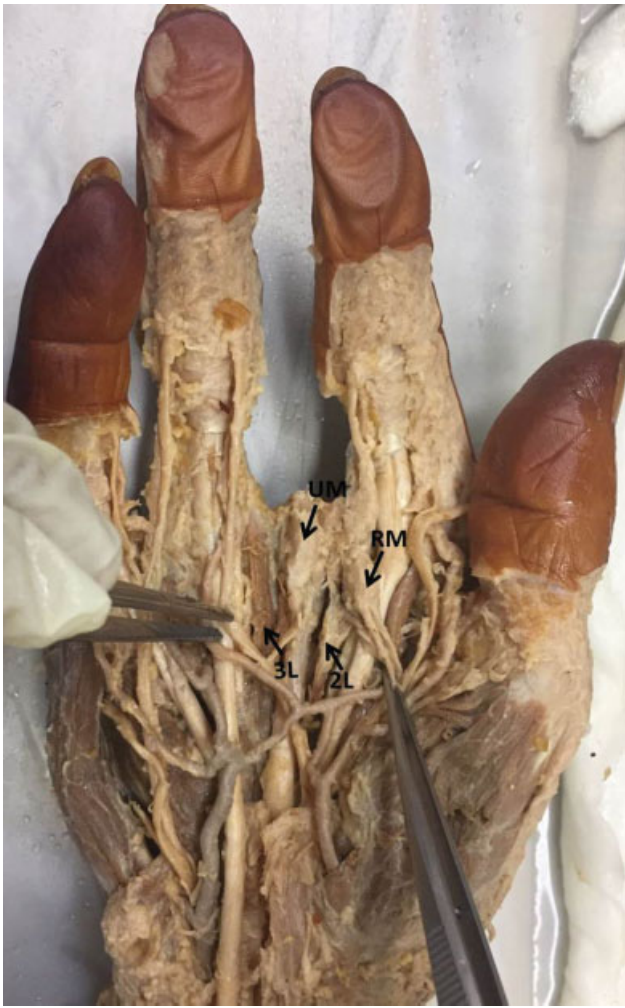Both superficial and deep flexor digital tendons of the missing middle finger were fused and inserted on the palmar surface of the head of the 3<sup>rd</sup> metacarpal bone [►Fig. 1]. The extensor digitorum tendon of the missing finger was inserted on the dorsal surface of the head of the 3<sup>rd</sup> metacarpal bone. Just before the insertion site, the tendon had thick tendinous interconnections with extensor tendons of the index and ring fingers (►Fig. 2). The palmar digital nerves of the median nerve of the middle finger formed 2 visible fibrotic masses; radial and ulnar, over the base of the 2<sup>nd</sup> web space. Of these, the radial mass was formed by fusion of both palmar digital nerves, as well as a common palmar digital artery from the superficial palmar arch of the missing finger (►Figs. 1 and 3). No variations were observed in the left hand (►Fig. 4).

## Discussion

Although cleft hand has many variations, absence of the central portion of the hand is the most common feature of this condition. Deficiency of the central portion may include absence of phalanges, of a whole individual digit, or of all digits. The palmar cleft can be shallow or deep, depending upon the growth of the remaining metacarpal bones. Usually, the wider clefts are associated with an overly adducted or deficient thumb.<sup>4</sup> Classically, the cleft hand is classified into two types: typical and atypical. The typical cleft hand is usually V-shaped, bilateral, involves the foot and is presented as a syndrome along with other anomalies such as anencephaly, cleft lip, and cleft palate. This type of anomaly usually displays a familial inheritance. On the other hand, the atypical cleft hand is usually U-shaped, unilateral, sporadic, only involves one limb, and often the metacarpals are absent and the thumb and little finger are hypoplastic. It is not associated with any other anomalies.<sup>3</sup> Currently, the atypical cleft hand is referred to as symbrachydactyly.<sup>4</sup> The condition is mainly due to a developmental arrest in the formation of the phalanges and of the metacarpals, and usually two



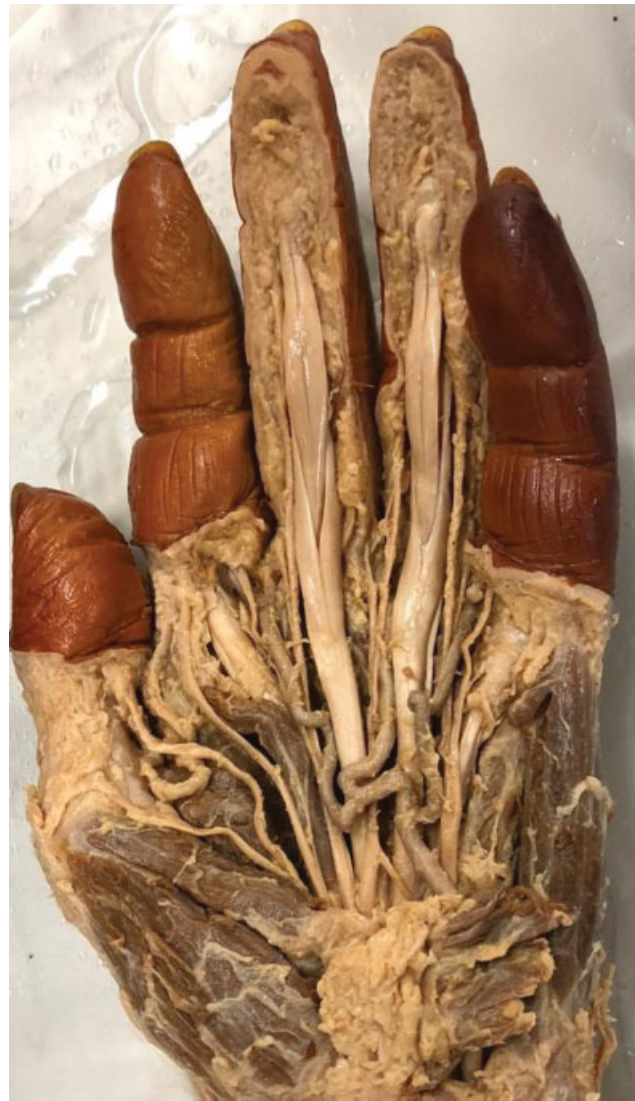**Fig. 2** Dissection of the right hand showing the distal attachment of the extensor digitorum tendon of the middle finger (DTM) over the head of the 3<sup>rd</sup> metacarpal bone. Note the tendinous interconnections (asterisk) between the extensor tendons of the ring finger and the missing middle finger.



**Fig. 3** Dissection of the right hand showing the distal attachment of the 2<sup>nd</sup> lumbrical (2L) and of the 3<sup>rd</sup> lumbrical (3L). Note the position of the 2 fibrotic masses: ulnar mass (UM) and radial mass (RM) at the base of the palmar cleft.

central digits are involved.<sup>2</sup> The remains of the missing finger will still possess some active movement. The present case may fall under the atypical category due to it being unilateral and having a U-shaped cleft. However, in the present case, contrary to the classical atypical cleft hand, the thumb, the ring and little fingers are of normal size.

In cleft hand deformity, the bone abnormalities are more frequent than those of soft tissues. They include fusion of adjacent metacarpals, bony bridges across the digits, and proximal phalanx having articulation with two metacarpals. Carpal bones may also show abnormalities.<sup>7</sup> In our case, the three phalanges of the middle finger were absent. There were no other bony abnormalities. Generally, the flexor and extensor tendons of the missing fingers fuse with each other to form tendinous loops over the rudimental carpal or metacarpal bones. The altered bony configuration may lead to extrinsic and intrinsic muscle abnormalities.<sup>7</sup> In our case, the flexor and extensor digital tendons are inserted over the head of the metacarpal bone of the missing middle finger. The 2<sup>nd</sup> and 3<sup>rd</sup> lumbricals showed variations in their distal attachment.



**Fig. 4** Dissection of the left hand showing the presence of all digits.

Angiography studies on cleft hand have demonstrated the normal development of digital arteries.<sup>8</sup> However, they are variable in number, with normal origin pattern from the radial and ulnar arteries.<sup>7</sup> In our case, there were two fibrotic masses at the base of the palmar cleft. They are formed by the fusion of the palmar digital artery with the palmar digital nerve (median nerve). More research is warranted to understand the embryological basis for occurrence of these fibrotic masses.

The functional limitation and psychiatric morbidity are the main concerns in patients with cleft hand deformity. Plastic surgery followed by rehabilitation with or without prosthesis is preferred in these patients to restore the active movements and pinch.<sup>9</sup> The reported soft tissue abnormalities in the present case are accidental during cadaveric dissection and are of academic interest. The knowledge of these abnormalities will be helpful to plastic surgeons working in this field for successful management. To the best of our knowledge, the fibrotic masses reported in the present case are unique and these masses may cause diagnostic errors during angiographic procedures.

**Financial Disclosure**

None to disclose.

**Conflicts of Interests**

The authors have no conflicts of interests to disclose

**Acknowledgments**

None to disclose.

**References**

- 1 Sadler TW. Teratology. 11th Edition. New Delhi: Wolter Klauer Health (India) Pvt. Ltd; 2009. Clinical correlates. In- Skeletral system (ch. 9). Langman's medical embryology; pp. 136-41.
- 2 Buss PW. Cleft hand/foot: clinical and developmental aspects. *J Med Genet* 1994;31(09):726-730
- 3 Swanson AB. A classification for congenital limb malformations. *J Hand Surg Am* 1976;1(01):8-22
- 4 Baba AN, Bhat YJ, Ahmed SM, Nazir A. Unilateral cleft hand with cleft foot. *Int J Health Sci (Qassim)* 2009;3(02):243-246
- 5 Durowaye M, Adeboye M, Yahaya-Kongoila S, et al. Familial ectrodactyly syndrome in a nigerian child: a case report. *Oman Med J* 2011;26(04):275-278
- 6 Tertarry SA, McKuisk VA. Absence deformities as isolated malformations. In: Bergsma D, Mudge JR, Paul NW, Greene Sc, editors. *The Genetics of Hand Malformations*. New York: Alan R Liss, Inc; 1978:36
- 7 Durand S, Delmas V, Fox M, Hivelin M, Oberlin C, Guero S. Anatomic variations in a cleft hand of an elder cadaveric specimen. *Surg Radiol Anat* 2009;31(02):145-148
- 8 Ueba Y, Buck-Gramcko D. Cleft hand. *Congenital Malformations of the Hand and Forearm*. 1998 London: Churchill Livingstone; 199-215
- 9 Snow JW, Littler JW. Surgical treatment of cleft hand. In: *Transactions of the International Society for Plastic Reconstructive Surgery, Fourth Congress, Rome., Excerpta Medical Foundation*. 1967:888-93