

# Sciatic Nerve to Pudendal Nerve Transfer: Anatomical Feasibility for a New Proposed Technique

Pawan Agarwal<sup>1</sup> Dhananjaya Sharma<sup>2</sup> Sudesh Wankhede<sup>2</sup> P.C. Jain<sup>3</sup> N.L. Agrawal<sup>3</sup>

<sup>1</sup>Plastic Surgery Unit, NSCB Government Medical College, Jabalpur, Madhya Pradesh, India

<sup>2</sup>Department of Surgery, NSCB Government Medical College, Jabalpur, Madhya Pradesh, India

<sup>3</sup>Department of Anatomy, NSCB Government Medical College, Jabalpur, Madhya Pradesh, India

**Address for correspondence** Pawan Agarwal, MS, MCh, PhD, DNB, FRCS (Glasgow), 292/293, Napier Town, Jabalpur, 482003 MP, India (e-mail: drpawanagarwal@yahoo.com).

Indian J Plast Surg 2019;52:222–225

## Abstract

**Aim** Restoration of bladder and bowel continence after pudendal nerve anastomosis has been shown successfully in animal models and may be applicable in humans. Aim of this cadaveric study was to assess feasibility of pudendal nerve neurotization using motor fascicles from sciatic nerve.

**Methods** Pudendal and sciatic nerves were exposed via gluteal approach in 5 human cadavers (10 sites). Size of pudendal and sciatic nerves and the distance between two nerves was measured.

**Results** There were four male and one female cadavers. Mean age was 62 (range, 50–70) years. Mean pudendal nerve diameter was 2.94 mm (right side) and 2.82 mm (left side). Mean sciatic nerve diameter was 11.2 mm (right side) and 14.2 mm (left side). The distance between two nerves was 23.4 mm on both sides.

**Conclusion** Transfer of the motor fascicles from sciatic nerve to pudendal nerve to restore the bladder and bowel continence is feasible.

## Keywords

- ▶ sciatic nerve
- ▶ pudendal nerve
- ▶ neurotization
- ▶ incontinence
- ▶ bladder
- ▶ spinal cord injury

## Introduction

The innervation of lower urinary tract is controlled by a complex neural circuit between the brain, spinal cord, and bladder that coordinates urine storage and emptying.<sup>1</sup>

Damage to the pudendal nerve or sacral roots results in bladder and bowel incontinence which is associated with embarrassment, depression, and social isolation leading to decrease in quality of life and significant socioeconomic impact.<sup>2</sup> Restoration of bladder/bowel function by nerve transfer has the potential to markedly improve quality of life, and help prevent long-term complications. In this cadaveric study, we assessed the feasibility of transfer of motor fascicles from the sciatic nerve to the pudendal nerve to improve bladder and bowel continence.

## Material and Methods

This study was conducted in the plastic surgery unit of department of surgery and department of anatomy in a tertiary referral center in Central India over a period of 2 months.

Institutional ethical committee approval was obtained. Five formalin (10%)-fixed cadavers were dissected. Cadavers were inspected to ensure that the gluteal area anatomy was intact. Cadaver was placed in prone position and dissection proceeded with a gluteal approach for the pudendal nerve and sciatic nerve exposure by using the technique described by O'Bichere et al.<sup>3</sup> The midpoint of the lateral border of the sacrum, the ischial tuberosity, and the ipsilateral greater trochanter of the femur were identified and marked (▶Fig. 1). An incision was made through the skin and subcutaneous tissue from the mid sacrum to the ischial tuberosity, and curved upwards and laterally to the greater trochanter to create a flap that was reflected to reveal oblique fibers of the distal one-half of the gluteus maximus (▶Fig. 2). The exposed gluteus maximus fibers were split and retracted to expose the glistening fibers of the sacrotuberous ligament (▶Fig. 3). Sacrotuberous ligament was then divided at its distal attachment and drawn outwards. Pudendal neurovascular bundle lies along its free border in Alcock's canal. The sciatic nerve was exposed lateral to the ischial tuberosity (▶Fig. 4). Size

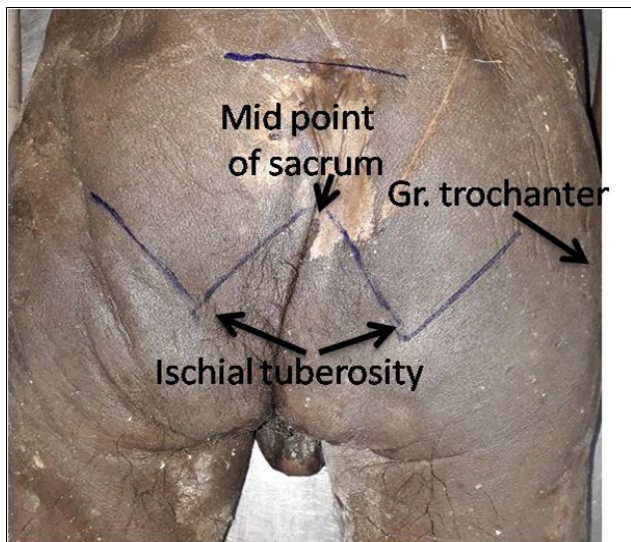


Fig. 1 Surface marking for exposure of the sciatic and pudendal nerves.

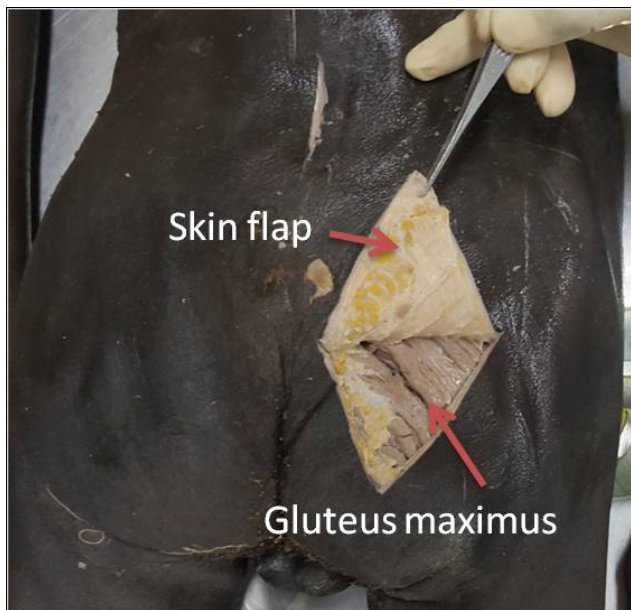

Fig. 2 Skin flap raise and gluteus maximus muscle exposed.

of the pudendal and sciatic nerves and distance between the two nerves were measured with the help of vernier calipers and a flexible measuring tape.

**Results**

Pudendal and sciatic nerves were exposed in 5 (4 male and 1 female) human cadavers (10 sites). Mean age was 62 (range = 50–70) years. Mean pudendal nerve diameter was 2.94 mm (range = 2.7–3.1 mm) on the right side and 2.82 mm (range = 2.5–3 mm) on the left. Mean sciatic nerve diameter was 11.2 mm (range = 9–14 mm) on the right side and 14.2 mm (range = 9–20 mm) on the left side. The distance between the two nerves was 23.4 mm (range = 20–26 mm) on both sides (► **Table 1**).

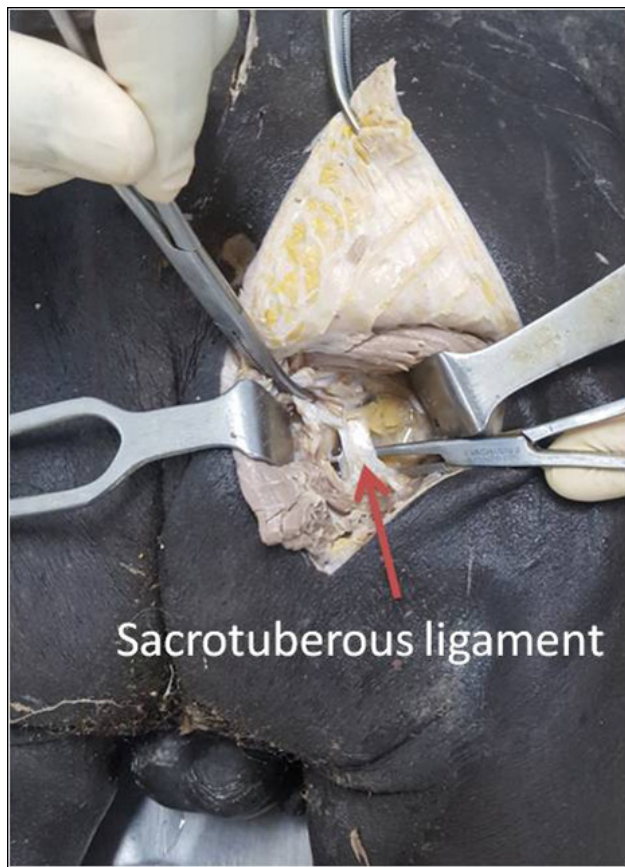


Fig. 3 Gluteus maximus split and sacrotuberous ligament exposed.

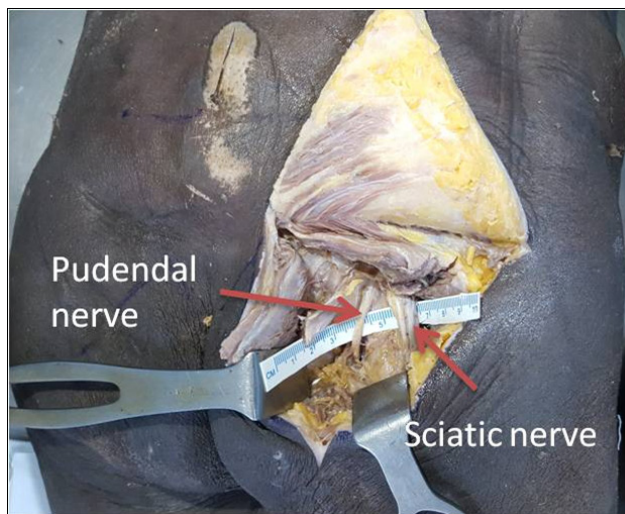


Fig. 4 Sacrotuberous ligament cut and pudendal nerve exposed in Alcock's canal and sciatic nerve lateral to ischial tuberosity.

**Discussion**

The pudendal nerve and its branches are susceptible to injury especially during surgery for ischiorectal abscess/fistula, hemorrhoidectomies, pudendal canal decompression, pelvic/perineal surgery, and in orthopedic surgery, with the incidence as high as 15%.<sup>4–6</sup> Symptoms range from mild perineal sensory deficit, with or without sexual dysfunction, to urinary and

**Table 1** Demographic details of patients with the size of the nerves

Cadaver	Age, Y	Sex	Pudendal nerve diameter (mm)		Sciatic nerve diameter (mm)		Distance between two nerves (mm)	
			Right	Left	Right	Left	Right	Left
1	65	M	2.9	3	10	9	21	25
2	70	M	3	2.6	11	13	23	25
3	60	F	2.7	2.5	9	12	25	26
4	50	M	3	3	12	20	22	21
5	65	M	3.1	3	14	17	26	20
Average	62		2.94	2.82	11.2	14.2	23.4	23.4

Abbreviations: F, female; M, male.

fecal incontinence. Lesions of the conus medullaris, cauda equina, sacral meningocele, sacral tumor/fractures, and pelvic exenteration for colonic/gynecological malignancies may also lead to pudendal nerve/sacral roots damage. The extent of nerve damage is dependent on its etiology. For patients with nerve entrapment and compression (difficult childbirth, orthopedic/gynecological procedures, or avid cycling), the damage is not permanent and the nerve recovers spontaneously or needs decompression/neurolysis. Severe and permanent nerve damage is rare but will lead to urinary/fecal incontinence, perineal pain/anesthesia, and bladder/sexual dysfunction.

Pudendal nerve carries both motor (efferent pathway) and sensory fibers (afferent pathway) and both can be affected by injury to this nerve. Efferent pathway is mainly responsible for sphincter continence, while afferent pathway is inhibitory and can suppress bladder overactivity or hyperreflexia; therefore, pudendal nerve injury can induce both stress urinary incontinence and overactive bladder.<sup>7</sup>

Many experimental studies have demonstrated that the transection of the pudendal nerve results in reduction in the size of the external urinary sphincter, electromyogram signs of denervation, and voiding dysfunction.<sup>8</sup> Conventionally, these patients are treated by Kegel's exercises, pharmacotherapy, sling surgeries, or urethral bulking agent injections.<sup>9</sup> Pharmacotherapy to improve urinary sphincter weakness has disappointing results and only 50% patients achieve success with pelvic floor exercises. Sling surgeries have a significant associated morbidity and repeated injections of bulking agents may be required to be effective.<sup>10-12</sup>

Other options are artificial urinary sphincter, sphincteric muscle augmentation, and implantable valves. All these methods need good capacity of bladder and electrical stimulation of implantable devices. No active treatment option is currently available to address urinary incontinence, and beside the above-mentioned options, these patients are managed by indwelling urinary catheters, colostomies, or bowel programs.

During the last century, the development of nerve crossover surgeries/root repair to create new pathways between the bladder and the spinal cord to restore continence has been tried.<sup>13-16</sup> However, major complications, damage to nerve roots, sacrifice of residual function, and limited reproducibility limit their routine use.<sup>17</sup>

Restoring urinary continence through peripheral nerve transfers in animals and cadavers results in varying degrees of success and reinnervation can be objectively demonstrated by nerve-evoked detrusor contractions and retrograde labeling techniques.<sup>18</sup> Femoral and obturator nerves have been used to neurotize pudendal nerve in animal and cadaveric studies.<sup>18-20</sup> However, transfer of the obturator nerve requires laparotomy and another operation site in the thigh is needed to transfer the femoral nerve with much more difficult dissection. Additionally, when these nerves are used there is the matter of adequate length of the nerve to reach the recipient nerve with added morbidity of paralysis of adductors or part of quadriceps femoris. Moreover, these modalities have not brought about normal detrusor or sphincter function due to smaller number of motor axons.

This study was undertaken in search of simple and effective technique that can achieve consistent axonal regeneration for return of useful function. The transfer of motor fascicles from the sciatic nerve to the pudendal nerve to improve the sphincter weakness can be done as single transfer or in combination with pelvic nerve neurotization using other abdominal or extremity nerves whenever there is detrusor over activity or areflexia. This is the first anatomic study assessing the feasibility of transfer of motor fascicles from the sciatic nerve to the pudendal nerve in cadavers. The size of the sciatic nerve in the gluteal area was 11.2 to 14.2 mm and the diameter of the pudendal nerve was 2.83 to 2.92 mm. Previous studies have shown the average diameter of the pudendal nerve to be from 3.2 to 5.5 mm.<sup>21</sup> Both the nerves lay very close to each other in the gluteal area and their exposure is very easy with single incision. When the pudendal nerve is neurotized in Alcock's canal, distance to the end organ (external urinary/rectal sphincter) is much shorter in contrast to when neurotization is done at the level of root repair; therefore, functional recovery can be expected in shorter period of time. The sciatic nerve has large number of axons (1,200-1,300 of motor and sensory fibers) and its location is very close to the pudendal nerve in the gluteal region (average distance: 23.4 mm). The number of fascicles required to neurotize the pudendal nerve would be 3 to 4. The sciatic nerve has consistent anatomy and fascicular morphology with sufficient branch-free length in the gluteal area for transfer without tension. The sciatic nerve's fascicles

fuse and divide throughout the course of the nerve forming an intraneural plexus. Because of this special anatomic consideration, partial division of the sciatic nerve does not produce motor or sensory change or one of transient nature only.<sup>22</sup> Harvesting of few motor fascicles from the nerve will not cause any functional deficit as extrapolated from other studies on brachial plexus repairs.<sup>23</sup>

In cases of sacral roots injuries, there may be problems using sciatic nerve because it will be partially denervated. In these cases, the L4, L5, and S1 segments of the sciatic nerve can be used which supplies the gluteal or obturator internus muscles.

All these cadaveric and animal experimentations have shown that the peripheral nerves can be used to restore bladder/bowel continence in lower motor neuron lesions and isolated pudendal nerve injury with minimum morbidity. However, identification of preoperative evaluation tests to select the appropriate patient needs to be done before this knowledge can be applied in humans.

## Conclusions

Transfer of the motor fascicles from the sciatic nerve to the pudendal nerve to restore bladder and rectal incontinence is feasible in lower motor neuron lesions and isolated pudendal nerve injury. The dissection of the sciatic nerve and pudendal nerve is relatively easy and reproducible in the gluteal area. Sciatic to pudendal nerve neurotization can be performed to improve the function of bladder/bowel sphincters and pelvic floor muscles.

### Conflict of Interest

None.

## References

- 1 Yoshimura N, de Groat WC. Neural control of the lower urinary tract. *Int J Urol* 1997;4(2):111–125
- 2 Wilson L, Brown JS, Shin GP, Luc KO, Subak LL. Annual direct cost of urinary incontinence. *Obstet Gynecol* 2001;98(3):398–406
- 3 O'Bichere A, Green C, Phillips RK. New, simple approach for maximal pudendal nerve exposure: anomalies and prospects for functional reconstruction. *Dis Colon Rectum* 2000;43(7):956–960
- 4 Kao JT, Burton D, Comstock C, McClellan RT, Carragee E. Pudendal nerve palsy after femoral intramedullary nailing. *J Orthop Trauma* 1993;7(1):58–63
- 5 Shetty SD, Kirkemo AK. Bilateral bone anchor vaginal vault suspension: an initial report of a new technique. *Tech Urol* 1997;3(1):1–5
- 6 Gillitzer R, Hampel C, Wiesner C, Pahernik S, Melchior SW, Thüroff JW. Pudendal nerve branch injury during radical perineal prostatectomy. *Urology* 2006;67(2):423.e1–423.e3
- 7 Christianson JA, Liang R, Ustinova EE, Davis BM, Fraser MO, Pezzone MA. Convergence of bladder and colon sensory innervation occurs at the primary afferent level. *Pain* 2007;128(3):235–243
- 8 Heidkamp MC, Leong FC, Brubaker L, Russell B. Pudendal denervation affects the structure and function of the striated, urethral sphincter in female rats. *Int Urogynecol J Pelvic Floor Dysfunct* 1998;9(2):88–93
- 9 Kreder KJ, Austin JC. Treatment of stress urinary incontinence in women with urethral hypermobility and intrinsic sphincter deficiency. *J Urol* 1996;156(6):1995–1998
- 10 Cammu H, Van Nysten M, Amy JJ. A 10-year follow-up after Kegel pelvic floor muscle exercises for genuine stress incontinence. *BJU Int* 2000;85(6):655–658
- 11 Hassouna ME, Ghoniem GM. Long-term outcome and quality of life after modified pubovaginal sling for intrinsic sphincteric deficiency. *Urology* 1999;53(2):287–291
- 12 Winters JC, Chiverton A, Scarpero HM, Prats LJ Jr. Collagen injection therapy in elderly women: long-term results and patient satisfaction. *Urology* 2000;55(6):856–861
- 13 Brindley GS. The first 500 patients with sacral anterior root stimulator implants: general description. *Paraplegia* 1994;32(12):795–805
- 14 Xiao CG. Reinnervation for neurogenic bladder: historic review and introduction of a somatic-autonomic reflex pathway procedure for patients with spinal cord injury or spina bifida. *Eur Urol* 2006;49(1):22–28, discussion 28–29
- 15 Ruggieri MR, Braverman AS, D'Andrea L, McCarthy J, Barbe MF. Functional reinnervation of the canine bladder after spinal root transection and immediate somatic nerve transfer. *J Neurotrauma* 2008;25(3):214–224
- 16 Barbe MF, Ruggieri MR Sr. Innervation of parasympathetic postganglionic neurons and bladder detrusor muscle directly after sacral root transection and repair using nerve transfer. *NeuroUrol Urodyn* 2011;30(4):599–605
- 17 Tuite GF, Storrs BB, Homsy YL, et al. Attempted bladder reinnervation and creation of a scratch reflex for bladder emptying through a somatic-to-autonomic intradural anastomosis. *J Neurosurg Pediatr* 2013;12(1):80–86
- 18 Tachibana E, Saito K, Fukuta K, Yoshida J. Evaluation of the healing process after dural reconstruction achieved using a free fascial graft. *J Neurosurg* 2002;96(2):280–286
- 19 Barbe MF, Brown JM, Pontari MA, Dean GE, Braverman AS, Ruggieri MR. Feasibility of a femoral nerve motor branch for transfer to the pudendal nerve for restoring continence: a cadaveric study. *J Neurosurg Spine* 2011;15(5):526–531
- 20 Brown JM, Barbe MF, Albo ME, Lai HH, Ruggieri MR Sr. Anatomical feasibility of performing intercostal and ilioinguinal nerve to pelvic nerve transfer: a possible technique to restore lower urinary tract innervation. *J Neurosurg Spine* 2012;17(4):357–362
- 21 Brown JM, Barbe MF, Albo ME, Ruggieri MR Sr. Anatomical feasibility of performing a nerve transfer from the femoral branch to bilateral pelvic nerves in a cadaver: a potential method to restore bladder function following proximal spinal cord injury. *J Neurosurg Spine* 2013;18(6):598–605
- 22 McKinley JC. The intraneural plexus of fasciculi and fibers in the sciatic nerve. *Arch Neurol Psychiatry* 1921;6:317–399
- 23 Narakas AO. The surgical treatment of traumatic brachial plexus lesions. *Int Surg* 1980;65(6):521–527