

Management of Post-Traumatic Osteomyelitis in the Lower Limb: Current State of the Art

James K. K. Chan^{1,2} Jamie Y. Ferguson² Matthew Scarborough² Martin A. McNally² Alex J. Ramsden²

¹Nuffield Department of Orthopaedics, Rheumatology and Musculoskeletal Sciences, University of Oxford, United Kingdom

²Bone Infection Unit, Oxford University Hospitals, United Kingdom

Address for correspondence James K. K. Chan, DPhil, FRCS (Plast), Registrar in Plastic Reconstructive Surgery Oxford University Hospitals Honorary Clinical Lecturer Nuffield Department of Orthopaedics, Rheumatology and Musculoskeletal Sciences, University of Oxford, United Kingdom (e-mail: james.chan@kennedy.ox.ac.uk).

Indian J Plast Surg 2019;52:62–72

Abstract

Osteomyelitis (OM) of the lower limb represents a large unmet global healthcare burden. It often arises from a contiguous focus of infection and is a recognized complication of open fractures or their surgical treatment, arthroplasty, and diabetic foot ulcers. Historically, this debilitating condition is associated with high rates of recurrence and secondary amputation. However, excellent long-term outcomes are now achieved by adopting a multidisciplinary approach with meticulous surgical debridement, skeletal and soft tissue reconstruction, and tailored antimicrobial treatment. This review focuses on the modern evidence-based management of post-traumatic OM in the lower limb from a reconstructive plastic surgery perspective, highlighting the latest developments and areas of controversy.

Keywords

- ▶ osteomyelitis
- ▶ soft tissue reconstruction
- ▶ lower limb

Introduction

Osteomyelitis (OM) is a destructive inflammatory process of bone caused by an infecting microorganism. It commonly occurs in the lower limb where it is often a result of direct bacterial invasion from surrounding tissues or implants. This is known as contiguous focus OM (cOM) and is a recognized complication of diabetic foot infections, open fractures, and implant-related surgery. Plastic surgeons most commonly encounter cOM as the surrounding soft tissues may be severely compromised and require reconstruction as a result of the underlying chronic inflammation with extensive fibrosis and discharging sinuses.

Patients with cOM can be chronically unwell and suffer considerable pain and disability with persistent wounds that discharge malodorous pus. The infection may have been present for months and even decades and is associated with reduced life expectancy.¹ Treatment of cOM typically includes a combination of surgical intervention and a prolonged course of antibiotic therapy. Failure to effectively eradicate the infection results in prolonged hospital stays, multiple surgical procedures, and may promote the selection of antibiotic resistant microorganisms. Occasionally, such infected limbs are

considered unsalvageable and amputation may become the only treatment option. Failure of treatment results in loss of mobility, unemployment, requirement for significant long-term support but rarely, uncontrolled infection and death. The economic impact of OM is substantial^{2,3} and its incidence is rising largely due to the increased prevalence of risk factors, including diabetes and orthopaedic surgery, as well as life expectancy.^{4,5}

Modern treatment strategies can now eradicate cOM with limb salvage in most patients with less surgical intervention, reduced costs, and a rapid return to society. Detailed accounts of OM and the principles of management are already available.^{6,7} This review focuses on the plastic surgical aspects in the management of post-traumatic cOM in the lower limb and presents the latest evidence-based principles, developments, and controversies.

Rationale for Surgery

OM is historically subdivided according to the source of infection, speed of onset of symptoms, and cultured microorganisms.

Microorganisms can infect bone by either hematogenous or contiguous spread. The former is more common at the

extremes of age and in immunocompromised individuals and can often be treated with antibiotics alone so rarely requires plastic surgical intervention.⁶ We will not discuss this type of OM in this review. By contrast, cOM arises from a neighboring wound and usually requires a combination of surgical intervention and antibiotic treatment.

OM is often referred to as either acute or chronic. This outdated classification is ambiguous and misleading as it has been variably used to refer to the chronicity as well as speed of onset of the infection. A preferred approach is to consider whether there is dead material at the site of infection. Dead materials such as necrotic bone and implants provide an avascular substrate to which planktonic bacteria adhere strongly.⁸ The microorganisms can survive and persist by switching to a dormant state, which renders them relatively nonsusceptible to the majority of antimicrobial agents. In addition, bacteria form a biofilm composed of extracellular polymeric substances, which is impenetrable by the host immune response. Over time, these microorganisms develop resistance to antibiotics and can also reactivate following a latent period of many years despite prolonged antimicrobial treatment.^{9,10} The combination of dead bone and biofilm makes eradication with antibiotics alone virtually impossible. Unfortunately, the presence of biofilm can only be confirmed with microscopy and histochemical staining postoperatively so the diagnosis of a biofilm-related cOM should be based on clinical assessment and imaging.

Microorganisms and Antimicrobial Treatment

The involvement of a specialist musculoskeletal infectious disease physician is critical in the diagnosis and treatment of OM and is associated with improved outcomes.¹¹

In cOM, *Staphylococcus aureus* is the most commonly cultured microorganism, but coagulase-negative staphylococci, *Cutibacterium acnes*, and gram-negative bacilli are also common, particularly in periprosthetic infections. A significant proportion of cases are polymicrobial.¹² *Clostridia* and *Nocardia* are associated with open fractures and *Pseudomonas aeruginosa* with foot infections.

More recently, increasing prevalence of bacterial resistance has given rise to greater challenges in antimicrobial treatment.^{5,12} Furthermore, a significant proportion of cases are culture negative (28%).¹² Measures to improve microbiological diagnosis and treatment include meticulous wound sampling technique,⁷ the development of laboratory techniques such as sonication and molecular diagnostics,¹³ and the use of local antibiotics.¹⁴

The choice of antimicrobial agent is governed by several factors, the most important of which is susceptibility. Meticulous surgical sampling and specimen processing are therefore essential to inform the antibiotic regimen (see section *Wound Excision and Microbiological Sampling*). Based on expert opinion, medical management for bone and joint infection was commonly believed to mandate high dose, intravenous, prolonged courses of antibiotic therapy, often for several months.¹⁵ Recent trials including the OVIVA (oral versus intravenous antibiotics for bone and joint infection) and AVAPOM trials have sought to better define

these parameters and, although data are limited, emerging evidence suggests that carefully chosen oral antibiotic regimens may be noninferior to intravenous therapy,^{16,17} and, in some circumstances, the duration of therapy has become better defined. For example, for spinal OM, 6 weeks of therapy may be sufficient¹⁸ and for certain prosthetic hip joint infections managed by debridement, antibiotics, and implant retention, 8 weeks are sufficient.¹⁹ Close liaison with the bone infection physician and follow-up to detect any recurrence is advocated.

Principles of Surgical Treatment

Assessment

Treatment of OM is complex, multifaceted and requires a dedicated multidisciplinary team.^{11,20} In our Bone Infection Unit, all new patients are assessed simultaneously by an infectious diseases' physician, an orthopaedic limb reconstruction surgeon specializing in bone infection, and when required, a plastic surgeon. Imaging is reviewed by dedicated musculoskeletal radiologists. Where necessary, vascular surgeons optimize peripheral blood flow with angioplasty preoperatively and other specialists are involved as required, including psychologists or rehabilitation physicians.

Clinical assessment involves a thorough history and examination. Pain, localized swelling, erythema, and warmth are common but not invariable. In chronic disease, the soft tissue envelope may be fibrotic with the evidence of old or actively discharging sinuses, soft tissue abscesses, and scars from previous surgery or injury. It is uncommon for patients to be systemically unwell particularly if they have a discharging sinus, but they may experience flare-ups of disease which may present with pyrexia, sweats, and anorexia. C-reactive protein, erythrocyte sedimentation rate, and white blood cells are nonspecific and may be normal in chronic discharging infection.²¹

Imaging

Plain radiographs remain the principal investigation and are particularly useful when reviewed serially. New periosteal bone formation on X-ray suggests living, vascularized bone. By contrast, dead sequestered bone is unable to form new bone or remodel, and remains radiodense, sclerotic and unchanging.

Magnetic resonance imaging (MRI) is useful for surgical planning.²² It provides good anatomical detail and enables delineation of the extent of bone and surrounding soft tissue involvement. The fluid sequences including T2-weighted, fat-suppressed, and short-tau inversion recovery sequences display fluid as high signal and are therefore useful for detecting inflammation. However, MRI use is limited in implant-related infection due to artifact. Furthermore, it can overestimate the extent of infection as differentiation between bone infection and bone edema can be difficult.

Computed tomography (CT) is useful for assessment of bone stability and fracture healing. It can identify small sequestra. If fludeoxyglucose positron emission tomography computed tomography is available, this can provide accurate targeting of infected areas particularly

when there is widespread abnormality in the bone morphology or in the presence of metalwork. It can help determine if segmental or a more limited excision is required. Radiolabeled white cell scans alone are not useful as they have a low specificity.²²

Our institution rarely performs preoperative radiologically guided biopsy, but it can be helpful in patients who are unfit for surgery and in whom microbiological specimens can be used to guide suppressive antibiotic regimens.

Preoperative Considerations

In developed nations, a significant proportion of patients with chronic post-traumatic cOM of the lower limb are group B (compromised) hosts according to the Cierny and Mader (CM) classification.^{23,24} These patients have medical conditions which directly affect the ability to heal wounds or reduce the efficacy of drug treatment. Therefore, preoperative optimization and the anesthetic assessment are critical to achieve optimal results. In our unit, regional anesthesia in the form of an epidural is frequently used as it can limit the physiological impact of the surgery and improve postoperative analgesia and recovery.²⁵

Peripheral vascular disease may compromise long-term outcome. In a series of 120 patients with chronic OM, Hong et al identified peripheral vascular disease as the only significant risk factor for recurrence of OM.²³ A hand-held Doppler ultrasound is useful in the outpatient clinic. A CT angiogram or a Duplex ultrasound can indicate whether

preoperative angioplasty may be required. Hahn et al reported their experience of microvascular reconstruction of the lower limb in patients with peripheral arterial occlusive disease and demonstrated no significant difference in the salvage rate (100%) when compared with the control (unobstructed, nonangioplastied) group (97.7%). They also found that preoperative angioplasty was not a significant predictor of increased complications or longer postoperative downtime.²⁶ However, only 8 of the 62 cases had OM.

Patients with chronic inflammation and exudative wounds are catabolic and may be nutritionally depleted. Efforts to optimize the patient to promote wound healing and reduce the risks of wound-related complications should include smoking cessation,²⁷ nutritional support and decolonization of carriers of methicillin-sensitive *S. aureus*.²⁸

Ideally all antibiotics should be stopped at least 2 weeks preoperatively to improve the culture rate of causative organisms from intraoperative samples. This may not be possible if the patient is overtly septic but is achievable in the majority. Surgery should not be undertaken prior to completing investigation and treatment of concurrent medical conditions and must be properly planned.

Principles of Surgical Management of OM

Surgery is the principal component of effective management of cOM (► Fig. 1).

The surgical principles of managing biofilm-related OM are to:

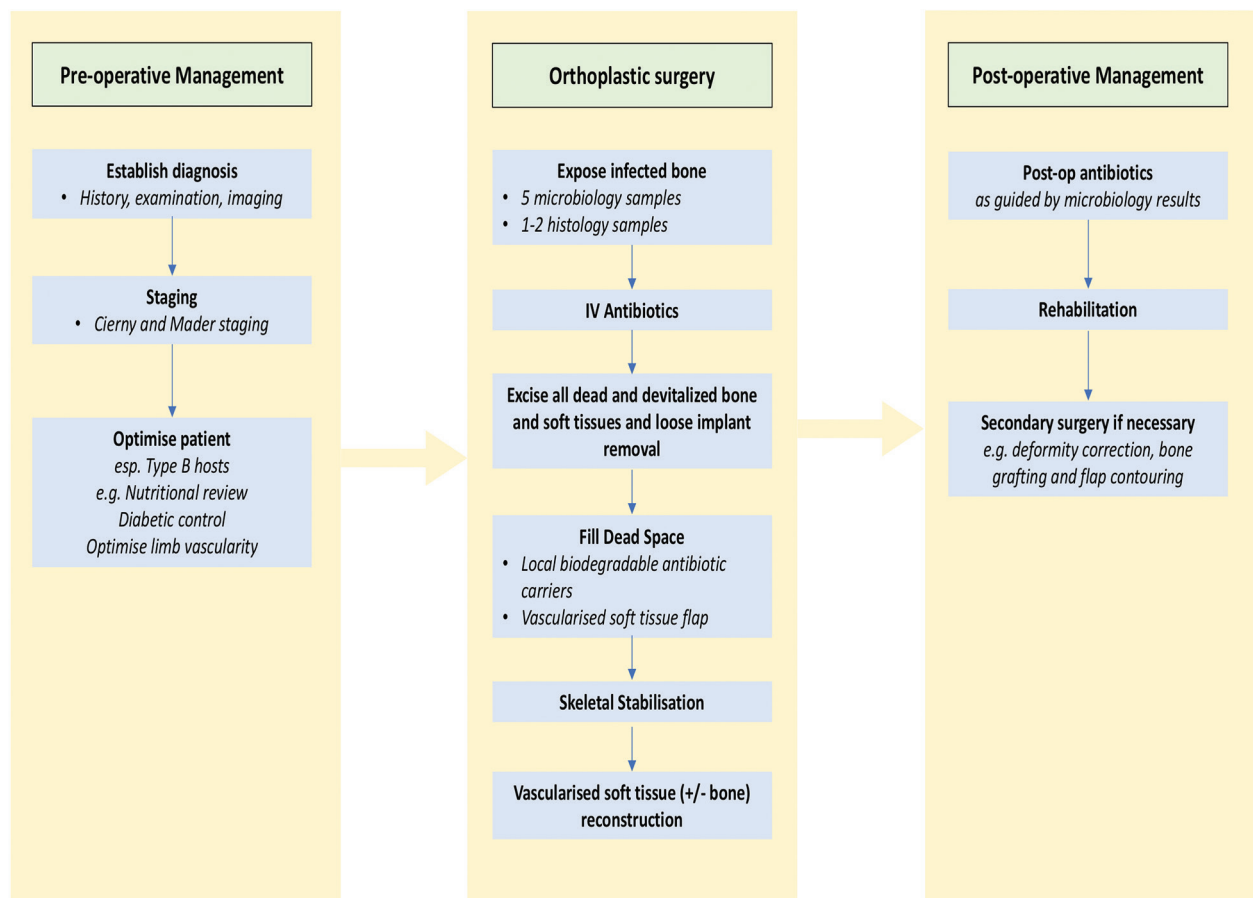


Fig. 1 Management of chronic osteomyelitis in the lower limb.

- Undertake adequate microbiological sampling
- Perform complete excision of all macroscopically devitalized tissue and implants
- Manage postexcision dead space
- Ensure adequate skeletal stabilization, and
- Provide immediate wound cover.

Failure in managing chronic OM usually stems from violation of one or more of these five principles. The most important aspect is to ensure that all macroscopically devitalized tissue and biofilm are excised to prevent recurrence. As long as healthy bleeding tissue is left behind, any planktonic bacteria still present should be adequately eradicated by the immune system and appropriate antibiotics.

Surgical Planning

It is paramount to plan the operation jointly with orthopaedic colleagues. In our unit, ~50% of patients who require joint orthoplastic reconstruction have type III OM, 40% type IV, and 20% type II. Flaps are not required in Type I (medullary) infections. Access incisions are jointly agreed to avoid damaging perforating vessels and to allow convenient access for vascular microsurgery, particularly in complex tibial defects requiring external fixation. The expected size, position, and shape of the soft tissue defect can be estimated preoperatively to allow immediate reconstruction.

Wound Excision and Microbiological Sampling

Obtaining representative samples for microbiological and histological analysis is paramount as this will guide the antibiotic regime.^{21,29-31} Samples should be taken early in the procedure to avoid contamination. The excised sinus tract should not be sent for microbiological assessment as it is usually colonized by skin flora that is not representative of the deep pathogens. Taking multiple samples, each with clean instruments to minimize cross contamination, increases the accuracy of microbiological analysis. Care is taken to avoid touching the skin with the instrument tips, fingers, or suction until sampling has been completed. Swabs should be avoided. Once taken, samples should be transported immediately to the laboratory to avoid degradation. The best tissue to sample is bone or surrounding membrane. A total of five microbiological samples is recommended if possible.^{21,29-31} This may be difficult in small bones of the hand.

Following sampling, the second stage of the operation is to expose and excise the infected region. Residual biofilm risks recurrence. A major advantage of a joint orthoplastic approach is to enable excision to be performed without fear of being unable to reconstruct the soft tissue or bone defect and hence margins are not compromised. Sharp osteotomes and chisels as well as cooled drills and burrs can be used to excise bone until it is seen to be healthy and bleeding. Abnormal bone splinters as it is cut, whereas healthy bone curls up like a wood shaving. Bone bleeding can still be seen with an inflated tourniquet. Once all the devitalized tissue and foreign material are removed, one moves onto the next stage (► Fig. 2).

Skeletal Stabilization

It is important that, following debridement, the bone is sufficiently stable to allow weight bearing. Post-operative weight bearing is important to minimize the risks of worsening

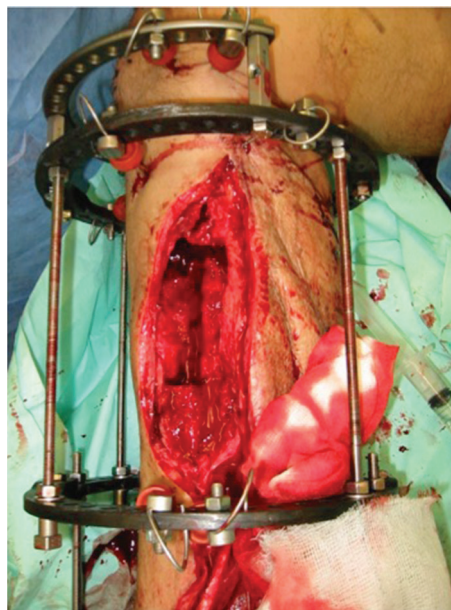


Fig. 2 Segmental excision of tibia with soft tissue defect requiring free flap coverage.

osteopenia, poor bone healing, muscle wasting and joint contracture. An assessment of the bone stability is made intraoperatively following excision. In cavity defects, with an intact bone, it may be advisable to apply a simple unilateral external fixator to allow full weight-bearing. In our practice, ~15% of patients with CM type II and III OM have external fixation to prevent fracture and allow full weight bearing (the fixator usually remains in place for ~8 weeks).

For CM type IV lesions with segmental involvement or with infected nonunions, an assessment of the bone stability is undertaken after excision.³² In stiff nonunions, we initially compress the bone with an external fixator and then distract at 1 mm per day for 10 days, or until full length is achieved. For mobile nonunions, we excise the nonunion and stabilize with an Ilizarov fixator. If possible, we acutely shorten the bone to allow bone contact at the defect and relengthen through a separate remote corticotomy (bifocal compression/distraction). If the defect is larger or the soft tissues prevent acute compression, a bone transport technique can be undertaken. If a muscle flap is needed for soft tissue cover, this can be transferred simultaneously with the frame application. The muscle will partly fill the segmental defect but will be “pushed out” during bone transport. When using a frame with a free flap, careful planning is required between the orthopaedic and plastic teams about pedicle position to allow immediate flap coverage through the frame. Fine wires can be safely placed through the flap as long as they are away from the pedicle³³ (► Figs. 3 and 4).

Traditionally, if required, external fixation has been the default method of skeletal stabilization due to concerns about residual infection establishing on any internal fixation that might be used. More recently,

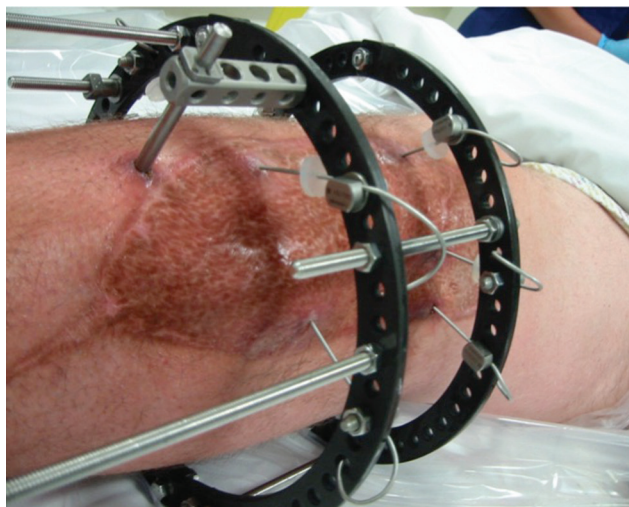


Fig. 3 Placement of wires through mature free flap in situ. Factors to consider when passing wires include the position of the flap's pedicle and how the wires will move during distraction.

there have been some early encouraging results with the combination of internal fixation with local antibiotics. Appropriate case selection is important and this approach should only be considered in selected cases where there is good bone stock, good soft tissues, no multiresistant organisms, a small bone gap (< 2 cm), and a healthy patient (CM type A host).³⁴ This is uncommon in our experience and only 3 to 4% of our infected nonunions are stabilized primarily with internal fixation.

Dead Space Management

Cavitary voids left in the bone following excision must be managed to prevent hematoma or seroma collection, which may become infected from the small numbers of planktonic organisms inevitably present at the end of debridement. Therefore, obliteration of the dead space is essential.²⁴ This can be achieved by importing vascularized tissue as a flap, particularly following cortical OM excision. Muscle flaps have the advantage of being able to conform to complex three-dimensional defects. However, for cavitary defects, synthetic bone graft substitutes that elute antibiotics are beneficial. They serve as osteoconductive carriers that promote bone healing while the carrier dissolves gradually and releases very high concentrations of antibiotic into the local region.¹⁴ The levels achieved are many orders of magnitude higher than the concentrations achieved by parenteral antibiotics but without the risk of systemic toxicity.^{35–37}

Soft Tissue Reconstruction in OM

COM may be associated with extensive soft tissue fibrosis and one or more sinuses. Large fragments of necrotic bone, or sequestra, break off and migrate to the surface along sinus tracts to be discharged with pus, which then results in a temporary period of quiescence. A vicious cycle of reactivation, discharge with symptoms, partial resolution with incomplete wound healing, and relapse can continue for decades, leading to extensive and dense fibrosis of the soft tissue envelope. Rarely, a particularly aggressive subtype

of squamous carcinoma (Marjolin's ulcer) may develop as a consequence of chronic inflammation.³⁸

Following excision of OM, soft tissue reconstruction in the form of a flap may be required.^{39–41} Most of these cases can be predicted at initial assessment. In 925 cases of long bone OM treated in the Oxford Bone Infection Unit between 2006 and 2015, direct closure was possible in 76%, with local flaps required in 5% and free tissue transfer in 19% (usually around the tibia) (*unpublished data*).

Local fibrosis, scarring, and previous soft tissue loss prevents direct closure. Sometimes the tight, edematous and brawny tissues may even prevent a simple surgical access incision from closing directly. The plastic surgeon should have a low threshold for soft tissue augmentation. The advent of microsurgical free tissue transfer of both bony and soft tissue components has allowed the possibility of functional limb salvage for lower limb OM where there are often large defects and limited local flap options (→ Fig. 5).

High-quality, vascularized soft tissue coverage with rapid healing provides a physical and microbiological barrier between the bone and the external microbiome including nosocomial microorganisms. This prevents a new infection establishing in exposed bone. The soft tissue flap plays several other roles, including delivery of host immunity and antibiotics, and it may also obturate dead space. It can also provide soft-tissue padding over bony prominences to protect the underlying bone from trauma or pressure ulceration in the longer term. Moreover, *ex vivo* and preclinical data have demonstrated that flaps provide a biological milieu (including cytokines and growth factors) conducive to bone regeneration.⁴²

Single-Stage versus Multiple Stages

Single-stage bone excision and soft tissue reconstruction should be undertaken whenever possible as early coverage is associated with earlier union, reduced infection, and shortened hospitalization.⁴³ By contrast, delay encourages colonization with microorganisms, biofilm development, recurrence of OM, and development of drug resistance.⁴⁴

In recent times, negative pressure wound therapy (NPWT) has gained popularity as an adjunct to temporize a wound and allow repeated debridement and staged closure. A major perceived advantage is that soft tissue coverage can be delayed until the wound is no longer infected. However, the evidence suggests that delay with NPWT risks superinfection⁴⁵ and skin flora microorganisms can migrate into the wound and adhere to internal fixation material, leading to nonunion or recurrent infection.⁴⁶ Furthermore, this approach leads to multiple unnecessary operations and cost. Our experience of 76 single-stage reconstruction for lower limb OM with a flap survival rate of 96% and 1-year infection-free rate of 90% demonstrates that single-stage reconstruction can reliably eradicate infection in most patients.⁴⁷ The four cases that experienced flap failure were successfully reconstructed with a subsequent flap.

The most robust studies on NPWT have been conducted in the acute trauma setting. In the analysis of the FLOW (fluid lavage of open wounds) trial, NPWT was associated with a significantly increased rate of infection in all types of open fracture wounds.⁴⁸ The recent




Fig. 4 Simultaneous flap and frame case with bone transport for infected nonunion. (A) Free gracilis muscle flap. Access can be improved for the plastic surgeon by temporarily removing the anteromedial transport rod until after surgery. Radiographs demonstrating (B) proximal corticotomy, (C) bone transport, (D) docking and further proximal distraction, (E) consolidation of regenerate, and (F) completion after frame removal.

WOLFF (wound management of open lower limb fractures) multicenter randomized clinical trial of 460 patients comparing standard care wound management versus NPWT after debridement in adult patients with an open fracture of the lower limb demonstrated no benefit of NPWT.⁴⁹ Furthermore, the latest Cochrane systematic review found that, based on 7 randomized controlled trials, there is moderate-certainty evidence for no clear difference between NPWT and standard care on wound healing.⁵⁰ Based on a separate comprehensive systematic review, the UK

National Institute for Health and Care Excellence guidance recommends soft tissue coverage within 72 hours of open fracture.⁵¹

A theoretical advantage of NPWT is the time-dependent reduction in the wound surface area and hence reconstructive demand. However, there is a lack of high-quality, long-term data to support this thesis. In our experience, soft tissue cover that results from healing by secondary intention in the context of OM is likely to be unstable and poorly vascularized scar tissue that is prone to recurrent soft tissue infections

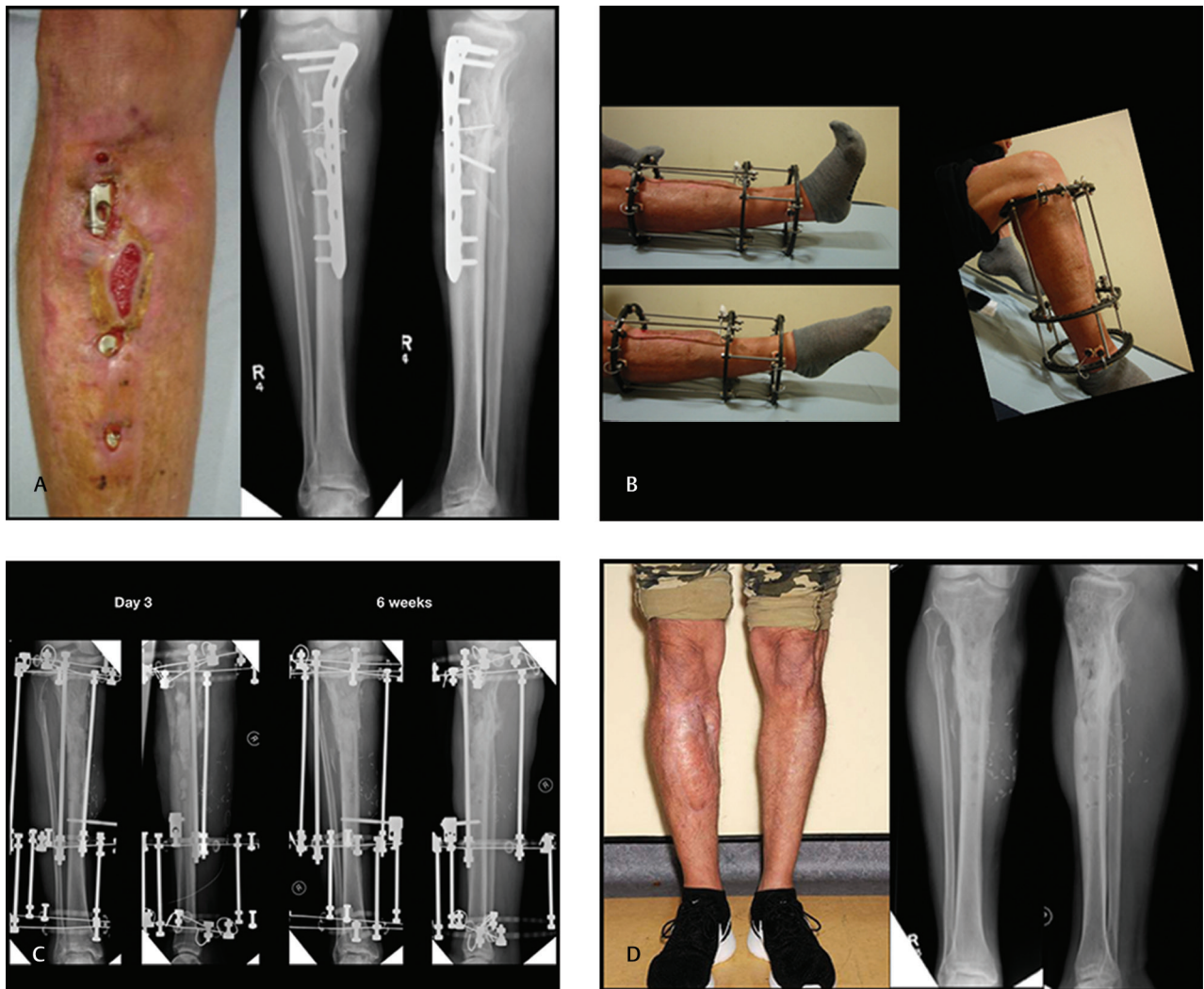


Fig. 5 Case example with infected nonunion. (A) Four months following fixation of an open comminuted fracture of the proximal tibia, the patient presented with wound breakdown and exposed metalwork. This was a CMIII contiguous focus osteomyelitis. The wound was excised including a significant amount of devitalized bone and the metalwork removed. Microbiology and histology samples were collected and antibiotics commenced. (B) Free distally based hemilatissimus dorsi muscle flap with an Ilizarov frame in situ to obliterate the dead space, provide soft tissue cover, and stabilize the fracture. A local antibiotic-eluting synthetic bone graft substitute was also used. Antibiotics were continued postoperatively. (C) Plain radiographs of the Ilizarov frame in situ. (D) One year post-operation. The frame had been removed at 4 months as the fracture had united. The patient had returned to work as a stone mason at 6 months. No secondary procedures were required.

and breakdown. Furthermore, large soft tissue flaps such as the anterolateral thigh (ALT) or latissimus dorsi can cover the vast majority of osteomyelitic defects.

In many units, a single stage “fix-and-flap” reconstruction is not possible logistically. The alternative is to “fix then flap.” However, there is little evidence to direct the timing between stages for the nonacute situation. We recommend that if done in two stages, the second stage must include a redebridement which is performed to the same standard as a single stage procedure before definitive coverage, and hence should be approached as if it were a single stage reconstruction.

Flap Choice

Pedicled versus Free

We advocate a low threshold for using free flaps in the lower limb. The availability of local tissues, particularly in the middle and distal thirds of a tibia, is limited and

locally compromised soft tissues are often inappropriate for locoregional transfer. Pedicled flaps in the lower extremity are associated with an unacceptably high partial or total failure rate, particularly in patients with multiple comorbidities such as diabetes mellitus, venous insufficiency, and peripheral arterial disease.⁵² A systematic review and pooled analysis of 907 patients who underwent a sural artery flap for mixed indications including trauma, ulcers, and open fractures reported a complication rate of 26.4% with a total flap loss rate of 3.2%.⁵³ A series of 60 open Gustilo IIIB tibial fractures reconstructed with islanded, distally-based fasciocutaneous flaps reported a 20% complication rate including five patients with complete flap loss and four patients with chronic OM and nonunion.⁵⁴ Perforator-based propeller flaps involve islanding the flaps to enable a greater arc of rotation and neater inset. However, these can also be problematic. A recent series of 21

propeller flaps in the upper and lower limbs found an overall complication rate of 33 and 14%, respectively, with partial flap necrosis of up to 50%.⁵⁵ In another retrospective series of 106 lower limb reconstructions using the islanded posterior tibial artery perforator flap, there was an 8.5% complete and 12% partial flap failure rate, both associated with cigarette smoking, diabetes, and peripheral vascular disease.⁵² Further surgery in the form of a free muscle transfer for limb salvage or a below-knee amputation was necessary for the failed flaps. The problem with partial flap or tip necrosis is that bone is exposed leading to reinfection and can therefore be considered the equivalent to total flap failure, thus requiring a new flap reconstruction. Finally, a systematic review and meta-analysis of 40 studies on perforator-pedicled propeller flaps in lower limb extremity defects reported a complication rate of 25.2% including a partial necrosis rate of 10.2% and complete necrosis rate of 3.5%.⁵⁶ While 55.2% of the 428 included cases were post-traumatic, neither a traumatic etiology nor acute cause was found to be a significant risk factor. However, age (over 60 years), diabetes, and arteriopathy were identified to be significant risk factors.

By contrast, reported free flap success rates are superior. May et al reported their 13-year experience of 97 microvascular free tissue transfers in 96 patients with chronic traumatic bone wounds.³⁹ Ninety percent of these were in the lower limb and 83% flaps were muscle-based. The overall free tissue transfer success rate was 97.9%. At a mean of follow-up of 13 years, 95.8% of patients had complete wound closure without drainage, 89.6% ambulatory without assistance, and 5.2% subsequently underwent amputation. In our series of 76 single-stage reconstruction in the lower limbs of 73 patients, flap survival rate was 96%.⁴⁷ Eleven of 76 cases required emergency return to operation theater for flap salvage and one patient required secondary amputation due to failure of reconstruction. Sabino et al reviewed 395 flap procedures in traumatic war-related extremity reconstruction, including pedicled and free options.⁵⁷ They reported flap failures of 14 and 8% in the pedicled muscle and fasciocutaneous groups, respectively, and 12 and 3% for the free muscle and fasciocutaneous groups, respectively. However, flap choice was not randomized and hence outcome from these groups are not directly comparable.

Muscle versus Fasciocutaneous

There are no randomized studies that have investigated the outcomes of muscle versus fasciocutaneous flaps in lower limb reconstruction. Various retrospective cohort studies have been performed and a review on this comparison in the context of lower limb trauma is already available.⁴² Two large series have been published since. Sofiadellis et al reported their experience of 105 free flap reconstructions in lower limb trauma.⁵⁸ There was a total flap failure rate of 6.3% in the muscle group and 0% in the fasciocutaneous group, and partial flap failure rate of 15.8 and 5.3%, respectively. Sabino et al reviewed 395 flap procedures in traumatic war-related extremity reconstruction.⁵⁷ There was no difference in overall flap complications. While there was a higher flap failure rate in the muscle group compared with the fasciocutaneous

group, when analyzed within the pedicled and free subgroups, no significant difference was found.

In the context of OM, Hong et al reported their experience of 120 patients who underwent fasciocutaneous free flaps, including ALT, superior circumflex artery perforator, gluteal artery perforator, upper medial thigh perforator, and thoracodorsal artery perforator flaps, for chronic OM.² However, this series may be biased as the authors describe using a segment of vastus lateralis with their ALT flaps for dead space management. They reported a flap loss rate of 4.2%, primary remission rate of 91.6%, secondary remission rate of 98.3%, and an amputation rate of 1%. The May series featured 91 muscle flaps (latissimus dorsi and gracilis) out of a total of 97 free tissue transfers for lower limb reconstruction for chronic traumatic lower limb wounds.³⁹ There was a flap success rate of 97.8% in the muscle group; 95.8% of patients had complete wound closure without drainage at 13 years. Paro et al analyzed their experience of free tissue reconstruction in the lower limb for a variety of indications including infection and found no significant difference in major or minor complication rates between the muscle and fasciocutaneous groups.⁵⁹ They also found that patients who underwent fasciocutaneous reconstruction were more likely to require revision surgery for aesthetics.

A recent retrospective review that included patients with acute traumatic injuries ($n = 238$) as well as chronic traumatic sequelae ($n = 280$) compared muscle versus fasciocutaneous free flaps.⁶⁰ The authors found similar rates of limb salvage and functional recovery in both the acute and chronic subgroups with no significant differences in functional recovery or complication rate. However, in patients with grade IIIB injuries and/or exposed defect hardware, fasciocutaneous flaps were more likely to be re-elevated for orthopaedic procedures, including staged primary bone grafting, hardware manipulation, and bone grafting for nonunion. This was the case in both the acute and chronic subgroups. The design of this study unfortunately precludes analysis to determine whether this difference is due to the biological effect of flap type or other confounders such as patient selection. In our series of 76 osteomyelitic limbs, 91% were muscle based (gracilis or latissimus dorsi).⁴⁷

Postoperative functional and aesthetic concerns, particularly with regard to shoe-fitting, should be part of the algorithm for extremity limb salvage. Revision procedures for fasciocutaneous flaps are well documented. Fasciocutaneous flaps have been found to be particularly problematic with contour and bulk.⁶¹⁻⁶³ Kotsougiani et al reviewed their series of 389 patients with free flap reconstruction in the lower limb (142 muscle and 193 fasciocutaneous free flaps).⁶⁴ They reported 13.9% requiring one to three secondary refinement procedures, the majority being surgical debulking, and found that the flap type did not predict secondary refinement procedures. Nelson et al reported 21.1% of their 152 patients underwent secondary aesthetic revisions again with debulking being the most common procedure.⁶⁵ However, they did not compare fasciocutaneous versus muscle groups. In our experience, free muscle flaps with an unmeshed skin graft provide durable coverage and muscle atrophy leads

to acceptable contouring if inset well at initial operation. In our experience, compression bandaging until there is no pitting edema of the muscle flap effectively reduces edema and improves contour but there is currently no published evidence to support this.

Microsurgery

In our unit, we have a low threshold for using free flaps for OM reconstruction. Overall, ~23% of our unit's cOM cases require plastic surgery reconstruction and around 75% of these involve free tissue transfer (almost all in the tibia). Free flaps are versatile and can cover defects of any size and in any location. Often, these patients have a soft tissue envelope that has become scared from the initial trauma, early and late orthopaedic reconstructions, and ongoing infection. These three stages can lead to extensive soft tissue fibrosis reducing the effectiveness of local flaps. The introduction of new tissue allows greater flexibility for resurfacing and also has the effect of taking the tension from local tissues potentially improving venous drainage and tissue quality. We also have a preference for muscle flaps except for very thin patients largely due to their effectiveness at obliterating dead space, provision of durable cover, and superior contouring. In our hands and patient population, muscle flaps require less revisional surgery including thinning than fasciocutaneous flaps. This is often neglected in operative planning but in a group of patients who have had many operations already, the prospect of multiple contouring procedures has significant implications and costs. We find that free tissue transfer is a reliable method of importing healthy vascularized soft tissue that reduces scarring on the leg with a high success rate and minimal donor site morbidity.

Technical Considerations

Vessel Preparation and Anastomosis

Although our surgical principles are based on the management of acute open fractures, it is important to emphasize that infected cases have very different technical challenges compared with acute trauma. In particular, the preparation of the recipient vessels is a major challenge as this requires dissection through chronically inflamed and fibrotic tissues. Finding the vessels is often difficult as anatomical planes may be disrupted by the previous trauma or surgery. The "zone of inflammation" may extend a long way up the limb in the neurovascular plane and so anastomosis is often performed in the scarred area. Arterial spasm is common during dissection but normally resolves with topical antispasmodics (e.g., 2% lignocaine). The posterior tibial vessels are least likely to have been injured during the initial trauma and are the most reliable recipient vessels in the lower limb.^{66,67}

With regard to vessel anastomosis, in our experience, 53% of arterial anastomoses were end-to-side and 47% end-to-end. Sixteen percent required one or more revisions.⁴⁷ The venous anastomosis was hand sutured in 84% of cases and a coupler was used in 12.5%. Seven percent required revision. With

regard to the choice of recipient vein, 98% were deep. In 75% cases, one vein was used and in 25%, two veins were used. Two retrospective reviews, each with over 300 free tissue reconstructions for the lower limb, found that anastomosis of one rather than two veins did not affect the rate of flap survival.^{68,69} Occasionally a vein graft is necessary. The mean ischemic time was 83.6 (40–210) minutes and total operating time was 7.76 (5–16) hours. About 14.5% required emergency return to theater for flap salvage or further reconstruction and 1 of 76 patients required a secondary amputation for complications unrelated to the successfully treated OM.

Inset of Flap

Tension-free closure with muscle tucked under the edges of the skin defect is critical to ensure a good seal. Usually one suction drain is placed under the flap away from the anastomosis to prevent fluid collection and to encourage adherence of the flap to the exposed bone surface. The muscle is then resurfaced with an unmeshed split thickness skin graft.

Flap Monitoring

We find venous Doppler monitoring systems as an easy and reliable method of flap monitoring as has been demonstrated in head and neck⁷⁰ and breast free flaps,⁷¹ with a sensitivity of 100% but high false positive rates of up to 13.6%. Most units will have their preferred methods of monitoring depending on local experience.

Irrespective of the reconstructive technique, if there is partial or total flap necrosis, we suggest early debridement of bone and immediate reconstruction with a second flap rather than prevaricating and hoping the wound will heal by secondary intention without reinfection of the bone.

Future Perspectives

Biofilm-related OM affecting the limbs presents a considerable reconstructive challenge. Encouragingly, with a multidisciplinary approach and microsurgical techniques, reliable long-term eradication rates of infection and limb salvage can now be expected.

A multidisciplinary approach and pragmatic individualized decision making based on best evidence are key to the successful treatment. To refine our management of these patients, it is imperative that well-designed trials are undertaken to provide a robust evidence base. While it is encouraging that the microbiological aspects of management of OM are being investigated, including the OVIVA and AVAPOM trials,^{16,17} there remains a dearth of evidence for the surgical aspects of therapy. The development of a classification system⁷² of OM that is more effective at guiding clinical management and OM-specific patient-reported outcome measures⁷³ together with the pragmatic design of trials to investigate the timing, staging and type of soft tissue reconstruction are urgently needed to enable clinicians to make better informed decisions and improve the care of these patients.

Conflict of Interest

Dr. Ferguson and Dr. McNally report personal fees from Bonesupport AB. Dr. McNally reports payment for lectures including service on speakers bureaus from AO foundation, Bonesupport AB, and Heraeus Medical.

References

- Huang CC, Tsai KT, Weng SF, et al. Chronic osteomyelitis increases long-term mortality risk in the elderly: a nationwide population-based cohort study. *BMC Geriatr* 2016;16:72
- Olesen UK, Pedersen NJ, Eckardt H, et al. The cost of infection in severe open tibial fractures treated with a free flap. *Int Orthop* 2017;41(5):1049–1055
- Shirley R, Fazekas J, McNally M, Ramsden A. Costs and remuneration of osteomyelitis treatment involving free flaps: implications of return to theatre. *J Bone Jt Infect* 2018;3(1):15–19
- Hackett DJ, Rothenberg AC, Chen AF, et al. The economic significance of orthopaedic infections. *J Am Acad Orthop Surg* 2015;23(Suppl):S1–S7
- Kremers HM, Nwojo ME, Ransom JE, Wood-Wentz CM, Melton LJ III, Huddlestone PM III. Trends in the epidemiology of osteomyelitis: a population-based study, 1969 to 2009. *J Bone Joint Surg Am* 2015;97(10):837–845
- Lew DP, Waldvogel FA. Osteomyelitis. *Lancet* 2004;364(9431):369–379
- McNally M, Nagarajah K. Osteomyelitis. *Orthop Trauma* 2010;24(6):416–429
- Barker JC, Khansa I, Gordillo GM. A formidable foe is sabotaging your results: what you should know about biofilms and wound healing. *Plast Reconstr Surg* 2017;139(5):1184e–1194e
- Libraty DH, Patkar C, Torres B. Staphylococcus aureus reactivation osteomyelitis after 75 years. *N Engl J Med* 2012;366(5):481–482
- Sendi P, Meier R, Sonderegger B, Bonel HM, Schäfer SC, Vögelin E. Reactivated Moraxella osteitis presenting as granulomatous disease. *Neth J Med* 2014;72(9):491–493
- Ziran BH, Rao N, Hall RA. A dedicated team approach enhances outcomes of osteomyelitis treatment. *Clin Orthop Relat Res* 2003;414:31–36
- Sheehy SH, Atkins BA, Bejon P, et al. The microbiology of chronic osteomyelitis: prevalence of resistance to common empirical anti-microbial regimens. *J Infect* 2010;60(5):338–343
- Street TL, Sanderson ND, Atkins BL, et al. Molecular diagnosis of orthopedic-device-related infection directly from sonication fluid by metagenomic sequencing. *J Clin Microbiol* 2017;55(8):2334–2347
- Ferguson J, Diefenbeck M, McNally M. Ceramic biocomposites as biodegradable antibiotic carriers in the treatment of bone infections. *J Bone Jt Infect* 2017;2(1):38–51
- Waldvogel FA, Medoff G, Swartz MN. Osteomyelitis: a review of clinical features, therapeutic considerations and unusual aspects. *N Engl J Med* 1970;282(4):198–206
- Senneville E, Coelho A, Eds. AVAPOM: Complete Oral Versus Intravenous Antibiotic Documented Treatment in Prosthetic Joint Infections. *Orthopaedic Proceedings*; 2017; Nantes, France: Orthopaedic Proceedings; 2018
- Li HK, Rombach I, Zambellas R, et al; OVIVA Trial Collaborators. Oral versus intravenous antibiotics for bone and joint infection. *N Engl J Med* 2019;380(5):425–436
- Bernard L, Dinh A, Ghout I, et al; Duration of Treatment for Spondylodiscitis (DTS) study group. Antibiotic treatment for 6 weeks versus 12 weeks in patients with pyogenic vertebral osteomyelitis: an open-label, non-inferiority, randomised, controlled trial. *Lancet* 2015;385(9971):875–882
- Lora-Tamayo J, Euba G, Cobo J, et al; Prosthetic Joint Infection Group of the Spanish Network for Research in Infectious Diseases—REIPI. Short- versus long-duration levofloxacin plus rifampicin for acute staphylococcal prosthetic joint infection managed with implant retention: a randomised clinical trial. *Int J Antimicrob Agents* 2016;48(3):310–316
- Hogan A, Heppert VG, Suda AJ. Osteomyelitis. *Arch Orthop Trauma Surg* 2013;133(9):1183–1196
- Høiby N, Bjarnsholt T, Moser C, et al; ESCMID Study Group for Biofilms and Consulting External Expert Werner Zimmerli. ESCMID guideline for the diagnosis and treatment of biofilm infections 2014. *Clin Microbiol Infect* 2015;21(Suppl 1):S1–S25
- Govaert GA, Ijpmma FF, McNally M, McNally E, Reininga IH, Claudemans AW. Accuracy of diagnostic imaging modalities for peripheral post-traumatic osteomyelitis - a systematic review of the recent literature. *Eur J Nucl Med Mol Imaging* 2017;44(8):1393–1407
- Hong JJP, Goh TLH, Choi DH, Kim JJ, Suh HS. The efficacy of perforator flaps in the treatment of chronic osteomyelitis. *Plast Reconstr Surg* 2017;140(1):179–188
- Cierny G III, Mader JT, Penninck JJ. A clinical staging system for adult osteomyelitis. *Clin Orthop Relat Res* 2003;414:7–24
- Kettner SC, Willschke H, Marhofer P. Does regional anaesthesia really improve outcome? *Br J Anaesth* 2011;107(Suppl 1):i90–i95
- Hahn HM, Jeong YS, Hong YS, et al. Use of revascularized artery as a recipient in microvascular reconstruction of the lower leg: an analysis of 62 consecutive free flap transfers. *J Plast Reconstr Aesthet Surg* 2017;70(5):606–617
- Mills E, Eyawo O, Lockhart I, Kelly S, Wu P, Ebbert JO. Smoking cessation reduces postoperative complications: a systematic review and meta-analysis. *Am J Med*. 2011;124(2):144–54 e8
- Bode LG, Kluytmans JA, Wertheim HF, et al. Preventing surgical-site infections in nasal carriers of Staphylococcus aureus. *N Engl J Med* 2010;362(1):9–17
- Atkins BL, Athanasou N, Deeks JJ, et al; The OSIRIS Collaborative Study Group. Prospective evaluation of criteria for microbiological diagnosis of prosthetic-joint infection at revision arthroplasty. *J Clin Microbiol* 1998;36(10):2932–2939
- McNally M. Infection after fracture. In: Kates SL, Borens O, eds. *Principles of Orthopaedic Infection Management*. 1st ed. AO Trauma. Stuttgart, Germany: Thieme; 2017:139–165
- Morgenstern M, Athanasou NA, Ferguson JY, Metsemakers WJ, Atkins BL, McNally MA. The value of quantitative histology in the diagnosis of fracture-related infection. *Bone Joint J* 2018;100-B(7):966–972
- McNally M, Ferguson J, Kugan R, Stubbs D. Ilizarov treatment protocols in the management of infected nonunion of the tibia. *J Orthop Trauma* 2017;31(Suppl 5):S47–S54
- Mifsud M, Ferguson J, Stubbs D, Ramsden A, McNally M, Eds. Outcomes of Simultaneous Ilizarov Frame Reconstruction and Free Muscle Flaps in the Management of Complex Limb Infection. *British Limb Reconstruction Society (BLRS) Annual Conference*; 2018; Southampton, UK: Orthopaedic Proceedings; 2018
- McNally M, Ferguson J, Mifsud M, Stubbs D, Eds. Internal Fixation and Local Antibiotics for Infected Nonunions: Technique and Outcome at over one year. *British Limb Reconstruction Society (BLRS) Annual Conference*; 2018; Southampton, UK: Orthopaedic Proceedings; 2018
- Mayberry-Carson KJ, Tober-Meyer B, Smith JK, Lambe DW Jr, Costerton JW. Bacterial adherence and glycocalyx formation in osteomyelitis experimentally induced with Staphylococcus aureus. *Infect Immun* 1984;43(3):825–833
- Stravinskis M, Horstmann P, Ferguson J, et al. Pharmacokinetics of gentamicin eluted from a regenerating bone graft substitute: in vitro and clinical release studies. *Bone Joint Res* 2016;5(9):427–435

- 37 Walenkamp GH, Vree TB, van Rens TJ. Gentamicin-PMMA beads. Pharmacokinetic and nephrotoxicological study. *Clin Orthop Relat Res* 1986;(205):171–183
- 38 McGrory JE, Pritchard DJ, Unni KK, Ilstrup D, Rowland CM. Malignant lesions arising in chronic osteomyelitis. *Clin Orthop Relat Res* 1999;(362):181–189
- 39 May JW Jr, Jupiter JB, Gallico GG III, Rothkopf DM, Zingarelli P. Treatment of chronic traumatic bone wounds. Microvascular free tissue transfer: a 13-year experience in 96 patients. *Ann Surg* 1991;214(3):241–250, discussion 250–252
- 40 McNally MA, Small JO, Tofighi HG, Mollan RA. Two-stage management of chronic osteomyelitis of the long bones. The Belfast technique. *J Bone Joint Surg Br* 1993;75(3):375–380
- 41 McNally MA, Ferguson JY, Lau AC, et al. Single-stage treatment of chronic osteomyelitis with a new absorbable, gentamicin-loaded, calcium sulphate/hydroxyapatite biocomposite: a prospective series of 100 cases. *Bone Joint J* 2016;98-B(9):1289–1296
- 42 Chan JK, Harry L, Williams G, Nanchahal J. Soft-tissue reconstruction of open fractures of the lower limb: muscle versus fasciocutaneous flaps. *Plast Reconstr Surg* 2012;130(2):284e–295e
- 43 Cierny G III, Byrd HS, Jones RE. Primary versus delayed soft tissue coverage for severe open tibial fractures. A comparison of results. *Clin Orthop Relat Res* 1983;(178):54–63
- 44 Mouës CM, Vos MC, van den Bemd GJ, Stijnen T, Hovius SE. Bacterial load in relation to vacuum-assisted closure wound therapy: a prospective randomized trial. *Wound Repair Regen* 2004;12(1):11–17
- 45 Olesen UK, Juul R, Bonde CT, et al. A review of forty five open tibial fractures covered with free flaps. Analysis of complications, microbiology and prognostic factors. *Int Orthop* 2015;39(6):1159–1166
- 46 Diefenbeck M, Mennenga U, Gückel P, Tiemann AH, Mückley T, Hofmann GO. [Vacuum-assisted closure therapy for the treatment of acute postoperative osteomyelitis]. *Z Orthop Unfall* 2011;149(3):336–341
- 47 Chan JK, Miller R, Ramsden A. Microvascular reconstruction in the management of chronic osteomyelitis of the lower limb. 9th Congress of World Society for Reconstructive Microsurgery; Seoul, Korea; 2017
- 48 Sendi P, McNally MA. Wound irrigation in initial management of open fractures. *N Engl J Med* 2016;374(18):1788
- 49 Costa ML, Achten J, Bruce J, et al; UK WOLFF Collaboration. Effect of negative pressure wound therapy vs standard wound management on 12-month disability among adults with severe open fracture of the lower limb: the WOLFF randomized clinical trial. *JAMA* 2018;319(22):2280–2288
- 50 Iheozor-Ejiofor Z, Newton K, Dumville JC, Costa ML, Norman G, Bruce J. Negative pressure wound therapy for open traumatic wounds. *Cochrane Database Syst Rev* 2018;7:CD012522
- 51 NICE. NICE Guidance: Fractures (complex) 2016 [Available from: <https://www.nice.org.uk/guidance/ng37/evidence>
- 52 Schaverien MV, Hamilton SA, Fairburn N, Rao P, Quaba AA. Lower limb reconstruction using the islanded posterior tibial artery perforator flap. *Plast Reconstr Surg* 2010;125(6):1735–1743
- 53 de Blacam C, Colakoglu S, Ogunleye AA, et al. Risk factors associated with complications in lower-extremity reconstruction with the distally based sural flap: a systematic review and pooled analysis. *J Plast Reconstr Aesthet Surg* 2014;67(5):607–616
- 54 Erdmann MW, Court-Brown CM, Quaba AA. A five year review of islanded distally based fasciocutaneous flaps on the lower limb. *Br J Plast Surg* 1997;50(6):421–427
- 55 Artiaco S, Battiston B, Colzani G, et al. Perforator based propeller flaps in limb reconstructive surgery: clinical application and literature review. *BioMed Res Int* 2014;2014:690649
- 56 Bekara F, Herlin C, Mojallal A, et al. A systematic review and meta-analysis of perforator-pedicled propeller flaps in lower extremity defects: identification of risk factors for complications. *Plast Reconstr Surg* 2016;137(1):314–331
- 57 Sabino J, Polfer E, Tintle S, et al. A decade of conflict: flap coverage options and outcomes in traumatic war-related extremity reconstruction. *Plast Reconstr Surg* 2015;135(3):895–902
- 58 Sofiadellis F, Liu DS, Webb A, Macgill K, Rozen WM, Ashton MW. Fasciocutaneous free flaps are more reliable than muscle free flaps in lower limb trauma reconstruction: experience in a single trauma center. *J Reconstr Microsurg* 2012;28(5):333–340
- 59 Paro J, Chiou G, Sen SK. Comparing muscle and fasciocutaneous free flaps in lower extremity reconstruction--does it matter? *Ann Plast Surg* 2016;76(Suppl 3):S213–S215
- 60 Cho EH, Shamma RL, Carney MJ, et al. Muscle versus fasciocutaneous free flaps in lower extremity traumatic reconstruction: a multicenter outcomes analysis. *Plast Reconstr Surg* 2018;141(1):191–199
- 61 Askouni EP, Topping A, Ball S, Hettiaratchy S, Nanchahal J, Jain A. Outcomes of anterolateral thigh free flap thinning using liposuction following lower limb trauma. *J Plast Reconstr Aesthet Surg* 2012;65(4):474–481
- 62 Hui-Chou HG, Sulek J, Bluebond-Langner R, Rodriguez ED. Secondary refinements of free perforator flaps for lower extremity reconstruction. *Plast Reconstr Surg* 2011;127(1):248–257
- 63 Ooi A, Wong CH, Ong YS. Combined use of liposuction and arthroscopic shaver in lower-limb fasciocutaneous flap contouring. *J Plast Reconstr Aesthet Surg* 2013;66(4):538–542
- 64 Kotsougiani D, Platte J, Bigdeli AK, et al. Evaluation of 389 patients following free-flap lower extremity reconstruction with respect to secondary refinement procedures. *Microsurgery* 2018;38(3):242–250
- 65 Nelson JA, Fischer JP, Haddock NT, et al. Striving for normalcy after lower extremity reconstruction with free tissue: the role of secondary esthetic refinements. *J Reconstr Microsurg* 2016;32(2):101–108
- 66 Chen HC, Chuang CC, Chen S, Hsu WM, Wei FC. Selection of recipient vessels for free flaps to the distal leg and foot following trauma. *Microsurgery* 1994;15(5):358–363
- 67 Haddock NT, Weichman KE, Reformat DD, Kligman BE, Levine JP, Saadeh PB. Lower extremity arterial injury patterns and reconstructive outcomes in patients with severe lower extremity trauma: a 26-year review. *J Am Coll Surg* 2010;210(1):66–72
- 68 Heidekrueger PI, Ehrl D, Heine-Geldern A, Ninkovic M, Broer PN. One versus two venous anastomoses in microvascular lower extremity reconstruction using gracilis muscle or anterolateral thigh flaps. *Injury* 2016;47(12):2828–2832
- 69 Lorenzo AR, Lin CH, Lin CH, et al. Selection of the recipient vein in microvascular flap reconstruction of the lower extremity: analysis of 362 free-tissue transfers. *J Plast Reconstr Aesthet Surg* 2011;64(5):649–655
- 70 Fujiwara RJT, Dibble JM, Larson SV, Pierce ML, Mehra S. Outcomes and reliability of the flow coupler in postoperative monitoring of head and neck free flaps. *Laryngoscope* 2018;128(4):812–817
- 71 Kempton SJ, Poore SO, Chen JT, Afifi AM. Free flap monitoring using an implantable anastomotic venous flow coupler: analysis of 119 consecutive abdominal-based free flaps for breast reconstruction. *Microsurgery* 2015;35(5):337–344
- 72 Hotchen AJ, McNally MA, Sendi P. The classification of long bone osteomyelitis: a systemic review of the literature. *J Bone Jt Infect* 2017;2(4):167–174
- 73 Egeler SA, de Jong T, Luijsterburg AJM, Mureau MAM. Long-term patient-reported outcomes following free flap lower extremity reconstruction for traumatic injuries. *Plast Reconstr Surg* 2018;141(3):773–783