



# Aortic Arch Thrombosis Associated with Fetal Cytomegalovirus Viremia

Elif Gul Yapar Eyi<sup>1</sup> Nahide Altuğ<sup>2</sup>

<sup>1</sup>Perinatology Subdivision, Zekai Tahir Burak Women's Health Education and Research Hospital, Ankara, Turkey

<sup>2</sup>Pediatric Cardiology, Zekai Tahir Burak Women's Health Education and Research Hospital, Ankara, Turkey

Address for correspondence Elif Gul Yapar Eyi, Perinatology Subdivision, Zekai Tahir Burak, Women's Health Education and Research Hospital, Talatpasa Boulevard, Ankara 06230, Turkey (e-mail: elifgulyapar@gmail.com).

Am J Perinatol Rep 2018;9:e23–e26.

## Abstract

Cytomegalovirus(CMV) associated thrombosis has been reported sporadically in the medical literature; however, its antenatal scenario has not been documented. We herein present the antenatal, Doppler's ultrasound and magnetic resonance angiographic features of thrombosis in the aortic arch showing extension toward the medial lumen of the brachiocephalic trunk with critical occlusion of the left common carotid artery and left subclavian artery in a term fetus to raise obstetricians'/ neonatologists'/ pediatric cardiologists' awareness for the association between CMV viremia and intrauterine thrombosis that caused cerebral injury, neurodevelopmental impairment, and permanent sequela.

## Keywords

- ▶ thrombosis
- ▶ cytomegalovirus
- ▶ aortic arcus
- ▶ viremia
- ▶ fetus

The detection of a fast heart rate greater than 180 beats per minute (bpm) in a term fetus should be considered as a medical emergency because it carries a significant risk of hemodynamic compromise, heart failure, morbidity, and even mortality. Identifying the etiology together with its hemodynamic impact is important because both the management and prognosis differ among the various disorders. We herein present the clinical and laboratory findings of thrombosis in the aortic arch in a term fetus presenting with tachycardia in whom congenital cytomegalovirus(CMV) infection was detected in the early neonatal period.

## Case

A 38-year-old primigravid woman at 38<sup>6/7</sup> weeks of gestation was hospitalized as detection of a fetal heart rate exceeding 200 bpm on antepartum cardiotocograph. Four chamber view and the outflow tracts appeared normal. Echocardiography revealed severe tricuspid regurgitation (3.2 cm/sec) and poor myocardial contraction. Maternal past medical history revealed Raynaud's phenomenon. Familial and antenatal follow-up was uneventful. There was no exposure to any drug or medication during pregnancy. She was taken to emergent cesarean section. A female infant weighing 3,720 g/52 cm (head circumference: 37 cm) with 7 and 9

Apgar's scores at 1 and 5 minutes were delivered. Cyanosis unresponsive to oxygen therapy was present. Radiological, hematological, and biochemical parameters were shown in ▶Table 1 and ▶Table 2. Echocardiography depicted the dilatation of the heart. There was an echogenic mass measuring 10 × 5 mm in the aortic arch restricting the antegrade flow to the descending aorta. Thrombogenic mass was also detected in the left interatrial septum. Systolic functions decreased (▶Videos 1 and 2). Magnetic resonance imaging (MRI) angiography depicted that thrombosis in the aortic arch was showing extension toward the medial lumen of the brachiocephalic trunk with critical occlusion of the left common carotid artery and left subclavian artery (▶Fig. 1A–E). Because of the potential organ and life-threatening location of the thrombus, recombinant human tissue type plasminogen activator (t-PA: 0.2 mg/kg/hour) for 6 hours, prostaglandin E1 (0.1 mg/kg/minute), and inotropic agent (Dopamine 5 mg/kg/minute) were infused. Over the subsequent 24 hours, echocardiography showed resolution of the thrombus. The t-PA and prostaglandin were discontinued. Intracranial hemorrhage was reported on the cranial ultrasonography. Convulsions started. Anticonvulsant agents were administered. Anticoagulant therapy with enoxaparin: 2 × 3.62 mg was initiated on the fourth day. Hereditary and acquired thrombophilia tests revealed no pathology.

received  
September 6, 2018  
accepted  
September 11, 2018

DOI <https://doi.org/10.1055/s-0038-1675631>.  
ISSN 2157-6998.

Copyright © 2019 by Thieme Medical Publishers, Inc., 333 Seventh Avenue, New York, NY 10001, USA.  
Tel: +1(212) 584-4662.

License terms



**Table 1** Symptoms and radiological findings

Symptoms	Immediately after birth	24–48 hour after birth	Following days
Echocardiography (► Videos 1 and 2)	Tachycardia, dyspnea, hyperventilation Cyanosis, reduced brachial pulse, reduced femoral pulse <ul style="list-style-type: none"> <li>• 10.0 × 3.5 mm thrombus in the aortic arch</li> <li>• Thrombus in the atrial septum</li> <li>• Mitral regurgitation: 3.5 m/s</li> <li>• Tricuspid regurgitation: 3.2 m/s</li> <li>• Ejection fraction 56%</li> <li>• Left ventricular fractional shortening 27%</li> </ul>	Convulsions/intubated No thrombus in the aortic arch Decrease in the dimension of the thrombosis in the atrial septum	Extubated on day 11
Cranial ultrasound	<ul style="list-style-type: none"> <li>• Atrial width: 11 mm bilateral encephalomalacia near the right lateral ventricle measuring 8 × 4 mm and near the left lateral ventricle measuring 5 × 7 mm</li> </ul>		Bilateral encephalomalacia near the right lateral ventricle measuring 18 × 20 mm, near the left lateral ventricle measuring 15 × 7 mm
Cranial computed tomography	<ul style="list-style-type: none"> <li>• Left frontoparietal and right parietal subarachnoid hemorrhage</li> <li>• Intraparenchymal hemorrhage</li> <li>• Brain edema</li> <li>• The diminished contour of the hemispheric sulcus</li> </ul>		
Cranial magnetic resonance angiography (► Fig. 1A–E)	<ul style="list-style-type: none"> <li>• Thrombosis in the aortic arch extending toward the medial lumen of the brachiocephalic trunk with critical occlusion of the left common carotid artery and left subclavian artery</li> <li>• Loss of calibers in the right internal carotid artery</li> <li>• There is no apparent flow in the right thin anterior cerebral artery and midcerebral artery</li> <li>• Retrograde and collateral circulation, which is thought to be coming from external carotid artery</li> <li>• Swelling of the basal ganglia and leukomalacia</li> </ul>		

Heterozygote mutation in the MTHFR A1298C was detected in the newborn (► Table 2).

### Video 1

Axial view of the transverse aorta depicting the outflow tract of the brachiocephalic trunk, the left common carotid artery and the subclavian artery. Aortic coarctation pattern is seen with color Doppler. Online content including video sequences viewable at: [www.thieme-connect.com/products/ejournals/html/10.1055/s-0038-1675631](http://www.thieme-connect.com/products/ejournals/html/10.1055/s-0038-1675631).

### Video 2

One thrombosis in the aortic arch measuring 10.0 × 3.5 mm is present impairing the blood flow to critical levels. Online content including video sequences viewable at: [www.thieme-connect.com/products/ejournals/html/10.1055/s-0038-1675631](http://www.thieme-connect.com/products/ejournals/html/10.1055/s-0038-1675631).

1.77 × 10<sup>7</sup> copies/mL CMV DNA (deoxyribonucleic acid) was detected in serum samples of the neonate by polymerase chain reaction (PCR). Mother was CMV IgM (immunoglobulin M) seronegative. She was CMV IgG seropositive with high avidity. No virus was detected in breast milk (► Table 2). Baby received Ganciclovir infusion (18 mg twice daily) due to the acute viremia in the second week. Electroencephalography depicted severe abnormality. No sign of chorioretinitis was detected in the eye examination. She was discharged home on enoxaparin and anticonvulsant therapy on the 55th day after birth.

## Discussion

Arterial thrombosis is much less common than venous thrombosis.<sup>1</sup> The symptomatic neonatal arterial thromboembolic disease has been reported to be between 2.5 to 5.1/10,000 live births<sup>2,3</sup> and 2/79 (2.5%) of the cases were documented as aortic thrombosis.<sup>3</sup> Mortality has been quoted as high as 33% in infants with aortic thrombosis.<sup>3,4</sup> Among the several reports on the thrombosis of the aorta during the neonatal period,<sup>1–6</sup> aortic arch thrombosis associated with CMV infection has been reported twice<sup>5,6</sup> and antenatal findings have not been published previously.

Natural history of CMV infections during pregnancy is complex and not fully understood. A pregnant woman who is

**Table 2** Laboratory findings of the newborn and the mother

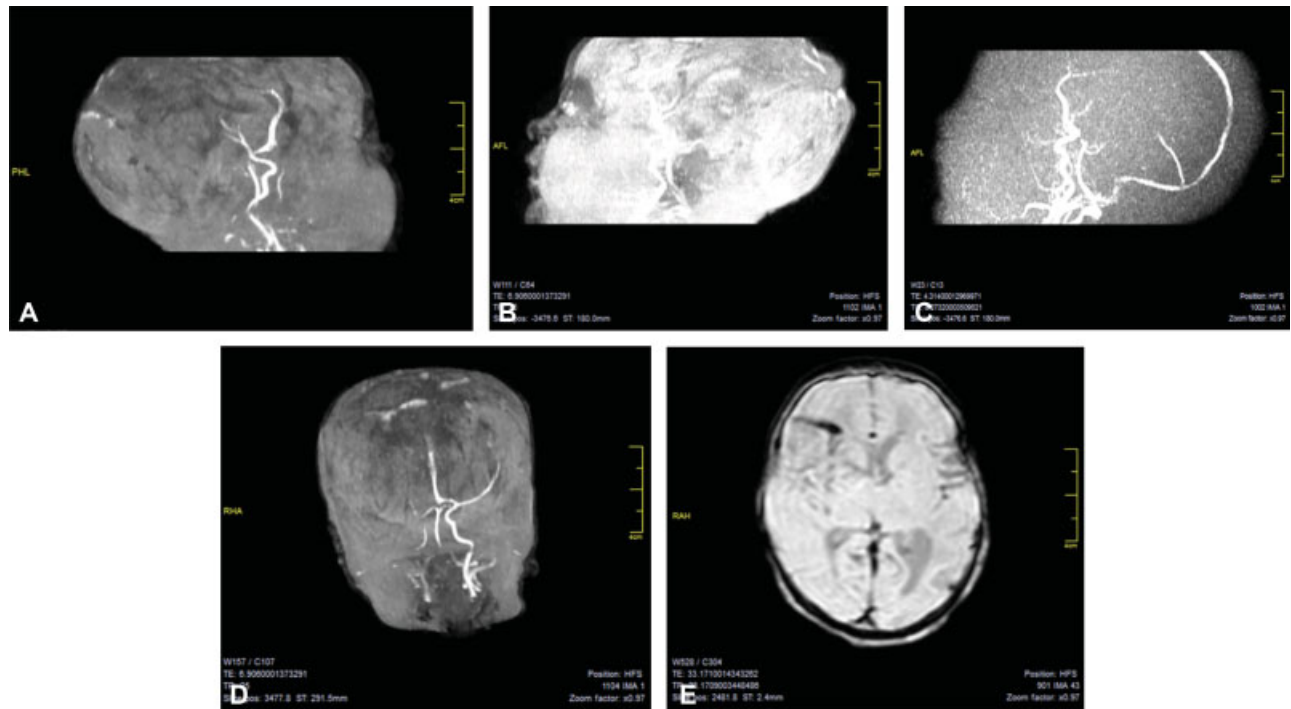
	Newborn	Mother
Blood count (at birth)	Hemoglobin: 16 g/dL Hematocrit: 52.1% WBC: 18,600/mm <sup>3</sup> Platelets: 143,000/mm <sup>3</sup>	
Coagulation profile (at birth)	PT: 15 s aPTT: 42 s INR: 1.44 Fibrinogen: 141 mg/dL	
Biochemical (at birth)	BUN: 13 mg/dL Creatinine: 0.34 mg/dL ALT: 33 mg/dL AST: 42 mg/dL Na: 141 mEq/dL K: 5.4 mEq/dL Ca: 1.07 mg/dL Lipoprotein a: 2.2 mg/dL	
Microbiological (first wk)	CMV IgM: 2.2 (Cut-off index $\geq 1.0$ )	Anti CMV IgG assay <sup>a</sup> (serum): 8.4 IU/mL (0–5) Anti CMV IgM assay (serum): 0.2 IU/mL (< 1) CMV IgG avidity: 0.0.83 high avidity (> 0.65)
	CMV PCR (serum): 1.77 $\times 10^7$ 8th d <sup>a</sup> 2.22 $\times 10^4$ 12th d 3.54 $\times 10^2$ 21st d 2.31 $\times 10^2$ 41st d Toxoplasmosis IgM and IgG negative Rubella IgM and IgG negative Herpes simplex IgM and IgG negative	Breast milk PCR: negative
Thrombophilia screening (first wk)	Heterozygote mutation MTHFR A1298C	MTHFR A1298C homozygote mutation
Direct coombs (at birth)	Negative	
Antiphospholipid antibody IgG	Negative	
Antiphospholipid antibody IgM	Negative	
Anticardiolipin antibody IgG	Negative	
Anticardiolipin antibody IgM	Negative	
Lupus anticoagulant	Normal	
Anti s DNA	Negative	
Factors VIII and XI	Negative	
Rheumatoid factor	Negative	

Abbreviations: ALT, alanine aminotransferase; aPTT, activated partial thromboplastin time; AST, aspartate aminotransferase; BUN, blood urea nitrogen; Ca, calcium; CMV, cytomegalovirus; DNA, deoxyribonucleic acid; IgG, Immunoglobulin G; IgM, Immunoglobulin M; INR, international normalized ratio; K, potassium; Na, sodium; PCR, polymerase chain reaction; PT, Prothrombin time; WBC, white blood cells.

<sup>a</sup>Chemiluminescent microparticle immunoassay.

infected with CMV can pass the virus to the fetus at any time during pregnancy. Moreover, this can happen following a primary infection, reinfection with a different CMV strain or reactivation of a previous infection. This means that unlike rubella, preconceptional immunity to CMV is incomplete and intrauterine transmission and damaging fetal infection can occur in women who are CMV seroimmune prior to pregnancy.<sup>7–11</sup> More than 90% of CMV infections during pregnancy are subclinical.<sup>8</sup> Primary maternal infections are more likely to be transmitted to the fetus and intrauterine transmission occurs in 30 to 40% of the cases of primary maternal CMV infection.<sup>9–11</sup> Because no reliable tests can define transmission of infection to the fetus, routine maternal screening for CMV infection during antepartum care is not recommended. However, the critical timing of acute fetal CMV viremia has permitted to diagnose this case. The diagnosis of CMV infection at

birth is made by laboratory testing within 2 to 3 weeks of birth by PCR to detect CMV DNA or viral culture to detect the live virus. Testing samples taken from a neonate more than 2 to 3 weeks after birth cannot distinguish between congenital infection and an infection acquired after birth. We herein demonstrated the critical aortic arch thrombosis in the early neonatal life during the full-blown CMV viremia as verified by the presence of a viral DNA load of 1.77  $\times 10^7$  copies/mL in infant's serum. Laboratory indicators of generalized CMV infection in fetal/neonatal blood have been reported as viral DNA load > 3,000 copies/mL and platelet count < 100,000/mm<sup>3</sup>.<sup>3,12</sup> While fetal viral load > 30,000 copies/mL is also a predictive marker for poor prognosis. Boppana et al reported that no neonates with a viral load < 3,000 copies/mL developed hearing loss.<sup>13</sup> CMV has been reported to infect endothelial cells which enhances thrombin generation. Alternatively, it is



**Fig. 1** Magnetic resonance angiography findings of the thrombosis in the aortic arch extending toward the medial lumen of the brachiocephalic trunk with critical occlusion of the left common carotid artery and left subclavian artery. (A) Loss of calibers in the right internal carotid artery. (B) There is no apparent flow in the right thin anterior cerebral artery (C) No apparent flow is seen in the right thin anterior cerebral artery and mid-cerebral artery. (D) Retrograde and collateral circulation, which is thought to be coming from external carotid artery. (E) Swelling of the basal ganglia and leukomalacia. AFL, anterior frontal longitudinal; PHL, posterior hemisphere longitudinal; RHA, right hemisphere anterior.

possible that the number of endothelial binding sites increases, thereby facilitating adhesion of inflammatory cells and platelets.<sup>5</sup> Besides severe organ failure, CMV infection has been detected more frequently in stillbirths and is associated with fetal thrombotic vasculopathy.<sup>14</sup> Among the clinical features of adult CMV infection, the incidence of thrombosis among acute CMV infection in hospitalized patients was 6.4% and the incidence of acute CMV infection among thrombosis hospitalized patients was 1.9 to 9.1%.<sup>15</sup> Precise diagnosis of fetal tachyarrhythmia and its consequences can be achieved in utero by evaluating hemodynamics with Doppler's ultrasonography on various fetal vessels including the aortic arcus and cerebral arteries. Cost-effectiveness of Doppler's ultrasonography for fetal and neonatal thrombosis and CMV viremia has to be reported.

In conclusion, this case report is an isolated severe thrombotic progress leading to neurologic impairment associated with fetal CMV.

## References

- Price VE, Chan AKC. Arterial thrombosis in children. *Expert Rev Cardiovasc Ther* 2008;6(03):419–428
- Schmidt B, Andrew M. Neonatal thrombosis: report of a prospective Canadian and international registry. *Pediatrics* 1995;96(5, Pt 1):939–943
- Nowak-Gottl U, von Kries R, Gobel U. Neonatal symptomatic thromboembolism in Germany: two-year survey. *Arch Dis Child Fetal Neonatal Ed* 1997;76(03):F163–F167
- Nagel K, Tuckuviene R, Paes B, Chan AK. Neonatal aortic thrombosis: a comprehensive review. *Klin Padiatr* 2010;222(03):134–139
- Sainte S, Suys B, Meyns B, Rega F. Spontaneous aortic arch thrombosis in a neonate. *J Thorac Cardiovasc Surg* 2013;146(03):e15–e16
- Lanari M, Lazzarotto T, Papa I, et al. Neonatal aortic arch thrombosis as a result of congenital cytomegalovirus infection. *Pediatrics* 2001;108(06):E114
- Cytomegalovirus (CMV) and congenital CMV infection. available from: <https://www.cdc.gov/cmV/index.html>; accessed on June 5, 2017
- Ross SA, Fowler KB, Ashrith G, et al. Hearing loss in children with congenital cytomegalovirus infection born to mothers with pre-existing immunity. *J Pediatr* 2006;148(03):332–336
- Demmler GJ. Infectious Diseases Society of America and Centers for Disease Control. Summary of a workshop on surveillance for congenital cytomegalovirus disease. *Rev Infect Dis* 1991;13(02):315–329
- Fowler KB, Stagno S, Pass RF. Maternal immunity and prevention of congenital cytomegalovirus infection. *JAMA* 2003;289(08):1008–1011
- Stagno S, Pass RF, Cloud G, et al. Primary cytomegalovirus infection in pregnancy. Incidence, transmission to fetus, and clinical outcome. *JAMA* 1986;256(14):1904–1908
- Benoist G, Salomon LJ, Jacquemard F, Daffos F, Ville Y. The prognostic value of ultrasound abnormalities and biological parameters in blood of fetuses infected with cytomegalovirus. *BJOG* 2008;115(07):823–829
- Boppa SB, Fowler KB, Pass RF, et al. Congenital cytomegalovirus infection: association between virus burden in infancy and hearing loss. *J Pediatr* 2005;146(06):817–823
- Iwasenko JM, Howard J, Arbuckle S, et al. Human cytomegalovirus infection is detected frequently in stillbirths and is associated with fetal thrombotic vasculopathy. *J Infect Dis* 2011;203(11):1526–1533
- Justo D, Finn T, Atzmony L, Guy N, Steinvil A. Thrombosis associated with acute cytomegalovirus infection: a meta-analysis. *Eur J Intern Med* 2011;22(02):195–199