

Small Bowel Diverticulosis Causing Pneumoperitoneum without Peritonitis: A Case Report

Geena Benjamin¹ Agnes Thomas¹ Mathew Koshy¹

¹Department of Radiodiagnosis, Pushpagiri Institute of Medical Sciences and Research Centre, Thiruvalla, Kerala, India

Address for correspondence Geena Benjamin, MBBS, DMRD, DNB, FRCR, Department of Radiodiagnosis, Pushpagiri Institute of Medical Sciences and Research Centre, Thiruvalla 689101, Kerala, India (e-mail: geenabenjamin@gmail.com).

J Gastrointestinal Abdominal Radiol ISGAR 2018;1:69–71

Abstract

Small bowel diverticulosis is a rare finding, with varied clinical presentations, which make the diagnosis difficult and delayed. Many cases are asymptomatic. However, it is an entity that can present with fatal complications. Here, we present a case of a 79-year-old male patient with diffuse small bowel diverticulosis, who presented with loose stools and acute exacerbation of chronic abdominal pain. Plain abdominal X-ray showed dilated bowel loops and pneumoperitoneum, which raised the possibility of bowel perforation. Computed tomography images revealed diffuse small bowel diverticulosis and pneumoperitoneum. Subsequent explorative laparotomy revealed no bowel perforation. Small bowel diverticulosis is a well-known cause of chronic/recurrent pneumoperitoneum without peritonitis or surgery.

Keywords

- ▶ jejunal diverticulosis
- ▶ pneumoperitoneum without peritonitis
- ▶ small bowel diverticulosis

Introduction

Small bowel diverticulosis is an uncommon entity characterized by formation of outpouchings composed of mucosa and sub mucosa. These are pulsion diverticula occurring at the weakest sites of bowel wall, i.e., along the mesenteric border where mesenteric vessels pierce the muscularis layer of bowel wall.¹ Most often this condition remains asymptomatic and is detected incidentally on imaging or surgery done for some other reason.² However, 10 to 30% patients can present with complications like obstruction, hemorrhage, diverticulitis and perforation causing pneumoperitoneum with peritonitis, and mesenteric abscess.^{3,4} Small bowel diverticulosis can also cause chronic/repetitive pneumoperitoneum without peritonitis through the micro perforations in the wall of the diverticula as a result of hyperactive peristaltic activity or due to transmural passage of air through the markedly thinned out wall of the diverticulum.^{5,6,7} We report a case of small bowel diverticulosis which presented with pneumoperitoneum without bowel perforation or peritonitis.

Case

A 79-year-old male patient with no comorbidities presented to our emergency department with complaints of chronic vague abdominal pain, loose stools since 1 month, and increased pain abdomen for 3 days. On examination, vitals were stable and abdomen was soft. Previously done upper gastrointestinal (GI) endoscopy showed hiatus hernia and gastric erosions. Routine blood investigations revealed elevated WBC (white blood cell) count (13,500 per microliter) with neutrophil predominance. A supine X-ray abdomen was taken which showed small bowel dilatation with the outline of bowel walls clearly seen due to intraluminal and extraluminal air (Rigler's sign positive) indicating pneumoperitoneum (▶ Fig. 1).

To identify the cause of pneumoperitoneum contrast-enhanced CT (CECT) abdomen was done with 128 slice MDCT (multidetector CT) equipment (OPTIMA 660–GE Healthcare, Illinois, United States.; ▶ Fig. 2). Precontrast and postcontrast (arterial: 35 seconds, venous: 60 seconds, delayed: 5 minutes)

received
August 31, 2018
accepted
September 5, 2018

DOI <https://doi.org/10.1055/s-0038-1675433>

©2018 by Indian Society of
Gastrointestinal and Abdominal
Radiology

License terms



images with 0.6-mm sections were acquired from the domes of the diaphragm to just below the pubic symphysis following administration of low osmolar nonionic contrast (Ultravist 370; Berlin, Germany) at the dose of 1 mL/kg and rate of 4 mL/sec. Mannitol was administered as neutral oral contrast agent and Gastrografin (Bracco Diagnostics Inc, Cranbury, NJ) as positive rectal contrast. Delayed images were acquired after further administration of positive oral contrast.

The study confirmed pneumoperitoneum with multiple diverticula arising from small bowel predominantly duodenum and jejunum, some of them being very large in caliber. Largest diverticulum was seen arising from third part of duodenum near duodenojejunal flexure measuring approximately

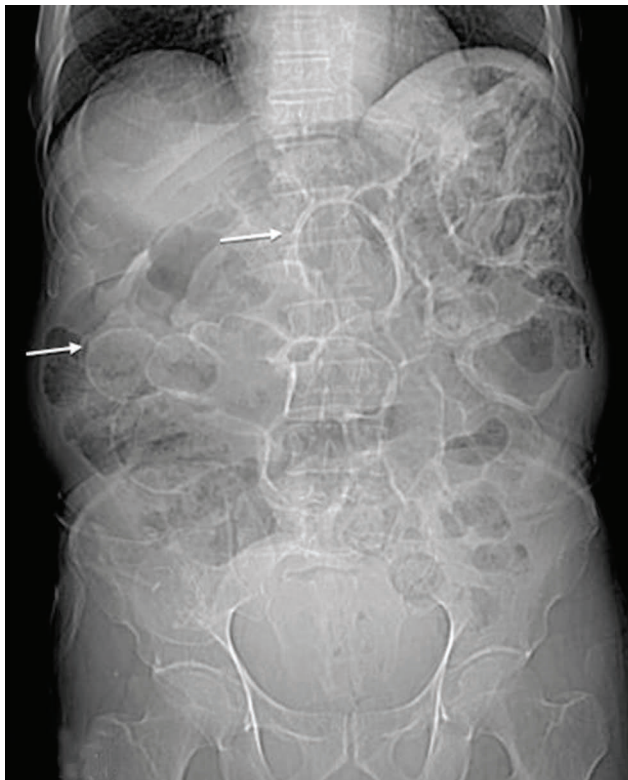


Fig. 1 X-ray abdomen-supine AP view showing dilated bowel loops (which later proved to be diverticula) with bowel wall clearly seen (arrows) due to intraluminal and extra luminal air (Rigler's sign positive). AP, anteroposterior.

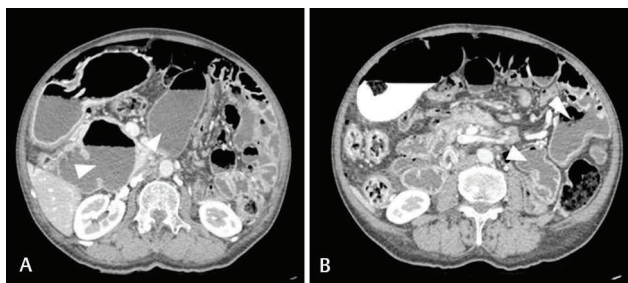


Fig. 2 (A) Axial CECT sections of abdomen with neutral oral contrast in venous phase, show large diverticula (arrowheads) arising from second and third part of duodenum, (B) shows multiple jejunal diverticula (arrowheads). CECT, contrast-enhanced computed tomography.

9 × 4 cm. However, the site of perforation or any other cause of pneumoperitoneum could not be identified (►Fig. 3).

Patient underwent exploratory laparotomy and per operatively numerous small bowel diverticula were noted along the mesenteric border, mostly from duodenum and jejunum (►Fig. 4). Entire length of bowel was inspected for any possible site of perforation but none was found in small or large bowel.

Discussion

Intestinal diverticulosis, a disease more of the western society, is one of the most common conditions affecting large bowel. Left hemi colon, predominantly sigmoid colon, is the most common site for large bowel diverticulosis, followed by right hemi colon. Small bowel diverticulosis which is rare compared with large bowel diverticulosis has an incidence

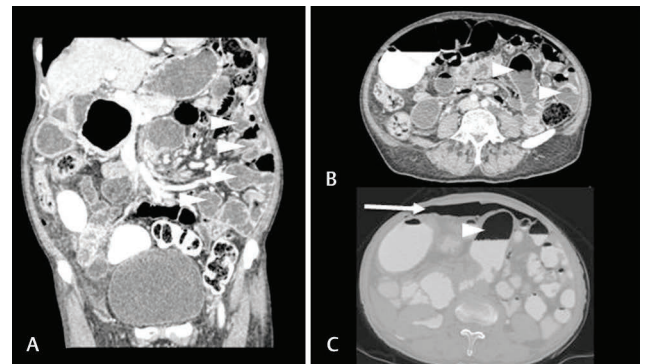


Fig. 3 Coronal reformatted CT image (A) and axial image (B) in venous phase, show multiple jejunal diverticula (white arrowheads). (C) Axial CT image in delayed phase with positive oral contrast, in bone window, shows pneumoperitoneum (white arrow). Large duodenal diverticulum with air contrast level can be seen in left paramedian location (arrowhead). CT, computed tomography;

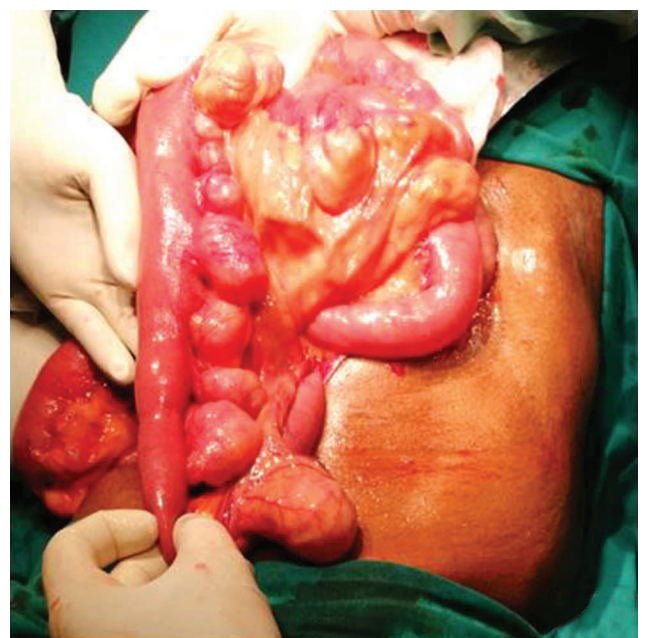

Fig. 4 Per operative image showing numerous small bowel diverticula with no perforation/infection.

of 0.5 to 2.3%.⁸ First description of small bowel diverticulosis was given by Sommering in 1794 and later by Astley Cooper during an autopsy performed during 1809. First operation for diverticula was done in 1906 by Gordinier and Shil.⁹ Duodenum followed by jejunum and ileum are the common sites for small bowel diverticulosis. Jejunum is the more frequent site for diverticulosis than ileum due to the larger caliber of penetrating jejunal arteries.¹⁰

Small bowel diverticula can be congenital or acquired. Meckel's Diverticulum which is a true diverticulum that constitutes the commonest congenital form.¹¹ Acquired small bowel diverticulosis occurs due to abnormalities of smooth muscle or myenteric plexus as in progressive systemic sclerosis (where there is fibrosis and decreased number of normal muscle cells), visceral myopathy (fibrosis and degenerated smooth muscle cells) and visceral neuropathy (neuronal and axonal degeneration).¹² These abnormalities of smooth muscle or myenteric plexus result in altered smooth muscle contractions of small bowel and increased intraluminal pressure. As a consequence, mucosa and submucosa herniate through the weakest points of the bowel wall which is the mesenteric border where vasa recta pierce the muscularis layer resulting in pulsion or pseudo diverticulum.^{6,8}

Small bowel diverticulosis affects individuals above 40 years with male to female ratio 2:1.¹³ Prevalence increases with age, with majority being detected in sixth or seventh decade.⁶ Most cases (around 80%) remain asymptomatic.¹⁴ When symptomatic, they can present with chronic epigastric or periumbilical abdominal pain (especially postprandial pain), constipation, diarrhea, and malabsorption.¹⁵ Sometimes a triad of symptoms as described by Rodriguez et al consisting of epigastric pain, abdominal discomfort, and flatulence 1 or 2 hours after meals may be observed.¹⁶ Acute life-threatening complications such as gastrointestinal hemorrhage, diverticulitis, intestinal perforation with abscess and acute intestinal obstruction may be the initial presentation in 8 to 30% patients.¹⁷ Chronic complications due to small bowel diverticulosis includes malabsorption, blind loop syndrome, enterolith formation, jejunal dyskinesia, chronic diverticulitis, and chronic recurrent pneumoperitoneum without peritonitis.^{6,18}

Diverticular perforation is one of the serious complications which can present with peritonitis. Most often peritonitis caused by perforation of small bowel diverticulosis is localized, contained and self-limiting as the mesentery walls them off.¹⁹ Small bowel diverticulosis can cause pneumoperitoneum without peritonitis as air within the lumen of the diverticulum enters peritoneal cavity through minute perforations in the thin wall of diverticula as a result of hyper peristaltic activity²⁰ or due to transmural passage of air through the markedly thinned out walls of the diverticula.⁶ Other causes for pneumoperitoneum without peritonitis include GI causes (post laparotomy/laparoscopy/paracentesis/peritoneal dialysis, pneumatosis cystoides coli/intestinalis etc.), intrathoracic causes (COPD [chronic obstructive pulmonary disease], asthma, positive pressure ventilation, pneumomediastinum/pneumothorax), and gynecological causes (instrumentation such as hysterosalpingography, Rubin's test, pelvic examination, postpartum knee-chest exercises, and vaginal douching).⁵

In summary, small bowel diverticulosis is a rare entity which can have a wide spectrum of presentations. Our case highlights the need to understand that small bowel diverticulosis is one of the conditions that can cause pneumoperitoneum without peritonitis. This understanding helps in avoiding unnecessary surgery in the absence of clinical evidence of peritonitis in a case of small bowel diverticulosis in spite of presence of pneumoperitoneum.

Conflict of Interest

None.

References

- 1 Ja'afreh S, Odeh J. Complicated diffuse giant small bowel diverticulosis: a case report. *J Royal Med Serv* 2013;20:71-75
- 2 Tsiotos GG, Farnell MB, Ilstrup DM. Nonmeckelian jejunal or ileal diverticulosis: an analysis of 112 cases. *Surgery* 1994;116(4):726-731, discussion 731-732
- 3 Akhrass R, Yaffe MB, Fischer C, Ponsky J, Shuck JM. Small-bowel diverticulosis: perceptions and reality. *J Am Coll Surg* 1997;184(4):383-388
- 4 Wilcox RD, Shatney CH. Surgical implications of jejunal diverticula. *South Med J* 1988;81(11):1386-1391
- 5 Dunn V, Nelson JA. Jejunal diverticulosis and chronic pneumoperitoneum. *Gastrointest Radiol* 1979;4(2):165-168
- 6 Kwak JY, Park EH, Park CS, Kim JH, Han MS, Kwak JH. Uncomplicated jejunal diverticulosis with pneumoperitoneum. *Ann Surg Treat Res* 2016;90(6):346-349
- 7 Alvarez J Jr, Dolph J, Shetty J, Marjani M. Recurrent rupture of jejunal diverticula. *Conn Med* 1982;46(7):376-378
- 8 Longo WE, Vernava AM III. Clinical implications of jejunoileal diverticular disease. *Dis Colon Rectum* 1992;35(4):381-388
- 9 Falidas E, Vlachos K, Mathioulakis S, Archontovasilis F, Villias C. Multiple giant diverticula of the jejunum causing intestinal obstruction: report of a case and review of the literature. *World J Emerg Surg* 2011;6(1):8
- 10 Ferreira-Aparicio FE, Gutiérrez-Vega R, Gálvez-Molina Y, Ontiveros-Nevarés P, Athie-Gutiérrez C, Montalvo-Javé EE. Diverticular disease of the small bowel. *Case Rep Gastroenterol* 2012;6(3):668-676
- 11 Kouraklis G, Glinavou A, Mantas D, Kouskos E, Karatzas G. Clinical implications of small bowel diverticula. *Isr Med Assoc J* 2002;4(6):431-433
- 12 Krishnamurthy S, Kelly MM, Rohrmann CA, Schuffler MD. Jejunal diverticulosis. A heterogenous disorder caused by a variety of abnormalities of smooth muscle or myenteric plexus. *Gastroenterology* 1983;85(3):538-547
- 13 Rankin FW, Martin WJ Jr. Diverticula of the small bowel. *Ann Surg* 1934;100(6):1123-1135
- 14 Altemeier WA, Bryant LR, Wulsin JH. The surgical significance of jejunal diverticulosis. *Arch Surg* 1963;86:732-745
- 15 Palder SB, Frey CB. Jejunal diverticulosis. *Arch Surg* 1988;123(7):889-894
- 16 Rodriguez HE, Ziauddin MF, Quiros ED, Brown AM, Podbielski FJ. Jejunal diverticulosis and gastrointestinal bleeding. *J Clin Gastroenterol* 2001;33(5):412-414
- 17 Butler JS, Collins CG, McEntee GPC. Perforated jejunal diverticula: a case report. *J Med Case Reports* 2010;4:172
- 18 Ross CB, Richards WO, Sharp KW, Bertram PD, Schaper PW. Diverticular disease of the jejunum and its complications. *Am Surg* 1990;56(5):319-324
- 19 Herrington JL Jr. Perforation of acquired diverticula of the jejunum and ileum. Analysis of reported cases. *Surgery* 1962;51:426-433
- 20 Nanson EM, Dragan GE. A spontaneous pneumoperitoneum due to jejunal diverticulosis. *Ann Surg* 1956;143(1):112-116