

Heterogeneous Presentation of Neonatal Hemochromatosis in Dichorionic Twins

Yee Yuet Chee, FHKAM¹ Siu Chun Mabel Wong, FHKAM¹ Ming Sum Rosanna Wong, FHKAM¹

¹Department of Paediatrics and Adolescent Medicine, University of Hong Kong, Hong Kong, Hong Kong

Address for correspondence Yuet Yee Chee, FHKAM, Department of Paediatrics and Adolescent Medicine, University of Hong Kong, 102 Pokfulam Road, Queen Mary Hospital, Hong Kong, Hong Kong (e-mail: yychee@hotmail.com).

Am J Perinatol Rep 2018;8:e332–e334.

Abstract

Acute liver failure (ALF) in neonates is rare. Although the incidence is reported to be rare, neonatal hemochromatosis (NH) has to be considered as one of the causes of neonatal ALF. We present a pair of dichorionic twin who had a diverse clinical presentation of NH. One twin passed away despite medical treatment with exchange transfusion and intravenous immunoglobulin (IVIg), whereas the other twin suffered from only mildly deranged liver function, which normalized spontaneously. Early identification of liver failure and clinical awareness of this disease entity are essential to its timely diagnosis and treatment. Antenatal management using IVIg prevents the recurrence of NH in subsequent pregnancies.

Keywords

- ▶ neonatal hemochromatosis
- ▶ gestational alloimmune liver disease
- ▶ liver failure

Case Report

Clinical Presentation

A dichorionic diamniotic male twin was born at 35 weeks of gestation with a birth weight of 1.6 kg (small for gestational age). The baby presented with recurrent hypoglycemia shortly after birth. Blood tests on the second day of life showed cholestasis (up to 145 $\mu\text{mol/L}$), hypoalbuminemia, hyperam-

monemia (up to 453 $\mu\text{mol/L}$), and coagulopathy, which progressively worsened throughout the first week of life. Work-up for neonatal liver failure was negative for metabolic disease, and surgical and infective causes.

Ferritin level was elevated at 8,397 $\mu\text{mol/L}$. Biopsy of the liver and buccal mucosa was performed. This demonstrated hepatic and extrahepatic iron deposition (**▶ Fig. 1**) and confirmed the

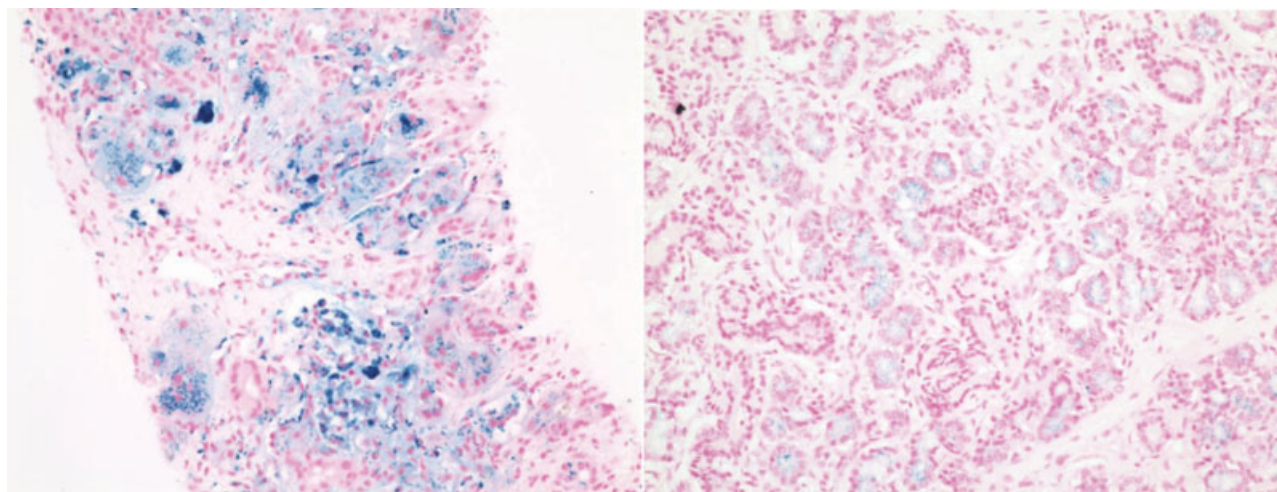


Fig. 1 Liver biopsy showing hepatocellular siderosis (left) and abnormal iron deposition in salivary gland (right), demonstrating iron in blue by Perl's stain.

received
January 31, 2018
accepted after revision
June 19, 2018

DOI <https://doi.org/10.1055/s-0038-1675335>.
ISSN 2157-6998.

Copyright © 2018 by Thieme Medical Publishers, Inc., 333 Seventh Avenue, New York, NY 10001, USA.
Tel: +1(212) 584-4662.

License terms



Table 1 Summary of twins pregnancy affected by NH

	Normal values	Twin set 1 (index)	Twin B	Twin A	Twin set 2 ⁷	Twin B	Twin A	Twin set 3 ⁸	Twin B	Twin A	Twin set 4 ⁹	Twin B	Twin A	Twin set 5 ⁹	Twin B	Twin A	Twin set 6 ¹⁰	Twin B	Twin A	Twin set 7 ¹¹	Twin B	Twin A	Twin set 8 ¹¹	Twin B	Twin A
Pregnancy		Twin A	DCDA	Female	MC	Male	MC	MC	Female	MC	N/A	MCDA	Male	MCDA	Male	MCDA	MC	MCDA	MC	DCDA	Female	DCDA	DCDA	Female	DCDA
Gender		Male	Female	Male	Male	Female	Female	Female	Female	Male	Male	Male	Male	Male	Male	Male	Male	Male	Male	Male	Female	Female	Female	Female	Female
Gestational age (weeks)		35	35	37	37	34	34	34	34	37	27	26	26	26	26	26	33	33	33	35	35	37	37	37	37
Birth weight (kg)		1.6	2.4	2.49	2.5	1.83	1.95	1.83	1.95	2.5	0.92	0.82	0.82	0.82	0.9	2.4	2.4	2.1	2.1	AGA	AGA	AGA	AGA	AGA	AGA
Total bilirubin (umol/L)	<24	368	169	154	197	36	N/A	36	N/A	149	71	476	71	476	476	231	231	67	67	231	67	91	91	238	238
Direct bilirubin (umol/L)	<10	145	11	32	21	19	N/A	19	N/A	N/A	N/A	N/A	N/A	N/A	N/A	113	113	9	9	113	9	7	7	80	80
AST (U/L)	<60	146	371	502	133	34	N/A	34	N/A	N/A	N/A	N/A	N/A	N/A	N/A	N/A	N/A	N/A	N/A	N/A	N/A	N/A	N/A	N/A	N/A
ALT (U/L)	<53	56	162	78	23	101	N/A	101	N/A	98	25	306	25	306	306	27	27	41	41	27	41	21	21	38	38
INR	<2	4.5	1.2	2.8	1.5	3	N/A	3	N/A	1.5	1.2	1.6	1.2	1.6	1.6	4.7	4.7	1	1	4.7	1	2.2	2.2	3.4	3.4
Ferritin (pmol/L)	275-831	8,397	9,801	62,115	5,643	3,596	N/A	3,596	N/A	2,663	5,443	6,625	5,443	6,625	6,625	2,609	2,609	1,539	1,539	2,609	1,539	3,762	3,762	8,865	8,865
NH Treatment		N/G, ET	Not required	N/G	Not required	Antioxidant-chelation therapy	N/A	Antioxidant-chelation therapy	N/A	Antioxidant therapy	Not required	Antioxidant therapy	Not required	Antioxidant therapy	Antioxidant therapy	Antioxidant-chelation therapy	Antioxidant-chelation therapy	Antioxidant therapy	Antioxidant therapy	Antioxidant-chelation therapy	Antioxidant-chelation therapy	Antioxidant-chelation therapy	Antioxidant-chelation therapy	Antioxidant-chelation therapy	Antioxidant-chelation therapy
Outcome		Died on day 33 of life	Healthy at 10 mo	Healthy at 1.5 y	Healthy at 1.5 y	Healthy at 1 y	Died on day 12 of life	Healthy at 1 y	Died on day 12 of life	Alive	Alive	Alive	Alive	Alive	Alive	IUD	IUD	Healthy at 6 mo	Healthy at 1 y	Healthy at 1 y	Healthy at 1 y	Healthy at 10 mo	Healthy at 10 mo	Healthy at 10 mo	Healthy at 10 mo

Abbreviations: AGA, appropriate for gestational age; ALT, alanine aminotransferase; AST, aspartate aminotransferase; DCDA, dichorionic-diamniotic; ET, exchange transfusion; INR, international normalized ratio; IUD, intrauterine demise; N/G, intravenous immunoglobulin; MC, monochorionic; MCDA, monochorionic-diamniotic; N/A, not available; NH, neonatal hemochromatosis .

diagnosis of neonatal hemochromatosis (NH; likely due to gestational alloimmune liver disease, GALD). Medical treatment was given with exchange transfusion and intravenous immunoglobulin (IVIg). However, he failed to respond to medical treatment and developed worsening liver failure. Liver transplantation was considered but deemed not an option due to the low body weight and unavailability of living-related liver donor. After extensive discussion with the parents, the decision for redirection of care was made. The baby was electively extubated and eventually succumbed on day 33 of life.

On the contrary, the other twin girl was born with a birth weight of 2.4 kg and suffered only from mildly deranged liver function only. Her liver function test showed mildly elevated liver enzymes (peak aspartate aminotransferase [AST] of 371 U/L and alanine aminotransferase [ALT] of 162 U/L at around 3 weeks of life) and conjugated bilirubin (11 $\mu\text{mol/L}$), with normal ammonia level and clotting profile all along. Metabolic, surgical, and infective work-ups were negative. Ferritin level was high at 9,801 $\mu\text{mol/L}$. Liver function test subsequently normalized spontaneously upon follow-up.

Family was counseled on the importance of antenatal treatment with IVIg in future pregnancies to prevent the recurrence of NH.

Discussion

Although neonatal liver failure is rarely encountered, one of the most important diagnoses to consider is NH. NH is a rare condition. The exact incidence of the disorder is unknown. Fetal liver injury causes disturbed fetal iron homeostasis, resulting in fetal iron overload. NH is characterized by severe liver injury with the accumulation of iron in hepatic and extrahepatic tissues. The most common cause of fetal liver injury leading to the NH phenotype is a gestational alloimmune disorder called GALD.^{1,2} It results from the transplacental transfer of maternal immunoglobulin G (IgG) directed against an antigen on the fetal hepatocyte, with fetal complement activation and formation of membrane attack complex, resulting in fetal hepatocyte injury and death (with congenital cirrhosis and siderosis of extrahepatic tissues). Once a woman has become sensitized, transplacental passage of IgG can occur in subsequent pregnancy, causing immune-mediated liver injury in the fetus.

Diagnosis of NH is by the demonstration of iron accumulation in the extrahepatic tissues, usually through the biopsy of oral mucosal salivary glands or using T2-weighted magnetic resonance imaging (MRI) demonstrating the accumulation of iron in the pancreas, heart, or adrenal glands.¹ Antibodies to C5b-9 complex, a neoantigen created during the activation of terminal complement cascade, are used to demonstrate the accumulation of membrane attack complex in liver biopsy.² However, this immunohistochemical staining for C5b-9 complex is not available in our locality.

Treatment for NH includes exchange transfusion (by removing existing reactive antibodies) and IVIg (blocking antibody action and interfering with complement activation).^{3,4} Survi-

val with medical treatment (without liver transplantation) is reported to be at around 75%.⁴ If medical treatment fails, liver transplantation remains to be the last therapeutic option.

NH presentation could be quite heterogeneous, as shown in this pair of twins. The twin boy was being affected antenatally with growth restriction and early presentation with hypoglycemia within few hours after birth followed by liver failure. Without the frank presentation of liver failure in one of the index twin, the other twin would have been managed as a case of neonatal hepatitis, and the diagnosis of NH would be missed. With antenatal IVIg treatment, outcome of future pregnancy in our index family is expected to be good.^{5,6}

► **Table 1** summarizes the clinical characteristics of published cases of twins pregnancy affected by NH in the literature.⁷⁻¹¹

Conclusion

In conclusion, a high index of suspicion of NH in babies presenting with cholestasis and deranged liver function is important so as to facilitate its early diagnosis and management. It has a high recurrence in subsequent pregnancies, and antenatal IVIg treatment can greatly reduce this chance.

Conflicts of Interest

All contributing authors declare no conflicts of interest.

References

- Whittington PF. Gestational alloimmune liver disease and neonatal hemochromatosis. *Semin Liver Dis* 2012;32(04):325-332
- Heissat S, Collardeau-Frachon S, Baruteau J, et al. Neonatal hemochromatosis: diagnostic work-up based on a series of 56 cases of fetal death and neonatal liver failure. *J Pediatr* 2015;166(01):66-73
- Lopriore E, Mearin ML, Oepkes D, Devlieger R, Whittington PF. Neonatal hemochromatosis: management, outcome, and prevention. *Prenat Diagn* 2013;33(13):1221-1225
- Rand EB, Karpen SJ, Kelly S, et al. Treatment of neonatal hemochromatosis with exchange transfusion and intravenous immunoglobulin. *J Pediatr* 2009;155(04):566-571
- Whittington PF, Hibbard JU. High-dose immunoglobulin during pregnancy for recurrent neonatal haemochromatosis. *Lancet* 2004;364(9446):1690-1698
- Whittington PF, Kelly S. Outcome of pregnancies at risk for neonatal hemochromatosis is improved by treatment with high-dose intravenous immunoglobulin. *Pediatrics* 2008;121(06):e1615-e1621
- Midorikawa H, Mizuochi T, Okada JI, Hisano T. Disparate clinical findings in monozygotic twins with neonatal hemochromatosis. *Pediatr Int* 2017;59(11):1215-1216
- Korkmaz L, Baştuğ O, Daar G, Doğanay S, Deniz K, Kurtoğlu S. Neonatal hemochromatosis in monozygotic twins. *J Neonatal Perinatal Med* 2015;8(04):413-416
- Isa HM, Mohamed AM. Neonatal hemochromatosis. Case series from Bahrain. *Saudi Med J* 2013;34(12):1274-1280
- Vanden Eijnden S, Hassoun M, Donner C, et al. Iron overload in gestational alloimmune liver disease: still more questions than answers. *Prenat Diagn* 2012;32(08):810-812
- Ekong UD, Kelly S, Whittington PF. Disparate clinical presentation of neonatal hemochromatosis in twins. *Pediatrics* 2005;116(06):e880-e884