

Retrosigmoid Craniectomy for Vestibular Schwannoma with Hearing Preservation

Anthony M. Tolisano¹ Ankur R. Patel² Samuel L. Barnett² Brandon Isaacson¹

¹Department of Otolaryngology-Head and Neck Surgery, University of Texas Southwestern Medical Center, Dallas, Texas, United States

²Department of Neurological Surgery, University of Texas Southwestern Medical Center at Dallas, Dallas, Texas, United States

Address for correspondence Anthony M. Tolisano, MD, Department of Otolaryngology-Head and Neck Surgery, University of Texas Southwestern Medical Center, 5323 Harry Hines Blvd, Dallas, TX 75390, United States (e-mail: anthony.tolisano@gmail.com).

J Neurol Surg B 2019;80(suppl S3):S274–S275.

Abstract

Keywords

- ▶ retrosigmoid craniectomy
- ▶ vestibular schwannoma
- ▶ hearing preservation
- ▶ skull base surgery

Objectives To describe a retrosigmoid craniectomy, hearing-preservation approach for resection of vestibular schwannoma.

Design/Setting/Participants A video of a single patient undergoing the above approach at a tertiary care skull base surgery program.

Results This video demonstrates a retrosigmoid craniectomy approach for resection of an enlarging intracanalicular vestibular schwannoma in a patient with normal hearing. The video highlights the pertinent surgical anatomy and outlines in a step-by-step fashion the surgical steps. The patient obtained a gross total resection with preservation of hearing.

Conclusion A retrosigmoid craniectomy approach for vestibular schwannoma offers a potentially hearing preservation approach for selected tumors.

The link to the video can be found at: <https://youtu.be/VM663XztRZw>.

Conflict of Interest

None.



www.thieme.com/skullbasevideos

www.thieme.com/jnlsbvideos

received
May 30, 2018
accepted
August 19, 2018
published online
October 15, 2018

DOI <https://doi.org/10.1055/s-0038-1675148>.
ISSN 2193-6331.

© 2019 Georg Thieme Verlag KG
Stuttgart · New York

License terms



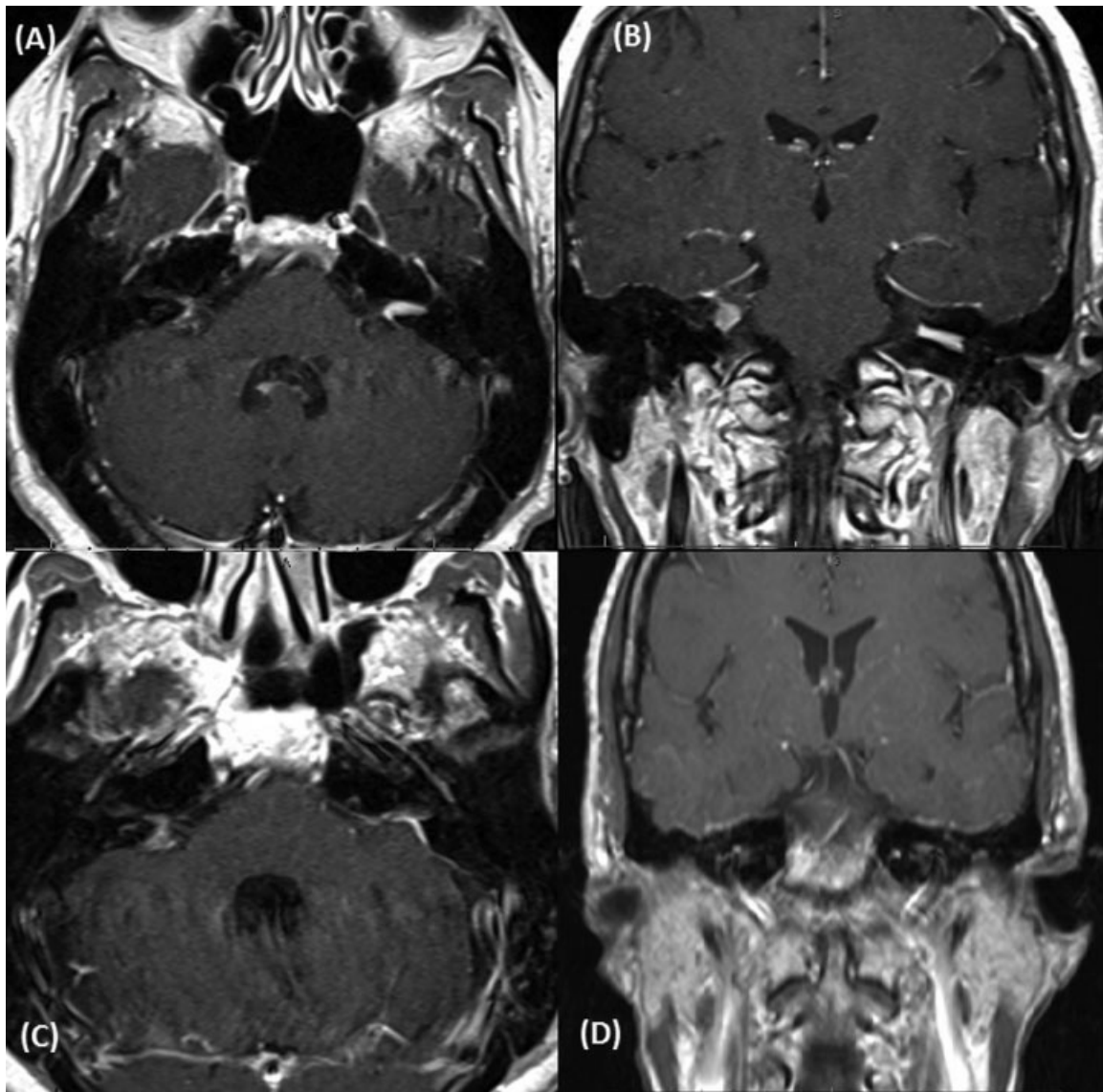


Fig. 1 T1-weighted magnetic resonance images with gadolinium demonstrating (A) preoperative axial, (B) preoperative coronal, (C) postoperative axial, and (D) postoperative coronal images of a left intracanalicular vestibular schwannoma.