

Retrosigmoid Approach for Resection of Cerebellar Peduncle Cavernoma

Hussam Abou-Al-Shaar¹ Gmaan Alzhrani¹ Yair M. Gozal¹ William T. Couldwell¹

¹Department of Neurosurgery, Clinical Neurosciences Center, University of Utah, Salt Lake City, Utah, United States

Address for correspondence William T. Couldwell, MD, PhD, Department of Neurosurgery, Clinical Neurosciences Center, University of Utah, 175 North Medical Drive East, Salt Lake City, UT 84132, United States (e-mail: neuropub@hsc.utah.edu).

J Neurol Surg B 2018;79(suppl S5):S420–S421.

Abstract

The case described in this video involved a 38-year-old man, who presented with a 4-week history of worsening acute-onset headache, nausea, double vision, and vertigo. On examination, he had impaired tandem gait and diplopia on right horizontal gaze. A computed tomography (CT) scan revealed a hyperdense lesion of the right cerebello-pontine angle. Magnetic resonance imaging (MRI) revealed a nonenhancing middle cerebellar peduncle lesion that was isointense on T2-weighted imaging and hypointense on FLAIR imaging (► **Fig. 1A–B**). The differential diagnoses for this lesion included cavernous malformation, thrombosed aneurysm, and neurocysticercosis. CT angiography was done preoperatively to rule out cerebral aneurysm. Surgical resection of the lesion was recommended to relieve his symptoms, to prevent further deterioration/bleeding, and to obtain a pathological diagnosis. The patient underwent a right retrosigmoid craniotomy for resection of the right middle cerebellar peduncle cavernoma (► **Fig. 2**). The patient tolerated the procedure well with no new postoperative neurological deficit. Postoperative MRI depicted gross total resection of the lesion and expected residual blood in the resection cavity (► **Fig. 1C–D**). The patient was discharged home on postoperative day 4. At his last follow-up appointment, 1 month after surgery, he reported complete resolution of his preoperative symptoms, including diplopia. The patient gave consent for publication.

Keywords

- cavernoma
- brainstem
- retrosigmoid approach
- cavernous malformation

The link to the video can be found at: <https://youtu.be/TRieS9DXbV4>.

Conflict of Interest

None.

Acknowledgments

We thank Vance Mortimer for assistance with the video and Kristin Kraus for editorial assistance.



www.thieme.com/skullbasevideos

www.thieme.com/jnlsbvideos

received
May 21, 2018
accepted
August 12, 2018
published online
September 25, 2018

DOI <https://doi.org/10.1055/s-0038-1669974>.
ISSN 2193-6331.

© 2018 Georg Thieme Verlag KG
Stuttgart · New York

License terms



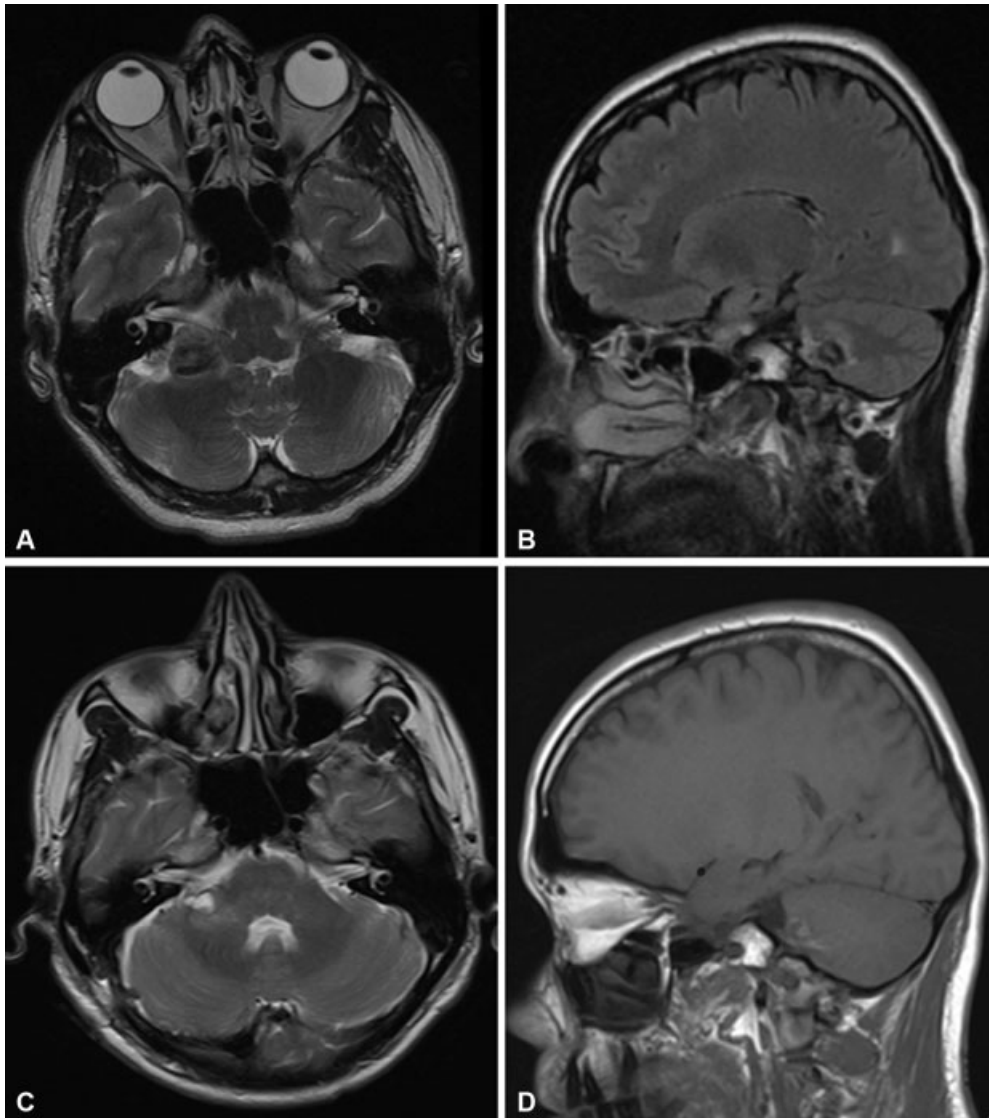


Fig. 1 (A–B) Preoperative magnetic resonance images showing cerebellar peduncle lesion. The lesion was: (A) isointense on axial T2-weighted imaging, and (B) hypointense on sagittal FLAIR imaging. (C–D) Postoperative axial T2-weighted and sagittal T1-weighted magnetic resonance images showing gross total removal of the lesion with some residual blood in the surgical cavity.

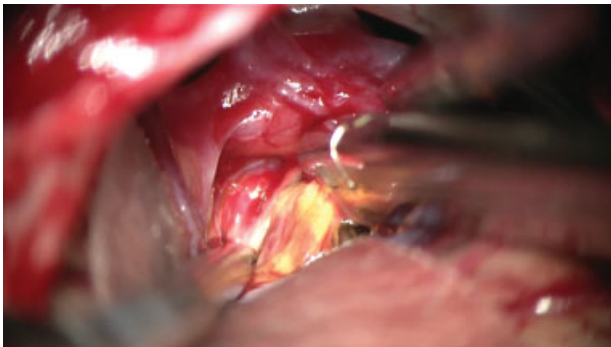


Fig. 2 Intraoperative image demonstrating resection of the hemosiderin-stained cavernoma.