

Gross Total Resection of a Jugular Foramen Thyroid Medullary Metastasis via a Transjugular Transsigmoid Approach

Ilhan Aydin¹ Sima Sayyahmelli¹ Mark Pyle¹ Mustafa K. Baskaya¹

¹Department of Neurological Surgery, University of Wisconsin Medical School, Madison, Wisconsin, United States

J Neurol Surg B 2018;79(suppl S5):S424–S425.

Address for correspondence Mustafa K. Baskaya, MD, Department of Neurological Surgery, University of Wisconsin Medical School, K4/834 CSC, 600 Highland Avenue, Madison, WI 53792-0001, United States (e-mail: baskaya@neurosurgery.wisc.edu).

Abstract

Surgical resection of jugular foramen tumors poses a significant challenge to skull base surgeons with the selection of an appropriate surgical approach, a matter of some debate. Jugular foramen metastatic tumors may mimic paragangliomas, and in some selected cases surgical resection is needed. In this video, we demonstrate the microsurgical gross total resection of a jugular foramen tumor via a postauricular trans-jugular trans-sigmoid approach. The patient is a 61-year-old man with a 7-year history of medullary thyroid cancer, who underwent three neck operations and radiation to the neck. He developed lower cranial nerve palsies (IX, X, and XI) with preoperative aspiration deficits, dysphonia, status post phonosurgery for vocal cord paralysis, profound sensorineural hearing loss, and muscle atrophy of the left shoulder. He initially received stereotactic radiation of the jugular foramen tumor at an outside hospital without histopathological diagnosis. Follow-up magnetic resonance images (MRIs) showed progressive enlargement of the tumor over the post-radiation year. The decision was made to resect this tumor to enable histopathological diagnosis, and to provide local tumor control, since his primary disease has been stable. He underwent microsurgical gross total resection via a transjugular transsigmoid approach. After skeletonizing the sigmoid sinus and jugular bulb, the sigmoid sinus was ligated and rolled toward the jugular bulb, where the major part of the tumor was. Then, using the transjugular route, the tumor was removed en bloc. The surgery and postoperative course were uneventful. The histopathology was a thyroid medullary cancer metastasis. He was followed with serial MRIs, and there was no recurrent tumor at 2 years follow-up. In this video, microsurgical techniques and important steps for the resection of a jugular foramen metastatic tumor are demonstrated.

The link to the video can be found at: <https://youtu.be/oXC6fX2CC84>.

Keywords

- ▶ skull base
- ▶ jugular foramen
- ▶ thyroid medullary cancer
- ▶ metastasis
- ▶ transjugular transsigmoid approach



www.thieme.com/skullbasevideos

www.thieme.com/jnlsbvideos

received
May 30, 2018
accepted
August 12, 2018
published online
September 25, 2018

DOI <https://doi.org/10.1055/s-0038-1669970>
ISSN 2193-6331.

© 2018 Georg Thieme Verlag KG
Stuttgart · New York

License terms



Conflict of Interest
None.

Disclosure of Funding
None.

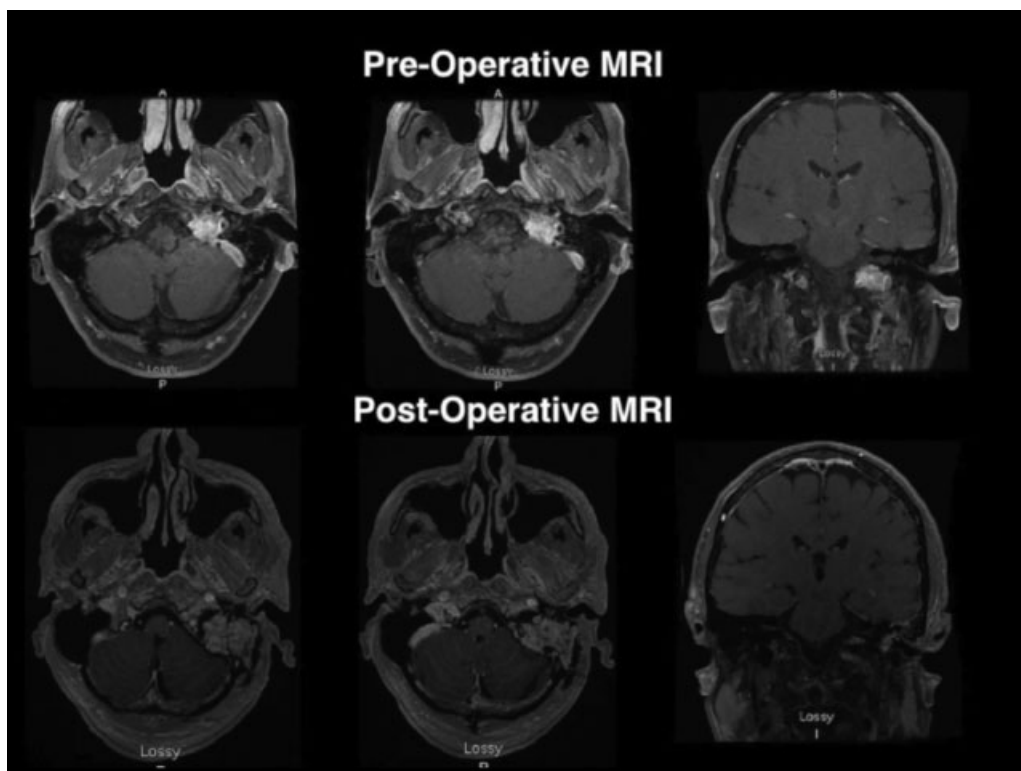


Fig. 1 Pre and postoperative images.

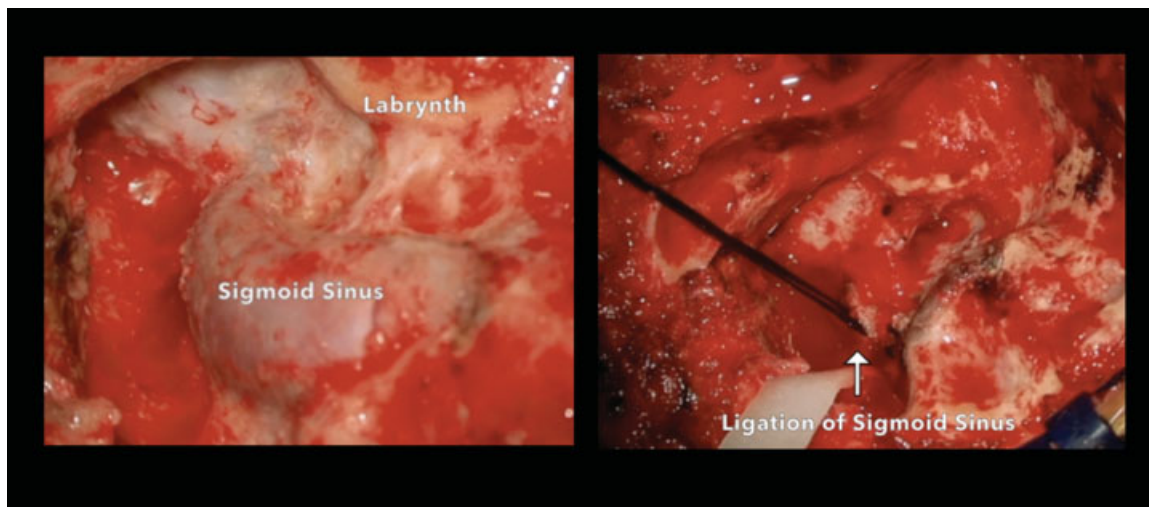


Fig. 2 Intraoperative images.