

# Robotic-Assisted Sleeve Lobectomy Using the Four-Arm Technique in the DaVinci Si<sup>®</sup> and Xi<sup>®</sup> Systems

Jan-Hendrik Egberts<sup>1</sup> Thorben Möller<sup>1</sup> Thomas Becker<sup>1</sup>

<sup>1</sup>Department for General, Visceral-, Thoracic-, Transplantation-, and Pediatric Surgery - Kurt Semm Center for laparoscopic and robotic surgery, University Hospital Schleswig Holstein, Campus Kiel Germany

Address for correspondence Prof. Dr. med. Jan-Hendrik Egberts, Department for General, Visceral-, Thoracic-, Transplantation-, and Pediatric Surgery - Kurt Semm Center for laparoscopic and robotic surgery, University Hospital Schleswig Holstein, Campus Kiel Arnold-Heller-Str. 3 24105 Kiel, Germany (e-mail: Jan-Hendrik.Egberts@uksh.de).

Thorac Cardiovasc Surg 2019;67:603–605.

## Abstract

Sleeve lobectomy (SL) makes it possible to resect centrally located lung carcinoma oncologically correct while protecting healthy lung tissue. However, this procedure is often limited with conventional video-assisted thoracoscopic surgery, due to the limited mobility of the rigid and long instruments and the limited visualization. Therefore, these interventions are often still performed in the open conventional technique with the well-known disadvantages. Particularly in the reconstruction of the respiratory tract, precise sewing must be performed in a small space to avoid stenosis of the different diameter of the lumina. Robotic surgery offers several advantages through an enlarged three-dimensional view and flexibility of the robotic instruments, which are particularly evident when sewing. So far, there are only a few reports of robotic SL. Here, we describe our experience of performing robotic SL with four arms on both, the currently available DaVinci Xi<sup>®</sup> and Si<sup>®</sup> systems.

## Keywords

- ▶ lung
- ▶ surgery
- ▶ robotic
- ▶ RATS
- ▶ sleeve lobectomy

## Introduction

Sleeve lobectomy (SL) is one of the most challenging operations in lung surgery, and only selected institutions offer a minimal invasive approach by video-assisted thoracoscopic surgery (VATS). The reconstructing of the airways with conventional VATS instruments is difficult and uncomfortable and is therefore often combined with minithoracotomies. In this context, the use of robot-assisted technology seems predestined since the precision and agility of the instruments eliminate the drawbacks of traditional VATS instruments.<sup>1</sup> The use of an additional, fourth robotic arm brings considerable advantages, in particular, in the reconstruction of the airway compared with the conventional minimally invasive technique: on the one hand, the structures can be tension-free adapted, and on the other hand, a maintenance of a constant thread tension is possible. The use of barbed sutures, which is described here for the first time, further improves the precision.

We present our set up and technique for a SL using the four-arm technique and describe the differences between Si<sup>®</sup> systems of the older generation as well as the currently available Xi<sup>®</sup> system.

## Technique Description

We perform SL on both the daVinci Si<sup>®</sup> and Xi<sup>®</sup> systems (Intuitive Surgical, Sunnyvale, California, United States). We describe the technique for the Xi<sup>®</sup> system and, in the case of a modification for the Si<sup>®</sup> system, indicate it accordingly. We describe the surgical steps for a right-sided SL.

## Port Placement

The patient is in a left lateral position. The trocar placement and trocar sizes are shown in ▶Fig. 1. We adopted the approach as described by Cerfolio et al.<sup>2</sup> with our own modifications.<sup>3</sup> The trocar placement for upper and middle

received

February 13, 2018

accepted after revision

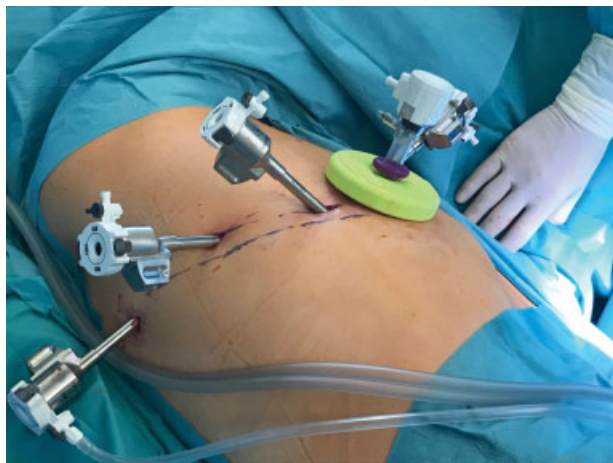
April 23, 2018

published online

June 16, 2018

© 2019 Georg Thieme Verlag KG  
Stuttgart · New York

DOI <https://doi.org/10.1055/s-0038-1660508>.  
ISSN 0171-6425.



**Fig. 1** Port placement for the Xi<sup>®</sup>-System: above the eighth rib with a distance of 6 cm between the trocars.

lobe procedures is above the eighth rib with an assistant trocar in intercostal space caudally. An Alexis wound retractor (size “A”) with a cap (Applied Medical, Rancho Santa Margarita, California, United States) is placed in a minithoracotomy of 3 cm, and a 12-mm port is inserted. This serves for the specimen removal and an emergency port. The distances of the trocars are 6 cm (8 cm in the Si<sup>®</sup> system). We work with the installation of a pneumothorax with a pressure of 8 mm Hg. The console surgeon operates with one instrument on the right (R1) and two instruments controlled by the left hand (R3 and R4). A 30-degree endoscope is placed in arm 2.

For the Si<sup>®</sup> system, a 12-mm camera port is inserted and two 8 mm trocars for the instruments in the same intercostal space. An additional 5 mm trocar is placed most posteriorly. Unfortunately, there are no 5 mm instruments currently available for the Xi<sup>®</sup> system (►Table 1). Robotic arms are docked with approach from the right side of the patient, by positioning the robot over the patient’s shoulder. The instruments used in the different systems are shown in ►Table 1.

### Dissection

The resection starts with the mobilization of the upper lobe by lifting it with robot arm 3 and dissecting the pulmonary artery in the interlobium. After identifying the segment 6, the segment 2 branch of the upper lobe is transected and the dorsal fissure is freed. Then, the upper lobe is pulled down by arm 3 and the surrounding pleura of the hilum are dissected. Lymph node station 10 is released. The anterior stem of the

segments 1 and 3 branches as well as the right upper pulmonary vein are identified and encircled and transected. The anterior fissure is now transected by linear staples.

Thereafter, the lower lobe is mobilized by dissecting the pulmonary ligament, collecting lymph node stations 8, 9, and 7.

### Transection of the Bronchus Intermedius

The anatomical structures need to be neatly displayed but not skeletonized, and traumatization of the bronchial wall must be avoided. Likewise, bronchi and vessels should only be used with atraumatic forceps, avoiding any contusion of the tissue. For cutting the bronchus, we use the monopolar curved scissors and start at the margin of the intermedius bronchus, followed by the right main stem bronchus margin. Frozen sections confirm the pathological free resection margins.

### Anastomosis

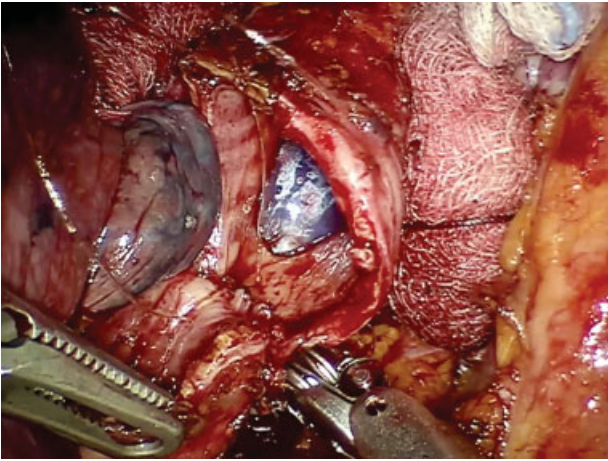
We use the large robotic needle driver and Cadiere Forceps. For anastomosis, we prefer a monofilament barbed suture (Stratafix 3/0, Ethicon Endosurgery, Inc., Cincinnati, Ohio, United States) (►Fig. 2). In our own practice, we have best experience with circumscribed continuous anastomosis. The first suture is placed on the posterior part of the right bronchus intermedius from out to in, to place the knot outside the airway. The corresponding stitch is performed on the right main stem bronchus from in to out, and this places the knot in the cartilage of the main stem bronchus close to the membranous part. It is important to perform the first stitch in this area to ensure adequate suture retention. The anastomosis is continued through the cartilaginous part, while slowly bringing the two cut ends together. When half of the circumference is reached, a second suture is used. The incongruity of both lumina can be compensated by different seam distances on both sides. We perform a leak test under water and cover the anastomosis with either a mediastinal tissue flap or an intercostal muscle flap. Finally, 24Ch chest tube is placed (►Video 1).

### Video 1

RATS right upper sleeve lobectomy using the four-arm technique. Online content including video sequences viewable at: <https://www.thieme-connect.com/products/ejournals/html/doi/10.1055/s-0038-1660508>.

**Table 1** List of used instruments in the Xi<sup>®</sup> and Si<sup>®</sup>

System	L2 (left hand)	L1 (left hand)	Camera	R (right hand)
DaVinci Xi <sup>®</sup>	Tip up fenestrated (8 mm)	Cadiere Forceps (8 mm)	8 mm trocar	– Curved bipolar dissector or long bipolar grasper (8 mm) – Monopolar scissors (8 mm) – Large needle driver (8 mm)
DaVinci Si <sup>®</sup>	Thoracic grasper (5 mm)	Cadiere Forceps (8 mm)	12 mm extralong trocar	– Curved bipolar dissector – Monopolar scissors (8 mm) – Large needle driver (8 mm)



**Fig. 2** Anastomosis of the right main stem bronchus and right intermedius bronchus. Cartilaginous aspect of the airway anastomosis is half-completed. Cuff of the double lumen tubus visible.

## Discussion

Our RATS technique combines the advantages of the minimal invasive procedure and the precise of the robotic dissection and suture. Especially for the reconstruction of the airways, the robotic reveals its advantages. The use of the presented four-

arm technique provides even more advantages: better exposure, tensioning, and stabilization of the tissue and structures with a stable operation under the control of the surgeon. It also reduces the number of instrument changes to a minimum. In addition, we have best experience with the use of a continuous anastomosis. Here, the level of evidence in the literature is limited to a few small series.<sup>4</sup> We describe the use of a barbed suture. Due to the memory effect of the suture, the alleged disadvantage of the missing tactile feedback can easily be compensated. Our own experience includes eight robotic bronchoplastic operations, of which five are SLs. So far, we have not observed any technical complications.

## References

- 1 Park BJ, Melfi F, Mussi A, et al. Robotic lobectomy for non-small cell lung cancer (NSCLC): long-term oncologic results. *J Thorac Cardiovasc Surg* 2012;143(02):383–389
- 2 Cerfolio RJ. Robotic sleeve lobectomy: technical details and early results. *J Thorac Dis* 2016;8(Suppl 2):S223–S226
- 3 Egberts J-H, Schlemminger M, Schafmayer C, Dohrmann P, Becker T. Robot-assisted minimally invasive lobectomy with systematic lymphadenectomy for lung cancer [in German]. *Zentralbl Chir* 2015;140(01):15–16
- 4 Shao F, Liu Z, Pan Y, Cao H, Yang R. Bronchoplasty using continuous suture in complete monitor view: a suitable method of thoracoscopic sleeve lobectomy for non-small cell lung cancer. *World J Surg Oncol* 2016;14:134