

Difficulty in Central Venous Cannulation due to Kinked Guidewire: Intravenous Cannula Comes to Rescue!

Ritesh Lamsal¹ Surya Kumar Dube¹ Ashish Bindra¹

¹Department of Neuroanaesthesiology and Critical Care, All India Institute of Medical Sciences, New Delhi, India

Address for correspondence Surya Kumar Dube, MD, DM, Department of Neuroanaesthesiology and Critical Care, 7th Floor, Neurosciences Center, All India Institute of Medical Sciences, New Delhi 110029, India (e-mail: surya.dube@yahoo.co.in).

J Neuroanaesthesiol Crit Care 2018;5:117–118.

Insertion of central venous catheter (CVC) can be difficult and challenging in children and can have several procedure-related as well as long-term complications.^{1,2} The use of the ultrasound facilitates the procedure by delineating the vascular anatomy and minimizing the risk of serious complications. However, certain problems related to the small and fragile guidewire of the pediatric central venous cannulation set are frequently encountered in clinical practice. We report one such problem and method to overcome it.

In our case, catheterization of the right internal jugular vein (IJV) was attempted with a 5F CVC under ultrasound guidance in a 2-year-old boy scheduled to undergo surgery for posterior fossa tumor. We encountered difficulty in inserting the guidewire into IJV thrice in spite of getting free flow of blood after puncture of the central vein with the introducer needle. In fourth attempt, we could manage to insert the guidewire, but we encountered difficulty in advancing the CVC over the guidewire even after dilating the skin tract. Therefore, we removed the CVC and railroaded the entire sheath of the 22G intravenous (IV) cannula over the guidewire and removed the guidewire, keeping the sheath inside. The removed guidewire was found to be kinked (► Fig. 1A). We confirmed the IV position of the sheath after observing free flow of blood on aspiration. Insertion of a new guidewire was attempted through the IV cannula sheath, and adequate length of the guidewire could be easily inserted. The rest of the procedure was uneventful, and the CVC could be inserted easily. The child did not have any CVC insertion-related complication in the postoperative period.

In our case, probably owing to the pressure applied while railroaded the CVC over the guidewire, the soft and fragile guidewire got kinked preventing the advancement of the CVC further. In that situation, current practice advocates removal of the guidewire and reattempting CVC. However, we tried CVC insertion using a 22G IV cannula (► Fig. 1B), because we were not able to insert the guidewire into IJV. It was probably due to displacement of introducer needle (after localization of vein), either before or during insertion of J-tip guidewire. This can happen during pediatric CVC insertion.³ Finally, when we inserted the guidewire into the IJV, it got kinked while railroaded the CVC. Hence, reattempting CVC insertion might not have solved the problem and would have led to another puncture, thereby increasing the risk of further CVC insertion-related complications. Use of IV cannula for ease of CVC insertion in pediatric patients has been reported previously.^{3,4} In our case, being soft and flexible, the IV cannula sheath could be easily threaded over the kinked portion of the guidewire into the central vein. Later, the sheath acted as a conduit for insertion of a new guidewire.

With this report, we suggest use of IV cannula for exchanging kinked guidewire during difficult CVC insertion in pediatric patients.

Funding

None.

Conflict of Interest

None.

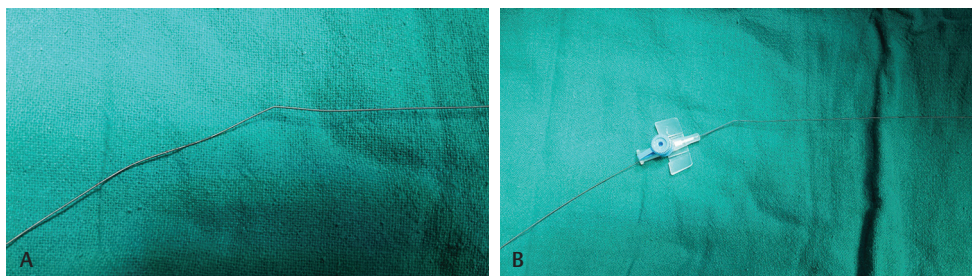


Fig. 1 (A) Kinked guidewire. (B) Guidewire inside a 22G intravenous catheter.

received
February 23, 2018
accepted
April 16, 2018
published online
May 18, 2018

DOI <https://doi.org/10.1055/s-0038-1655900>.
ISSN 2348-0548.

Copyright ©2018 Indian Society of Neuroanaesthesiology and Critical Care

License terms



References

- 1 Stenzel JP, Green TP, Fuhrman BP, Carlson PE, Marchessault RP. Percutaneous central venous catheterization in a pediatric intensive care unit: a survival analysis of complications. *Crit Care Med* 1989;17(10):984–988
- 2 Sheridan RL, Weber JM. Mechanical and infectious complications of central venous cannulation in children: lessons learned from a 10-year experience placing more than 1000 catheters. *J Burn Care Res* 2006;27(5):713–718
- 3 Dube SK, Chaturvedi A. A simple technique to avoid difficulty in guide wire insertion during pediatric central venous cannulation. *Saudi J Anaesth* 2014;8(1):141–142
- 4 Nakayama S, Takahashi S, Toyooka H. Curved-end guidewire for central venous cannulation in neonate. *Anesth Analg* 2003;97(3):917–918