

# Dynamic Distal Radioulnar Stabilization for Treatment of Triangular Fibrocartilage Complex Rupture Associated to Distal Radius Fracture — A New Surgical Technique

## *Estabilización dinámica radiocubital distal para el tratamiento de la rotura del complejo Fibrocartílago triangular asociada a fractura de extremidad distal de radio — una nueva técnica quirúrgica*

Samuel Pajares Cabanillas<sup>1</sup> Natalia Martínez Catalán<sup>2</sup> Emilio Calvo Crespo<sup>3</sup>

<sup>1</sup>Wrist and Hand Unit, Orthopedics and Traumatology Service of the Hospital Universitario Fundación Jiménez Díaz, Madrid, Spain

<sup>2</sup>Orthopaedics and Traumatology Service, Hospital Universitario Fundación Jiménez Díaz, Madrid, Spain

<sup>3</sup>Orthopaedics and Traumatology Department, Hospital Universitario Fundación Jiménez Díaz; Hospital Universitario Infanta Elena, Valdemoro; Hospital General de Villalba, Universidad Autónoma Servicio Cirugía Ortopédica y Traumatología, Madrid, Spain

Address for correspondence Samuel Pajares Cabanillas, MD, Hand Surgery, Orthopedics Department, Hospital Universitario Fundación Jiménez Díaz, Av. de los Reyes Católicos, 2, 28040, Madrid, Spain (e-mail: capisam@hotmail.com).

Rev Iberam Cir Mano 2018;46:52–59.

### Abstract

Distal radioulnar joint instability due to a tear of the triangular fibrocartilage complex (TFCC) secondary to fractures of the distal radius is one of the most difficult complications to treat in our specialty. Early functional recovery of postoperative radius fracture requires early mobilization and consequently it can result in a poor TFCC healing. On the other hand, the correct treatment of this rupture, regardless of the treatment performed (conservative, open or arthroscopic repair), requires an immobilization of the wrist and elbow for a period of at least 6 to 8 weeks. This fact may compromise the functional result of both the radius surgery and the radioulnar movement. We here describe the first surgical technique reported in the literature that allows a correct healing of the TFCC at the same time that mobilization of the wrist begins in the first week of the postoperative period, for both the radiocarpal and distal radioulnar joints. It is a surgical procedure to be performed immediately after osteosynthesis of the distal radius. It is a simple technique with low morbidity, which stabilizes the distal radioulnar joint in a dynamic way, so that the direction of rotation in which the instability is reproduced is restricted, stabilizing translational movement in the dorsopalmar plane and joint opening.

### Keywords

- ▶ radioulnar
- ▶ fibrocartilage
- ▶ distal radius

### Resumen

La inestabilidad radiocubital distal (RCD) secundaria a rotura del Complejo fibrocartílago triangular (FCT) producida en fracturas del radio distal es una de las

received  
February 8, 2018  
accepted  
March 27, 2018

DOI <https://doi.org/10.1055/s-0038-1651505>.  
ISSN 1698-8396.

Copyright © 2018 Thieme Revinter  
Publicações Ltda, Rio de Janeiro, Brazil

License terms



complicaciones más frecuentes y de más difícil manejo en nuestra especialidad. La recuperación funcional precoz de la síntesis del radio, exige movilización temprana y en consecuencia mala cicatrización del FCT. Por otro lado el correcto tratamiento de esta rotura, independientemente del tratamiento realizado (conservador, reparación abierta o artroscópica), obliga a una inmovilización de la muñeca y codo por un periodo no inferior a 6 semanas. Este hecho puede comprometer el resultado funcional tanto de la síntesis del radio, como de la pronosupinación. Se describe la primera técnica quirúrgica en la literatura que permite una correcta cicatrización del FCT, al mismo tiempo que se inicia la movilización a la primera semana del postoperatorio, tanto de la articulación radiocarpiana, como de la RCD. Se trata de una cirugía a realizar inmediatamente después de la síntesis del radio, de técnica sencilla y de escasa morbilidad, que consigue estabilizar la articulación RCD de una forma dinámica, de manera que el sentido del giro donde se reproduce la inestabilidad queda restringido, estabilizando el movimiento de traslación dorsopalmar y la apertura articular.

### Palabras Clave

- ▶ radiocubital
- ▶ fibrocartilago
- ▶ radio distal

## Introduction

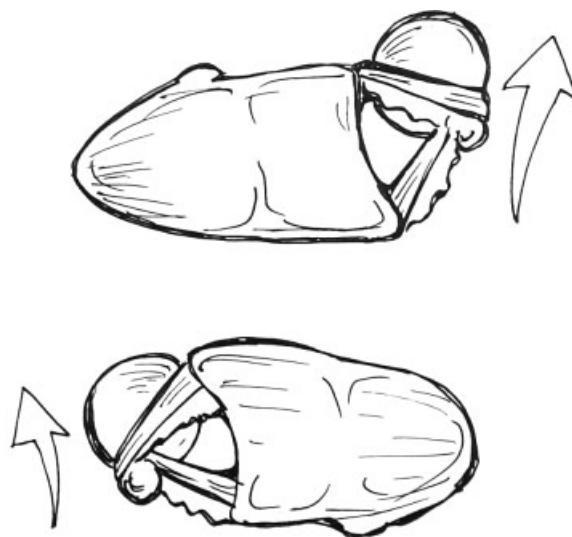
Fracture of the distal radius is one of the most common lesions in our environment. Distal radius fractures account for the most frequent fracture of the upper limbs and the third most frequent type of osteoporotic fracture. Distal radius fracture has been very often associated with instability or dysfunction of the distal radioulnar joint (DRUJ) due to acute ligamentous injury of the triangular fibrocartilage complex (TFCC).<sup>1,2</sup> It has been shown that the presence of TFCC lesions may worsen the prognosis of the initial lesion.<sup>3,4</sup>

A series of clinical and radiological parameters, which are well-defined in the literature, are used to establish orthopedic or surgical treatment of the fracture. Most of them are based on tracing of the fracture, displacement, joint involvement, comminuted fracture or number of fragments, etc. However, the criteria of surgical treatment for associated ligamentous injuries have not been so well defined, although radiological predictive factors for rupture of the TFCC have been proposed.<sup>5</sup> On the other hand, in contrast to great advances made in the improvement of surgical techniques of distal radius fractures to achieve a prompt return of the patients to their social and work activities,<sup>6</sup> in the case of ligamentous injuries of the distal radioulnar joint, there has not been any technical or scientific progress to accelerate the recovery.

Despite the high incidence of DRUJ instability in fractures of the distal radius,<sup>7-10</sup> the current surgical treatment of these fractures continues to be focused on the radiocarpal joint while the importance of the DRUJ function remains underestimated.

It is difficult to establish a diagnosis of acute DRUJ instability using only a radiographic study.<sup>11</sup> Clinical examination is currently the gold standard to assess radioulnar instability associated with a distal radius fracture. In the so-called ballottement test or maneuver, the patient's affected wrist is examined under anesthesia, and DRUJ instability is confirmed if there is excessive motion when compared with the normal contralateral wrist. The maneuver is performed

with the forearm in intermediate pronosupination position, looking for dislocation without dorsal or palmar stop<sup>4,12</sup> (→Fig. 1). Magnetic resonance imaging (MRI) or arthro-computed tomography (CT) studies are useful to assess DRUJ lesions, although the current trend is to diagnose this type of tears with intraoperative diagnostic arthroscopy.<sup>13</sup> In studies in which diagnostic arthroscopy has been performed, a high incidence of TFCC lesions associated with distal radius fractures (up to 75%) has been reported; however, the frequency of symptomatic tears of the TFCC causing clinical instability is unknown. In these cases, the patient will present radioulnar joint instability and pseudodislocation of the ulna, with dorsal dislocation occurring more frequently than volar depending on whether the injured ligament component is dorsal or palmar. The anatomical shape of the sigmoid notch of the distal radius, with a long "S" or "C" and more coverage in the palmar than in the dorsal region,



**Fig. 1** Anatomic dorsal and volar translational movement according to pronation (upper image) or supination (lower image).

determines the more common dorsal direction of the instability (►Fig. 1). This subluxation occurs during pronation or supination of the forearm, associated with pain in the ulnar region of the wrist and subjective feeling of loss of wrist stability. In the long-term, there is a decrease in strength and even loss in the range of motion, clicks with pronosupination movements, and in more advanced stages, radioulnar arthropathy can be found.

In the presence of clear DRUJ instability due to rupture of the TFCC, satisfactory results have been obtained with immobilization only using a brachial cast (including immobilization of the wrist and elbow to avoid rotation) during a period of ~8 to 9 weeks.<sup>14</sup> In addition to this immobilization, other approaches in the acute phase include arthroscopic repairs of the TFCC,<sup>15,16</sup> needle fixation with Kirschner wires or open repairs (most open-repair procedures have not been described in the context of acute fractures of the distal radius). The correct treatment of ulnar styloid fractures is a matter of debate, but according to the most recent literature there is no evidence of a correlation between fractures and appearance of TFCC rupture and instability of the radioulnar joint.<sup>17</sup> In cases of deferred lesions (time lapsed from the injury 4–6 weeks) in which primary ligament healing is not possible, a ligamentoplasty<sup>18</sup> or an ulnar shortening osteotomy can be performed.

At the present time, there is no history of a surgical technique that allows the healing of tears of the TFCC without the need for rigid immobilization of the wrist and elbow. Our technique, through dynamic selective immobilization in pronosupination, allows a partial mobilization in supination or pronation (depending on the type of rupture) and a complete flexion, extension, radial and ulnar deviation of the radiocarpal joint.

## Indications

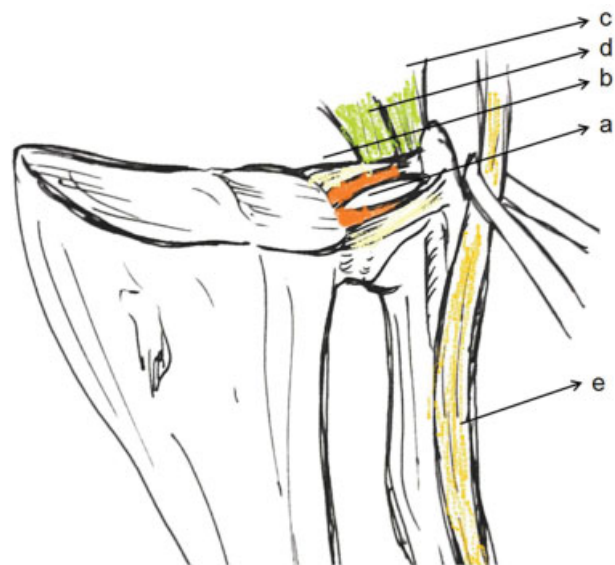
At the present time, indications of this procedure are as follows:

- Acute complete lesions of the TFCC with clinical repercussion of instability associated with distal radius fractures meeting the criteria for surgical treatment, the pattern of fracture or stability after surgery of which would allow early mobilization.
- Ages of the patients between 18 (or physeal closure) and 65 years.

## Contraindications

However, this procedure should not be performed in the following cases:

- Chronic lesions (more than 6–8 weeks after the index episode).
- Severe osteoporosis.
- Metaphyseal-diaphyseal junction fracture.
- Ulnar neck fracture.
- History of previous pathology in the affected wrist, concomitant tendinous or neovascular lesion.



**Fig. 2** Anatomic structure of the triangular fibrocartilage complex showing the radioulnar ligaments, the deep (A) and superficial (B) layers, the ulnotriquetral ligament (C), the ulna-semilunar ligament (D) and the extensor carpi ulnaris tendon (E).

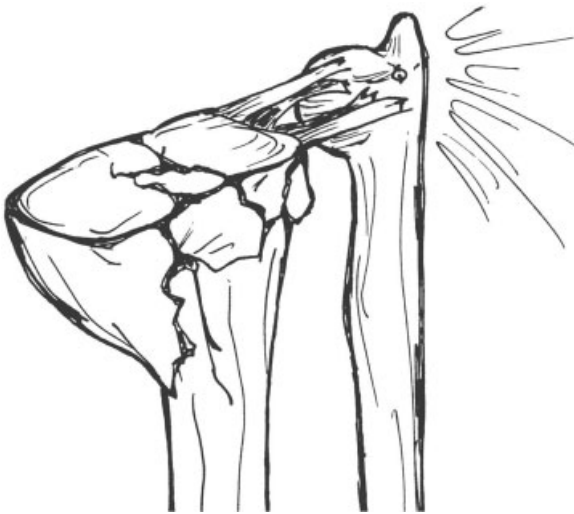## Surgical Anatomy

Due to the lack of osseous congruency, the stability of the radioulnar joint depends mainly on soft tissues. Intrinsic stabilizers provide primary stability and include volar and dorsal radioulnar ligaments of the TFCC. The deep fibers of the volar and dorsal radioulnar ligaments, or ligamentum subcruentum, converging toward their insertion to the fovea at the base of the ulnar (►Fig. 2) have an important role in the maintenance of carpal stability. These ligaments acquire a certain tension according to the position of rotation of the wrist, either in pronation or supination. Extrinsic secondary stabilizers include the ulnotriquetral (UT) ligament, the ulna-semilunar (US) ligament and the interosseous membrane (particularly the distal oblique band) provide additional static stabilization to the DRUJ. On the other hand, the tendon of the extensor carpi ulnaris is an extrinsic dynamic stabilizer of the DRUJ, and its role in the rehabilitation treatment of these lesions is essential.

Most TFCC tears with clinical repercussion present with ulna to dorsal instability, due to involvement of the deep dorsal or volar radioulnar fascicle of the DRUJ (it is still debated which rupture participates more in the instability). It should be remembered that they are present at the volar, and at the dorsopalmar level (►Fig. 3).

## Surgical Technique

The new surgical technique, radioulnar stabilization (RUS), is based on the use of a double anchoring system, one in the radial metaphysis and the other in the ulnar neck, which fixes a suture tape placed in an oblique direction between the two bones, from the dorsal surface of the ulna to the volar region of the radius through the interosseous membrane.

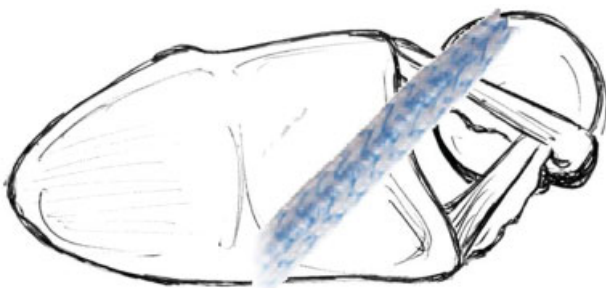


**Fig. 3** Dorsal and volar ligamentous rupture in a comminuted fracture of the distal radius.

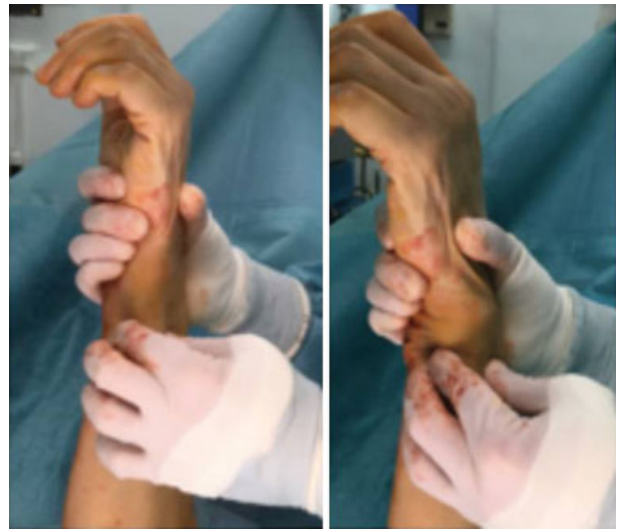This tape remains taut when we rotate the hand in pronation, which prevents translation of the ulna dorsally when there is a tear of the TFCC, allowing complete supination (► **Fig. 4**). Contrarily, in the presence of volar instability, the configuration of the tape has a disposition from the dorsal aspect of the radius to the volar region of the ulna, so that it is possible to simultaneously mobilize completely a component of the rotation movement (supination/pronation), partially another component (pronation/supination) and completely the mobility of the radiocarpal joint. This system allows healing in a position of stability of the TFCC, while mobilization is allowed. This novel approach has never been described in the medical literature.

To perform this technique, two elements are necessary:

- **Suture tape:** Polyethylene high molecular weight braided structure, 2 mm wide, with high resistance to tensile stress. The FiberTape (Arthrex, Naples, FL, USA) suture is used in this case.
- **Anchors:** Device composed of nonabsorbable thermoplastic material, usually polyetheretherketone (PEEK). It is a solid device that fixes the suture tape with tension, providing high tensile strength. In this case, SwiveLock C Anchor 3.5 mm (Arthrex, Naples, FL, USA) is used.



**Fig. 4** Dorsal stabilization provided by the suture tape when performing pronation, tensing it and offering a stop to the pathological subluxation of the distal ulna.



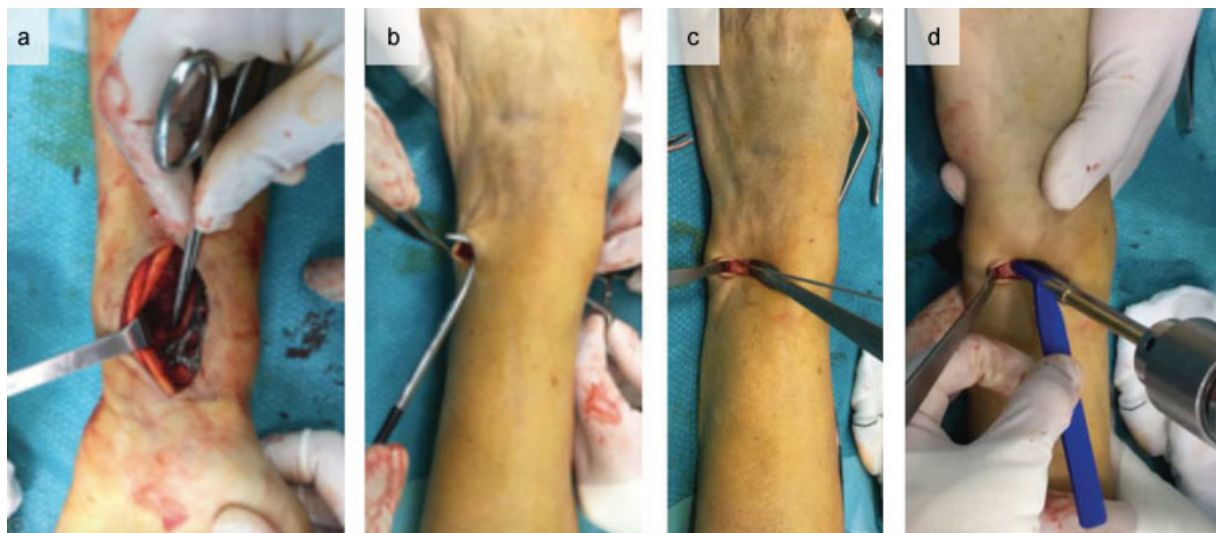
**Fig. 5** Positive ballottement test. The radius is fixed with the forearm in neutral pronation-supination and the distal ulna is displaced in a dorsal and volar direction.

Detailed steps of the surgical procedure (dorsal instability) include the following:

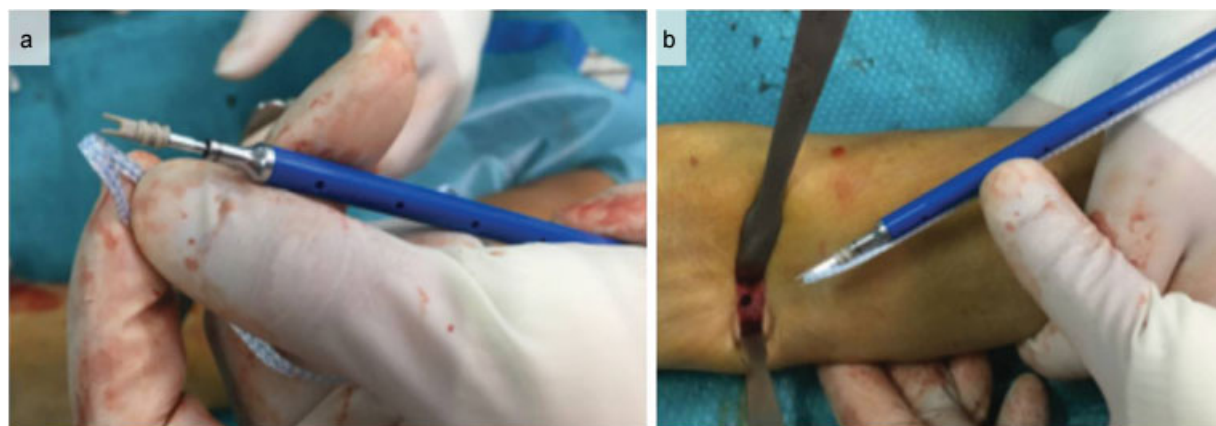
1. Performance of the surgical step corresponding to open reduction (after volar side distal Henry approach or Orbay approach) and osteosynthesis of the distal radius fracture.
2. Assessment of TFCC tear and DRUJ instability and confirmation with a positive ballottement maneuver (► **Fig. 5**).
3. We chose the metaphyseal-diaphyseal region of the radius as the point of origin of the tenodesis and, with a hemostatic or mosquito clamp, tunneling is performed from the radius to the ulna in the volar to dorsal direction, and proximally to distally, crossing the interosseous membrane and directed to the neck of the ulna. This path reproduces the trajectory that the suture tape should follow.
4. The tip of the mosquito marks the incision in the ulnar neck. A mini-open of the sheath of the extensor carpi ulnaris (ECU) is performed, rejecting it to the ulna and preserving the trajectory of the dorsal sensory branch of the ulnar nerve. Then, the anchoring site is prepared with the specific needle and drill (3.5 mm) (► **Fig. 6**). The SwiveLock anchor device holds the FiberTape approximately at the half distance to tunnelize a double thread (► **Fig. 7**).
5. From this region, the tape is recovered using a mosquito and is pushed back through the path previously made up to the metaphysis of the radius (► **Fig. 8**).
6. A second anchoring of the tape is performed through the screw hole of the osteosynthesis plate, closer to the point of origin and placing tension to the tape in maximum supinated position (► **Figs. 9 and 10**).
7. Adequate tension of the anchors and the dorsal stability of the ulna are finally checked (► **Fig. 11**).

## Postoperative Care

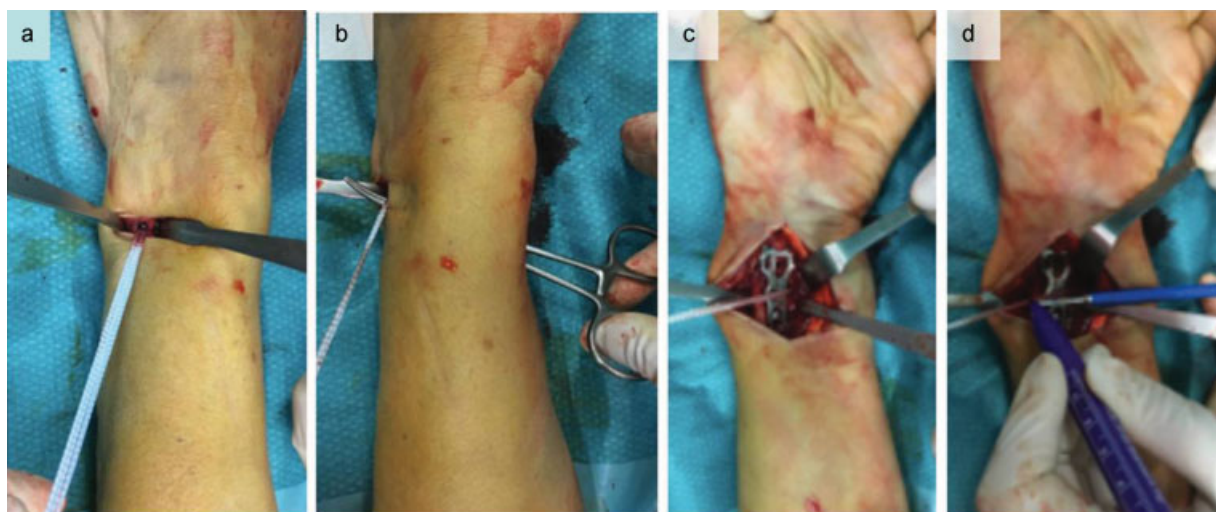
After the surgery, an antebrachial splint is placed in a functional position, with a sling. The patient is discharged from the hospital and scheduled for a control visit within the



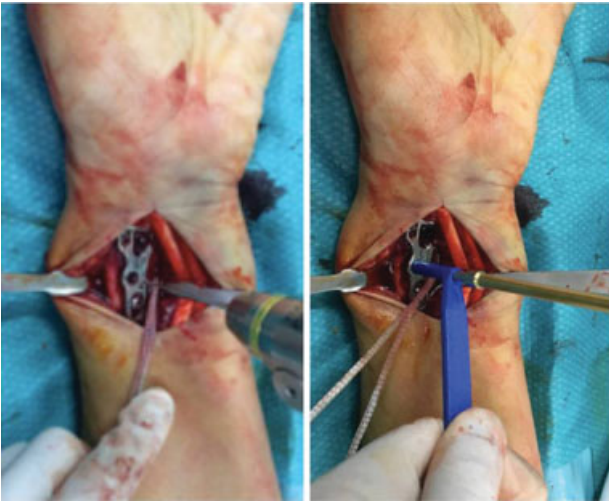
**Fig. 6** (A) Transection of the interosseous membrane with a mosquito clamp dorsally and distally to the ulna; (B) incision in the ulna; (C and D) needle and cannulated drill in the dorsum of the ulna.



**Fig. 7** (A) SwiveLock 3.5 mm device capturing the FiberTape in its approximate half to tunnel with double suture; (B) preparing its insertion in the dorsum of the ulna.



**Fig. 8** (A) The stability of the implant is checked; (B) recovery of the tape through the previous path; c) the anchor point on the plate of the distal radius in the metaphyseal orifice is marked (3.5 mm).



**Fig. 9** Needle and drill for the SwiveLock screw.

first postoperative week, which includes surgical wound care and indication of starting a protocol of active kinesiotherapy at home for the radiocarpal and radioulnar mobility. The patient will wear a removable rigid antebrachial orthosis.

At one month, except in the case of complications, the patient is referred to the rehabilitation service to begin

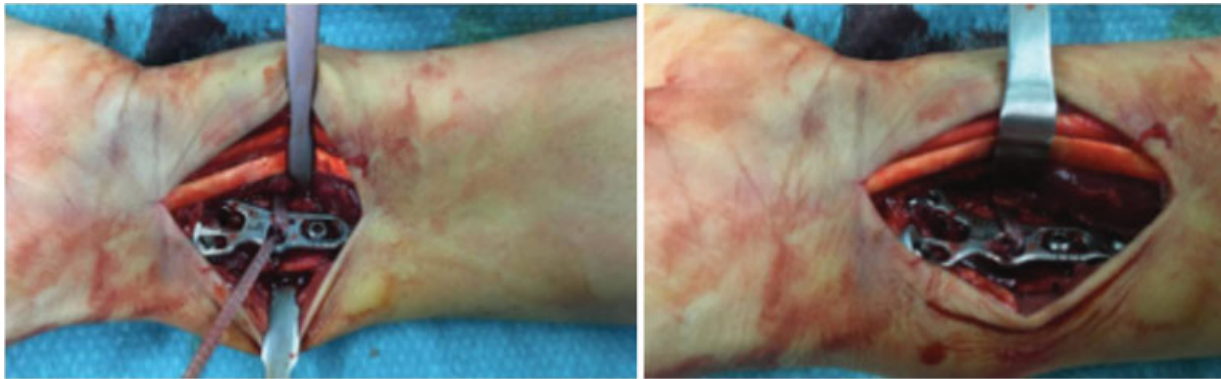physiotherapist-directed rehabilitation exercises. Between 12 and 14 weeks after surgery, if the patient presents pronation/supination limitation due to extreme tension of the tenodesis, he/she is scheduled to cut the FiberTape under local anesthesia and sterile conditions. From this time on, high activity on demand is allowed.

### Complications

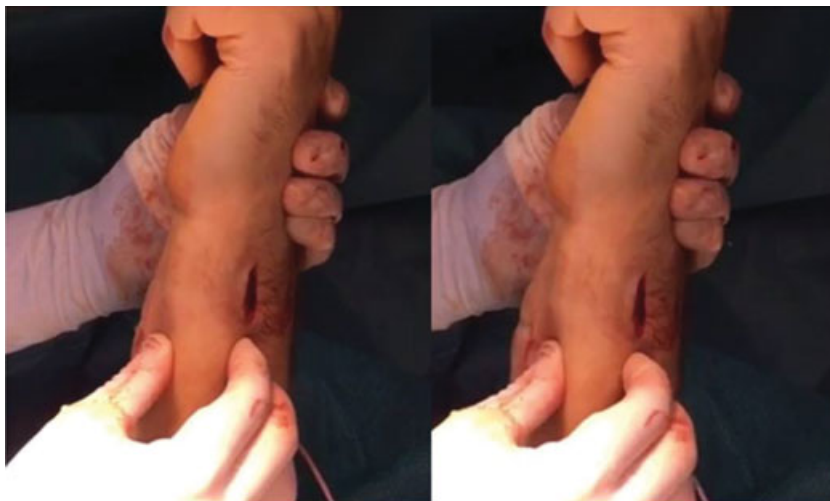The only intraoperative complication was the lack of fixation of the FiberTape to the SwiveLock anchor in the radius. In one case, it was due to the diaphyseal involvement of the fracture and in another case, because of incorrect drilling (3.0 instead of 3.5 mm) of the anchor system. In both cases, suture of the FiberTape over itself through the transosseous tunnels solved the complication.

Potential complications may include:

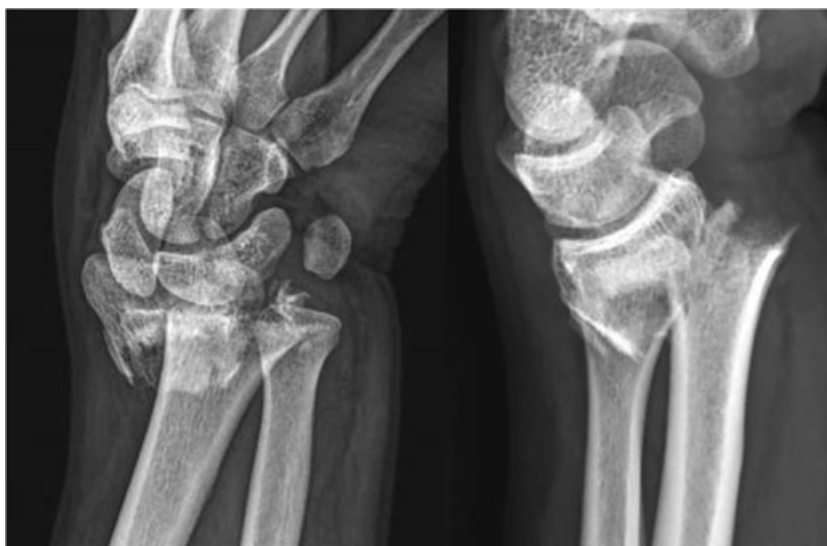- Contractures in pronation or supination if release of the tenodesis is delayed.
- Iatrogenic ulnar neuropathy in the surgical wound in the dorsum of the ulna, which is a complication that is preventable by performing of a correct surgical dissection.
- Fracture of the ulnar neck due to excessive or repeated drilling for ulnar anchoring.



**Fig. 10** Assessment of the implant stability in pronation-supination and cutting of the FiberTape with the scalpel.



**Fig. 11** The stability is confirmed with a negative ballottement maneuver.



**Fig. 12** C3 fracture of the distal radius.

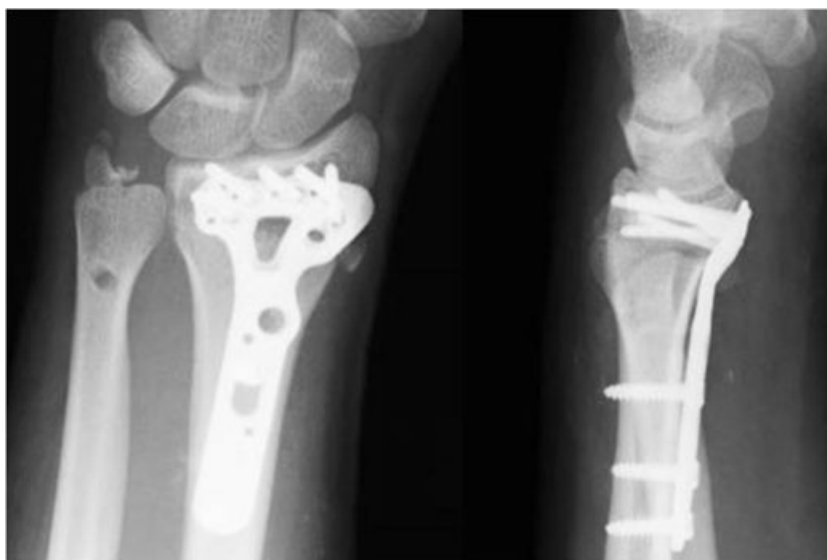### Case Report

A 29-year-old man who presented with a left wrist trauma as a result of a skating accident. The diagnosis of type 3 fracture of the distal radius, or grade VIII according to the Frykman classification, (**Fig. 12**) was made. Surgical treatment was indicated due to the radiological pattern of the fracture. Open reduction of the fracture using a distal Henry approach and osteosynthesis with a volar plate under axillary brachial plexus block was performed. Satisfactory reduction of the fracture was confirmed radiologically (**Fig. 13**).

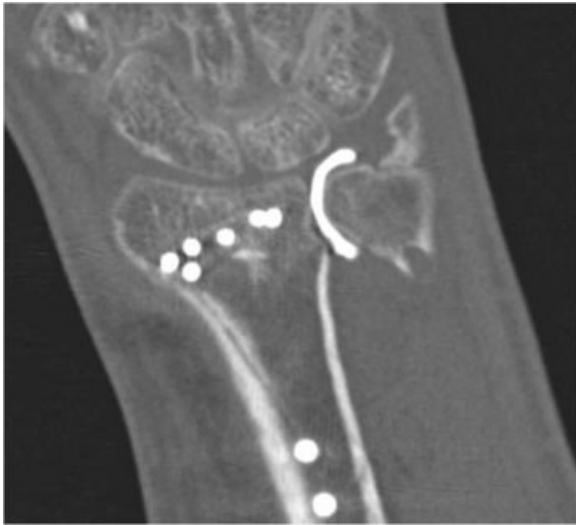
Subsequently, DRUJ instability was confirmed with a positive ballottement maneuver. Using a mosquito clamp, tunneling through the interosseous membrane following a palmar-dorsal and proximal-distal trajectory was performed as described in the aforementioned technique. The SwiveLock

anchor device with the FiberTape was placed on this site, and the FiberTape was returned to the volar aspect of the radius through the trajectory of the mosquito. Another SwiveLock anchor with the other end of the FiberTape was inserted in the metaphyseal orifice of the radius plate, in a position of maximum supination. The remnant of the tape was cut, and the achieved stability was assessed by means of a new ballottement test. The wound of the radius approach was closed in a routine manner, trying to suture the round pronator muscle, and the dorsal mini-incision was closed with skin sutures. An antebrachial splint was placed and, as there were no complications, the patient was discharged from the hospital.

Mobilization with a removable protected orthosis was started at 7 days, and physical rehabilitation exercises at 4 weeks. At 3 months after the surgery, the patient had no pain and showed a complete range of joint mobility in flexo-



**Fig. 13** Radiological control after osteosynthesis and radioulnar stabilization.



**Fig. 14** Image with no leak of contrast on the arthro-computed tomography after complete healing of the triangular fibrocartilage complex.

extension and pronosupination with a weight of 38 kg (only 5 points less than the contralateral). The score of the disabilities of arm, shoulder and hand (DASH) questionnaire was 15. The patient did not have carpal or ulnar symptoms and the distal radioulnar joint was stable as shown by the ballottement test.

Plain radiographs revealed signs of complete consolidation. An arthro-CT, which has shown the same usefulness and reliability as the MRI,<sup>19</sup> confirmed the complete TFCC healing (► **Fig. 14**). The patient requested to resume work activities and removal of the FiberTape was not proposed due to complete mobility and the absence of associated symptoms.

#### Conflicts of Interest

The authors declare that there are no conflicts of interest.

#### References

- Geissler WB, Fernandez DL, Lamey DM. Distal radioulnar joint injuries associated with fractures of the distal radius. *Clin Orthop Relat Res* 1996;(327):135–146
- Gong HS, Cho HE, Kim J, Kim MB, Lee YH, Baek GH. Surgical treatment of acute distal radioulnar joint instability associated with distal radius fractures. *J Hand Surg Eur Vol* 2015;40(08):783–789
- Lindau T, Hagberg L, Adlercreutz C, Jonsson K, Aspenberg P. Distal radioulnar instability is an independent worsening factor in distal radial fractures. *Clin Orthop Relat Res* 2000;(376):229–235
- Lindau T, Adlercreutz C, Aspenberg P. Peripheral tears of the triangular fibrocartilage complex cause distal radioulnar joint instability after distal radial fractures. *J Hand Surg Am* 2000;25(03):464–468
- Fujitani R, Omokawa S, Akahane M, Iida A, Ono H, Tanaka Y. Predictors of distal radioulnar joint instability in distal radius fractures. *J Hand Surg Am* 2011;36(12):1919–1925
- Osada D, Kamei S, Masuzaki K, Takai M, Kameda M, Tamai K. Prospective study of distal radius fractures treated with a volar locking plate system. *J Hand Surg Am* 2008;33(05):691–700
- May MM, Lawton JN, Blazar PE. Ulnar styloid fractures associated with distal radius fractures: incidence and implications for distal radioulnar joint instability. *J Hand Surg Am* 2002;27(06):965–971
- Solgaard S. Function after distal radius fracture. *Acta Orthop Scand* 1988;59(01):39–42
- Stoffelen D, De Smet L, Broos P. The importance of the distal radioulnar joint in distal radial fractures. *J Hand Surg [Br]* 1998;23(04):507–511
- Lindau T. Treatment of injuries to the ulnar side of the wrist occurring with distal radial fractures. *Hand Clin* 2005;21(03):417–425
- Lindau T, Aspenberg P. The radioulnar joint in distal radial fractures. *Acta Orthop Scand* 2002;73(05):579–588
- Kim JP, Park MJ. Assessment of distal radioulnar joint instability after distal radius fracture: comparison of computed tomography and clinical examination results. *J Hand Surg Am* 2008;33(09):1486–1492
- Mrkonjic A, Geijer M, Lindau T, Tägil M. The natural course of traumatic triangular fibrocartilage complex tears in distal radial fractures: a 13–15 year follow-up of arthroscopically diagnosed but untreated injuries. *J Hand Surg Am* 2012;37(08):1555–1560
- Lee SK, Kim KJ, Cha YH, Choy WS. Conservative treatment is sufficient for acute distal radioulnar joint instability with distal radius fracture. *Ann Plast Surg* 2016;77(03):297–304
- Ruch DS, Yang CC, Smith BP. Results of acute arthroscopically repaired triangular fibrocartilage complex injuries associated with intra-articular distal radius fractures. *Arthroscopy* 2003;19(05):511–516
- Trumble TE, Gilbert M, Vedder N. Arthroscopic repair of the triangular fibrocartilage complex. *Arthroscopy* 1996;12(05):588–597
- Buijze GA, Ring D. Clinical impact of United versus nonunited fractures of the proximal half of the ulnar styloid following volar plate fixation of the distal radius. *J Hand Surg Am* 2010;35(02):223–227
- Lawler E, Adams BD. Reconstruction for DRUJ instability. *Hand (NY)* 2007;2(03):123–126
- Lee RK, Ng AW, Tong CS, et al. Intrinsic ligament and triangular fibrocartilage complex tears of the wrist: comparison of MDCT arthrography, conventional 3-T MRI, and MR arthrography. *Skeletal Radiol* 2013;42(09):1277–1285