

Slow Elevation in Protein C Activity without a *PROC* Mutation in a Neonate with Intracranial Hemorrhage

Erika Uehara, MD¹ Hiro Nakao, MD^{1,2} Yusuke Tsumura, MD¹ Hisaya Nakadate, MD, PhD^{2,3}
 Shoichiro Amari, MD⁴ Hideshi Fujinaga, MD, PhD⁴ Yoshiyuki Tsutsumi, MD, PhD⁵
 Dongchon Kang, MD, PhD⁶ Shouichi Ohga, MD, PhD⁷ Akira Ishiguro, MD, PhD^{1,3}

¹Department of Postgraduate Education and Training, National Center for Child Health and Development, Tokyo, Japan

²Department of General Pediatrics and Interdisciplinary Medicine, National Center for Child Health and Development, Tokyo, Japan

³Division of Hematology, National Center for Child Health and Development, Tokyo, Japan

⁴Division of Neonatology, National Center for Child Health and Development, Tokyo, Japan

⁵Department of Radiology, National Center for Child Health and Development, Tokyo, Japan

⁶Department of Clinical Chemistry, Graduate School of Medical Sciences, Kyushu University, Fukuoka, Japan

⁷Department of Pediatrics, Graduate School of Medical Sciences, Kyushu University, Fukuoka, Japan

Address for correspondence Erika Uehara, MD, Department of Postgraduate Education and Training, National Center for Child Health and Development, 2-10-1 Okura, Setagaya-ku, Tokyo, Japan (e-mail: uehara-e@ncchd.go.jp).

Am J Perinatol Rep 2018;8:e68–e70.

Abstract

Severe protein C (PC) deficiency leads to purpura fulminans and stroke in newborns. However, the clinical impact of plasma PC activity on the development of neonatal cerebral disease remains elusive. We report a case of hemorrhagic stroke associated with neonatal asphyxia and severe PC deficiency. Plasma PC and protein S activity 7 days after birth was 12% and 43%, respectively. No *PROC* mutation was found. PC levels did not exceed 20% until 2 months of age, even in the absence of consumption coagulopathy or vitamin K deficiency. Neither thromboembolic nor hemorrhagic events occurred during the infusion of activated PC concentrate (twice weekly, up to 68 days after birth). The PC activity levels gradually increased to the standard value for age by 9 months of age. The present case showed that neonatal PC deficiency without a *PROC* mutation caused an intracranial hemorrhage before a slow increase in PC activity.

Keywords

- ▶ neonatal stroke
- ▶ hemorrhagic infarction
- ▶ protein C deficiency
- ▶ *PROC* mutation

Protein C (PC) is an anticoagulant factor synthesized in hepatocytes. Activated PC, augmented by protein S (PS), inhibits coagulation factors Va and VIIIa. PC deficiency leads to thromboembolic events; however, in neonates it often causes purpura fulminans and intracranial hemorrhage.¹

Neonatal PC deficiency can be divided into the inherited and noninherited types. The inherited type is caused by mutations in the protein C gene (*PROC*). However, the clinical impact of plasma PC activity on the development of neonatal cerebral disease remains elusive. Little is known about the

cause and presentation of neonatal noninherited PC deficiency.² The present case showed that neonatal PC deficiency without a *PROC* mutation was associated with hemorrhagic stroke before a slow increase in PC activity.

Case Report

A male infant weighing 2,216 g was born by cesarean section at 36 weeks of gestation due to a previous cesarean section and early labor pains. Fetal growth was normal, and the

received
 November 17, 2017
 accepted after revision
 February 12, 2018

DOI <https://doi.org/10.1055/s-0038-1639614>.
 ISSN 2157-6998.

Copyright © 2018 by Thieme Medical Publishers, Inc., 333 Seventh Avenue, New York, NY 10001, USA.
 Tel: +1(212) 584-4662.

License terms



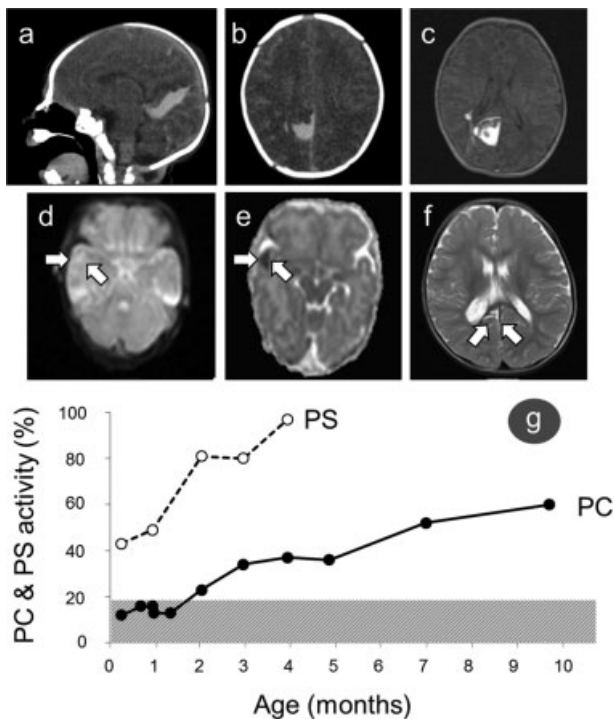


Fig. 1 Intracranial hemorrhage in computed tomograms at 1 day old (A, B) and T1-weighted magnetic resonance imaging at 9 days old (C). A cerebral infarction in diffusion-weighted magnetic resonance imaging (D) and apparent diffusion coefficient map at 9 days old (E). Follow-up T2-weighted magnetic resonance imaging at 18 months old (F) shows no new intracranial embolism or hemorrhage (G) Dissociation between changes in protein C (PC) and protein S (PS) activity. Closed circles and solid lines indicate PC activity; open circles and dotted lines indicate PS activity. PC activity increased slowly compared with the increase in PS activity.

placenta revealed no thromboembolic obstructions. There was no family history of blood coagulation disorder. The patient showed an Apgar score of 2, 4, and 7 at 1, 5, and 10 minutes, respectively.

A subarachnoid hemorrhage, subdural hematoma, and cerebral hemorrhage were found, and ischemic encephalopathy was disclosed by ultrasound and computed tomography at age 1 day. His blood test revealed leukocytes $20.34 \times 10^9/L$, hemoglobin 189 g/L, platelets $216 \times 10^9/L$, fibrinogen 1.05 g/L, prothrombin time-international normalized ratio (PT-INR) 1.2, activated partial thromboplastin time (aPTT) 85.6 second, antithrombin activity 37.1%, and D-dimer 27.4 $\mu\text{g/mL}$. The serum creatinine, alanine aminotransferase, and C-reactive protein were normal. A sepsis workup showed sterile culture results for the blood and gastric juice at birth. We infused fresh frozen plasma for 3 days.

At age of 7 days, a coagulation study revealed PC activity at 12% ($44\% \pm 80\%$ at 5 days old and $51\% \pm 16\%$ at 1 month old in reference neonates³), PS activity at 43% ($38\% \pm 14\%$ at 5 to 7 days old in reference neonates³), aPTT 67.4 second, and PT-INR 1.13 (\rightarrow Fig. 1). PC and PS activities were assessed by the coagulation method (Instrumentation Laboratory, MA). At 9 days old, magnetic resonance imaging visualized an intra-

cranial hemorrhage and multiple peripheral infarctions. Vitamin K 2 mg was given intravenously at 1 and 5 days old, and orally at 30 days old. A direct sequencing of the coding and promoter regions of *PROC* revealed no mutation at 1 month of age.¹ There were no further hemorrhagic or thromboembolic events. PC activity slowly increased to adult levels (60%) by 9 months of age without any thromboembolic events. He learned to roll over at 6 months old, to stand while holding on to objects at 13 months old, and to walk along a wall at 14 months old. A follow-up magnetic resonance imaging at 18 months old showed no new intracranial embolism or hemorrhage.

Discussion

The present case of neonatal PC deficiency with an intracranial hemorrhage is remarkable because it illustrates the pathophysiology of the disease without a *PROC* mutation. PC levels in healthy term infants are $\sim 30\%$ to 40% at age 5 days and $\sim 40\%$ to 50% at age 1 month.³ Levels reach the adult range at about age 6 to 9 months. Manco-Johnson et al showed that the PC activity in some infants increased from a very low level to a normal level, and that some of the infants suffered from thromboembolic events. They also reported that low PC levels occurred most frequently in preterm infants with respiratory distress and infants from twin gestations.⁴ The PC deficiency which occurred in these patients might also occur in stressed neonates like our patient.

There are a few case reports of neonatal noninherited PC-deficient patients born to healthy parents, having normal PC activity, and showing a presentation similar to that of neonates with a *PROC* mutation.² Two of seven Japanese PC-deficient patients who underwent the *PROC* gene test had no mutation.¹ As in our case and a previous case without a *PROC* mutation,⁵ low PC activity during the early infantile period increased more slowly than the PS activity.

In conclusion, our case of neonatal PC deficiency without a *PROC* mutation demonstrated an intracranial hemorrhage and slowly increasing PC activity. Further studies are needed to clarify the pathomechanism of neonatal transient PC deficiency.

Statement of Ethics

The institutional review board of our hospital approved this investigation. Informed consent was obtained from the caretakers for publication of this case report and accompanying images.

Conflict of Interest

None.

Acknowledgments

This work was supported by grants-in-aid (17929467) (S.O.) from the Japan Agency for Medical Research and Development (AMED), the Research on Measures for Intractable Diseases Project, and the Health and Labor Sciences Research grant (Research on Intractable Diseases) of the Ministry of Health, Labor and Welfare.

References

- 1 Ohga S, Kang D, Kinjo T, et al. Paediatric presentation and outcome of congenital protein C deficiency in Japan. *Haemophilia* 2013;19(03):378–384
- 2 Ohga S, Ishiguro A, Takahashi Y, et al; Japan Childhood Thrombophilia Study Group. Protein C deficiency as the major cause of thrombophilias in childhood. *Pediatr Int* 2013;55(03):267–271
- 3 Takahashi Y, Yoshioka A. Hemostasis and its regulation system in childhood. *Jpn J Pediatr Hematol* 1994;8:389–397
- 4 Manco-Johnson MJ, Abshire TC, Jacobson LJ, Marlar RA. Severe neonatal protein C deficiency: prevalence and thrombotic risk. *J Pediatr* 1991;119(05):793–798
- 5 Matsunaga Y, Ohga S, Kinjo T, et al. Neonatal asphyxia and renal failure as the presentation of non-inherited protein C deficiency. *J Perinatol* 2013;33(03):239–241