

Staged Surgical Palliation for HLHS in a Girl with Severe Factor X Deficiency

Ahmed F. Elmahrouk^{1,2} Mohamed F. Ismail^{1,3} Abdulbadee Bugis¹ Nashwa Badawy^{1,4}
Hesham Mohamed Aboelghar^{5,6} Tamer Hamouda^{1,7} Ahmed Jamjoom¹

¹Department of Cardiothoracic Surgery, King Faisal Specialist Hospital and Research Centre, Jeddah, Saudi Arabia

²Department of Cardiothoracic Surgery, Tanta University Faculty of Medicine, Tanta, Egypt

³Mansoura University Faculty of Medicine, Mansoura, Egypt

⁴Cairo University Kasr Alainy Faculty of Medicine, Cairo, Egypt

⁵Department of Pediatrics, Menoufia University Faculty of Medicine, Shebin El-Kom, Saudi Arabia

⁶Department of Hematology and Oncology BMT, King Faisal Specialist Hospital and Research Centre, Jeddah, Saudi Arabia

⁷Department of Cardiothoracic Surgery, Faculty of Medicine, Benha University, Benha, Egypt

Address for correspondence Ahmed F. Elmahrouk, MD, CTS, Department of Cardiothoracic Surgery, King Faisal Specialist Hospital and Research Centre, P. O. Box 40047 MBC J-16, Jeddah 21499, Saudi Arabia
(e-mail: a_marouky@hotmail.com; ael-mahrouk@kfshrc.edu.sa).

Thorac Cardiovasc Surg Rep 2018;7:e12–e15.

Abstract

Keywords

- ▶ factor X deficiency
- ▶ hypoplastic left heart syndrome
- ▶ Norwood procedure
- ▶ superior cavopulmonary anastomosis
- ▶ total cavopulmonary connection

Background Factor X deficiency (also known as Stuart–Prower factor deficiency) is an autosomal recessive extremely rare hereditary hematologic disorder, affecting around 1:1,000,000 of the general population.

Case Presentation This case report describes a patient with hypoplastic left heart syndrome and severe factor X deficiency, who underwent staged surgical palliation. From stage 1 Norwood palliation, through superior cavopulmonary anastomosis and ending with total cavopulmonary connection with satisfactory hemostasis and no significant perioperative bleeding complication.

Conclusion The need to maintain hemostasis while aiming to prevent intracardiac thrombosis requires multidisciplinary team approach including hematologist, cardiac surgeon, pediatric cardiac intensivist, and anesthesiologist along with meticulous hemostasis during surgery and careful monitoring of coagulation profile in the post-operative period.

Introduction

Factor X (FX) is a vitamin K-dependent clotting factor synthesized in the liver and found in plasma at a concentration of ~1 mg/dL. It plays an important role in the coagulation cascade system.¹

FX deficiency (also known as Stuart–Prower factor deficiency) is an autosomal recessive extremely rare hereditary hematologic disorder, affecting around 1:1,000,000 of the general population. Affected individuals commonly present with bleeding disorders that varies from easy bruising, bleed-

ing from mucous membranes up to spontaneous internal or external bleeding (hemarthrosis or hemorrhagic strokes) in patients with marked deficiency.¹

As with all bleeding disorders, FX deficiency may present significant difficulties in managing and maintaining hemostasis in surgery. Previous guidelines have described the use of different plasma products including fresh-frozen plasma (FFP), prothrombin complex concentrates (PCCs), and factor IX-X concentrate as a treatment and prophylaxis to control bleeding complication perioperatively. Recently, human plasma-derived

received
November 12, 2017
accepted after revision
January 25, 2018

DOI <https://doi.org/10.1055/s-0038-1637743>
ISSN 2194-7635.

© 2018 Georg Thieme Verlag KG
Stuttgart · New York

License terms



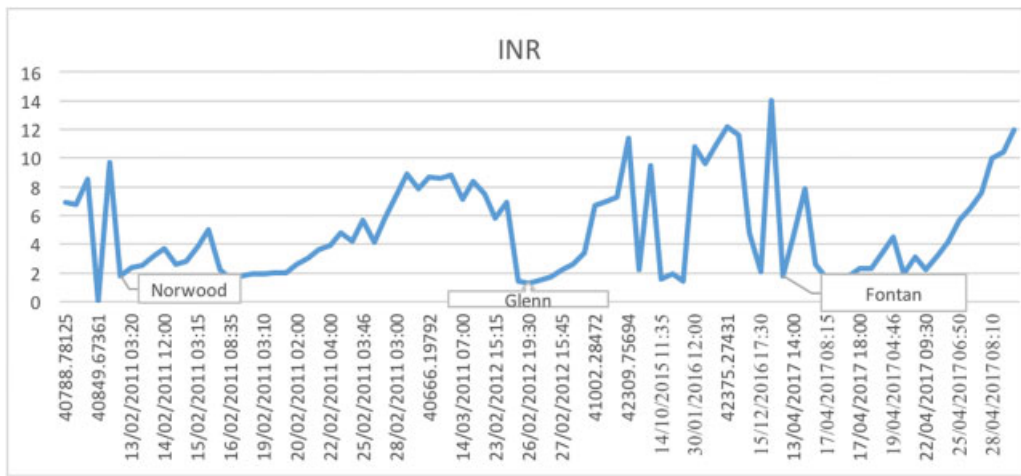


Fig. 1 A graph of the timeline for international normalized ratio [INR] measurements showing derangement, with returning near normal values after treatment at the time of surgeries.

FX concentrate has been approved for treatment of perioperative bleeding in affected patients.

This case report describes a patient with hypoplastic left heart syndrome (HLHS) and severe FX deficiency, who underwent staged surgical palliation, from stage 1 Norwood palliation, through superior cavopulmonary anastomosis and ending with total cavopulmonary connection (TCPC) with satisfactory hemostasis and no significant perioperative bleeding complication.

Case Report

A 6-year-old female with a history of HLHS diagnosed by echo at day 1 after birth that showed mitral atresia, rudimentary left ventricle, hypoplastic aortic arch, patent ductus arteriosus (PDA), and atrial septal defect (ASD). After initial diagnosis at birth, patient was started on prostaglandin and dobutamine and transferred to our center for further management.

During the routine preoperative workup, she was found to have prolonged prothrombin time (PT) and activated partial thromboplastin time (aPTT) (→ Figs. 1 and 2). Mixing study was performed by addition of normal pooled plasma to patient's

plasma, and it showed normalization of both the prolonged PT and aPTT; which indicated clotting factor deficiency (factors II, V, or X) that was corrected by addition of normal plasma. The respective clotting factors assays were performed, factor II and factor V were found within normal range for age (0.78 and 0.9 IU/mL, respectively). On the other hand, FX, was found to have severe deficiency with plasma FX level < 0.01 IU/mL, and FX functional activity (FX:C) was > 1%.

A structured plan was discussed with the hematologist for FX replacement therapy (one dose of FX concentrate [50 IU/kg] the day before the surgery and 1 hour prior to any future surgical intervention to reach an international normalized ratio [INR] level of < 1.5).¹ If the target preoperative INR was not achieved, an extra dose of FX concentrate is given. This is followed by daily 30 IU/kg of FX concentrate after surgery together with 10 mg/kg tranexamic acid four times a day for a period of 5 to 7 days to eliminate the risk of perioperative bleeding. She successfully underwent Norwood I procedure (Damus–Kaye–Stansel (DKS), modified Blalock–Taussig shunt (mBTS), aortic arch augmentation, and atrial septectomy) at the age of 7 weeks and was discharged home in stable condition.

At the age of 14 months, she was admitted for right superior cavopulmonary anastomosis (Glenn procedure).

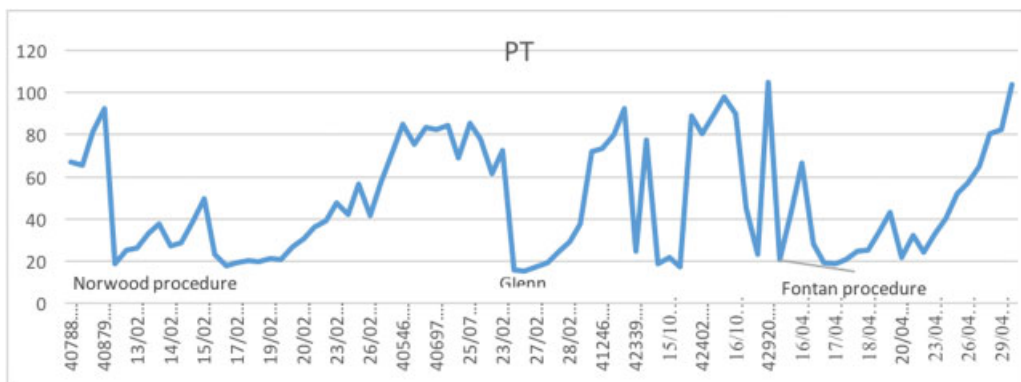


Fig. 2 A graph of the timeline for prothrombin time (PT) measurements showing derangement, with returning near normal values after treatment at the time of surgeries.

She received two doses of 50 IU/kg FX (Factor X P Behring) (one dose of FX concentrate [50 IU/kg] the day before the surgery and another dose was given 1 hour prior to surgery). This was followed by daily 30 IU/kg for 5 days after the surgery. Our patient had an uneventful hospital course and was discharged in stable condition.

At the age of 3 years, she had an episode of seizure that was described as partial loss of consciousness with generalized stiffening of the body and trembling of the jaw. This episode happened intermittently over a period of 20 minutes. A computed tomography (CT) scan and magnetic resonance imaging (MRI) of the brain showed no intracranial hemorrhage or infarction, but electroencephalogram (EEG) showed mild and intermittent background generalized slowing. The patient was started on antiepileptic medication (levetiracetam).

She maintained her usual state of health with no signs of bleeding and continued to follow up with pediatric cardiology. However, she experienced a recent episode of hemoptysis following upper respiratory tract infection (URTI) at the age of 5 years. The patient was admitted in another facility and treated with plasma transfusions.

Follow-up echocardiography showed patent right superior cavopulmonary anastomosis and DKS anastomosis, patent aortic arch, and large nonrestrictive ASD. Patient was planned for elective TCPC.

Dental clearance was done after undergoing multiple teeth extraction, restoration, and fillings. All were done in one session under general anesthesia after following the same FX preoperative replacement protocol. We did not give daily postoperative doses, as the patient underwent stage 3 palliation during the same admission.

Finally, at the age of 6 years, the patient underwent extra cardiac nonfenestrated TCPC, again following the same FX replacement protocol. However, due to the limited supply of FX concentrate, we accepted a preoperative INR value of 1.8.

The patient tolerated the procedure well with minimal intraoperative bleeding and she was maintained on FX concentrates daily and 150 mg tranexamic acid four times a day for 1 week postoperatively.

Postoperative echo showed patent TCPC circuit, confluent branch pulmonary arteries and patent DKS anastomosis, patent aortic arch with good overall ventricular systolic function, and no pericardial effusion. Patient had smooth uneventful postoperative course and was discharged in a stable condition.

In all of her surgical procedures, there was no noticeable perioperative bleeding or thromboembolic event related to coagulopathy or treatment administration.

Discussion

FX is a vitamin K-dependent enzyme that has an essential and unique position in the coagulation cascade. It is the first enzyme in the common pathway of thrombus formation.²

In case of derangement and prolongation of both PT and aPTT, mixing study (mixing 1:1 with normal plasma) is performed. Clotting factors deficiencies are suspected if mixing study shows normalization unless an inhibitor is present. Normalized prolonged aPTT by mixing studies indicates factors

VIII, XII, IX, or XI deficiency, while PT normalization indicates factor VII deficiency. When both prolonged aPTT and PT are normalized by mixing study, factors II, V, or X deficiencies are suspected. FX functional activity (FX:C) is quantified by performing serial dilutions with FX-deficient plasma.

The diagnosis of clotting factors deficiencies is confirmed by performing the respective clotting factors assays. FX level is low at birth and gradually increases to reach normal level by 6 months of age. For that reason, age-related ranges for FX are essential if a deficiency is suspected. It is also important to exclude vitamin K deficiency or other acquired causes of a clotting disorder before the diagnosis of FX deficiency is made.^{2,3}

In contrast to other coagulation factor deficiencies, the most frequent bleeding symptoms are mucocutaneous: easy bruising, epistaxis, and gingival bleeding. Affected individuals may present with bleeding disorders at any age, and the timing and the presentation of FX deficiency is related to the level of FX. FX activity measurement < 10% (< 1 IU/mL) is described as severe deficiency. It can present early in neonates as bleeding of umbilical stump in 28% of patients (usually when the stump falls off at 7–14 days). Recurrent hemarthrosis was found in 69% of patients with the development of hemophilic arthropathy. Intracranial hemorrhage was also reported in 9 to 26% of patients.

On the other hand, moderately affected patients with FX activity measurement of 10 to 40% (1–5 IU/mL) may experience bleeding only after trauma or surgery, and patients with mild form of FX deficiency (FX: activity > 40–60% [6–10 IU/mL]) can remain asymptomatic and get diagnosed incidentally on routine screening or because of a positive family history.^{3,4}

Although our patient has severe FX deficiency, she was discovered to have the disease on routine perioperative coagulation profile, and the only bleeding episode she experienced was hemoptysis after URTI at the age of 5 years.

These findings were in accordance with Thompson et al,⁵ who reviewed 60 patients with isolated acquired FX deficiency ($\leq 50\%$), who underwent a total of 112 invasive procedures over 30 years. They found infrequent complications with mild or moderate FX deficiency undergoing non-vascular procedures; however, baseline FX level was not predictive of bleeding risk. They concluded that there is no consensus on the correlation of bleeding risk with degree of FX deficiency.

FX deficiency is an extremely rare condition with limited information on the outcome and perioperative management in severe deficiency. There was a lack of reliable and evidence-based guidelines for its management, until the United Kingdom Hemophilia Centre Doctors' Organization (UKHEDO) published guidelines for management of FX deficiency beside other rare coagulation disorders relying on available literature and extensive clinical experience.³

Maintaining adequate hemostasis during surgery is challenging for rare hereditary bleeding disorders, particularly, when multicoagulation-factor concentrates are the only available therapeutic option.

Although FX is a vitamin K-dependent factor, vitamin K has no therapeutic effect on FX in patients with a congenital deficiency.

Current therapeutic options to manage patients with FX deficiency include fibrinolytic inhibitors, plasma, and intermediate-purity factor IX concentrates (PCCs). Similarly, recombinant human coagulation factor VIIa has been used successfully. Tranexamic acid also has been suggested particularly for mucosal bleeding and menorrhagia in a dose of 15 mg/kg, 8 hourly (in practice 1 g, 6–8 hourly).^{2,6}

Replacement therapy has been reserved for particular hemorrhagic episode or anticipated ones. FX levels of 10 to 20 IU/mL were proposed to be generally sufficient for hemostasis during surgery and in the immediate postoperative period. Since the biological half-life of FX is 20 to 40 hours, an adequate level can be achieved with repeated infusions.^{3,6}

It has been described that TCPC procedure has an associated risk of postoperative hypercoagulability that may predispose to intracardiac thrombus formation and subsequently contribute to mortality and morbidity after TCPC procedure.

There is no clear consensus in regard to prophylactic anticoagulation or antiplatelet therapy after TCPC. Although the majority of retrospective studies have advocated the use of lifelong anticoagulation and antiplatelet in all patients after TCPC, the efficacy of this recommendation is yet to be determined, since there is a lack of prospective data showing long-term follow-up.

In our case, blood coagulation has been optimized prior to TCPC surgery and continuously assessed in the postoperative period. Once surgical drains were removed and an echocardiography ruled out pericardial collection, we stopped following blood coagulation. Unlike our routine for patient post-TCPC, neither antiplatelet nor anticoagulation therapy was needed.

To the best of our knowledge, this is the first report to document staged surgical palliation in a patient with HLHS and severe FX deficiency. This child successfully underwent three major cardiac procedures with cardiopulmonary bypass and

one dental procedure with multiple teeth extraction, restoration, and fillings.

Conclusion

Staged surgical palliation for HLHS patients, who have bleeding disorders can be challenging during the perioperative period. TCPC operation is associated with postoperative risk of thrombosis that requires anticoagulation prophylaxis. The need to maintain hemostasis while aiming to prevent intracardiac thrombosis requires multidisciplinary team approach including hematologist, cardiac surgeon, pediatric cardiac intensivist, and anesthesiologist along with meticulous hemostasis during surgery and careful monitoring of coagulation profile in the postoperative period.

References

- 1 Horlocker TT, Wedel DJ, Rowlingson JC, et al. Regional anesthesia in the patient receiving antithrombotic or thrombolytic therapy: American Society of Regional Anesthesia and Pain Medicine Evidence-Based Guidelines (3rd ed.). *Reg Anesth Pain Med* 2010;35(01):64–101
- 2 Brown DL, Kouides PA. Diagnosis and treatment of inherited factor X deficiency. *Haemophilia* 2008;14(06):1176–1182
- 3 Bolton-Maggs PHB, Perry DJ, Chalmers EA, et al. The rare coagulation disorders—review with guidelines for management from the United Kingdom Haemophilia Centre Doctors' Organisation. *Haemophilia* 2004;10(05):593–628
- 4 Peyvandi F, Mannucci PM, Lak M, et al. Congenital factor X deficiency: spectrum of bleeding symptoms in 32 Iranian patients. *Br J Haematol* 1998;102(02):626–628
- 5 Thompson CA, Kyle R, Gertz M, Heit J, Pruthi R, Pardanani A. Systemic AL amyloidosis with acquired factor X deficiency: a study of perioperative bleeding risk and treatment outcomes in 60 patients. *Am J Hematol* 2010;85(03):171–173
- 6 Knight RD, Barr CF, Alving BM. Replacement therapy for congenital factor X deficiency. *Transfusion* 1985;25(01):78–80