

# Transposition of Great Arteries with Left Main Coronary Artery Atresia—Case Report

Ahmed F. Elmahrouk<sup>1,2</sup> Tamer Hamouda<sup>1,3</sup> Mohamed F. Ismail<sup>1,4</sup> Ahmed Jamjoom<sup>1</sup>

<sup>1</sup>Department of Cardiothoracic Surgery, King Faisal Specialist Hospital and Research Centre, Jeddah, Saudi Arabia

<sup>2</sup>Department of Cardiothoracic Surgery, Tanta University Faculty of Medicine, Tanta, Egypt

<sup>3</sup>Department of Cardiothoracic Surgery, Faculty of Medicine, Benha University, Benha, Egypt

<sup>4</sup>Department of Cardiothoracic Surgery, Faculty of Medicine, Mansoura University, Mansoura, Egypt

Address for correspondence Ahmed F. Elmahrouk, MD, CTS, Department of Cardiothoracic Surgery, King Faisal Specialist Hospital and Research Centre, P. O. Box 40047, MBC J-16, Jeddah 21499, Saudi Arabia (e-mail: a\_marouky@hotmail.com; ael-mahrouk@kfsfhr.edu.sa).

Thorac Cardiovasc Surg Rep 2018;7:e16–e17.

## Abstract

### Keywords

- ▶ transposition of great arteries
- ▶ congenital heart surgery
- ▶ arterial switch operation
- ▶ congenital coronary anomaly

**Background** The coronary artery anatomy in patients with transposition of the great artery (TGA) is a contributing factor for outcome in arterial switch procedure.

**Case Presentation** A full-term, 7-day-old baby boy diagnosed as dextro-TGA (dTGA) with intact ventricular septum. Intraoperatively, the left coronary sinus had a blind indentation from which a firm cord-like left main coronary artery originates. Procedure completed as usual for a routine arterial switch operation.

**Conclusion** About 5% of patients with D-TGA have a single coronary artery. Assessment of blood flow to all branches intraoperatively is mandatory to choose between either transfer of single ostium or bypass grafting to the other coronary system.

## Introduction

The coronary artery anatomy in patients with transposition of the great arteries (TGAs) is a contributing factor for outcome in arterial switch operation (ASO). However, abnormal coronary arterial pattern does not impede ASO to be done successfully, although patients with a single coronary artery, or other abnormal arterial patterns, had a slightly longer hospital course.<sup>1</sup>

The identification of coronary anatomy prior to surgery is of utmost importance for surgical outcome. Based on relatively small surgical, pathological, or echocardiographic series, several classifications of coronary anatomy in TGA had been described.<sup>2–5</sup>

In 1986, Quaegenbeur developed an alphanumeric classification, widely known as Leiden Convention. Standing on the side of the nonfacing sinus and facing the pulmonary trunk, the right-side sinus was named sinus 1 and on the left

side sinus 2. The coronary artery pattern was described in a simple system taking into account the origin of the right coronary artery (RCA; R), the circumflex (Cx), and the left anterior descending (LAD; L).<sup>6</sup>

The six main coronary artery patterns in TGA as described by some investigators were 4 with dual sinus origin of the coronary arteries from the facing sinuses. In the two remaining patterns, there is a single origin from either sinus 1 or sinus 2 (▶ **Table 1**).<sup>2–5</sup>

## Case Report

In this report, we describe a full-term 7-day-old baby boy, weighing 3.7 kg, diagnosed as dextro-TGA (dTGA) with intact ventricular septum, and small atrial septal defect and patent ductus arteriosus. He was complaining of cyanotic, tachypnea, and failure of latching on or sucking. The Appearance, Pulse, Grimace, Activity, and Respiration (APGAR) score was

received  
November 12, 2017  
accepted after revision  
February 5, 2018

DOI <https://doi.org/10.1055/s-0038-1637737>.  
ISSN 2194-7635.

© 2018 Georg Thieme Verlag KG  
Stuttgart · New York

License terms



**Table 1** The six main coronary artery patterns in TGA and their incidence in literatures

Type A:	1LCx-2R (70–74%)	Type D:	1RL-2Cx (2–6%)
Type B:	1L-2CxR (10–12%)	Type E:	2LCxR (5–6%)
Type C:	1R-2LCx (1–2%)	Type F:	1LCxR (2%)

Abbreviation: TGA, transposition of the great artery.

8, he was presented to our hospital on prostaglandin E and oxygen saturation was 70 to 80%, and was stable otherwise. Preoperative echocardiographic data did not describe coronary arterial anatomy.

ASO was planned as usual. Cross-clamp was applied, cardioplegia was given, and ascending aorta and pulmonary trunk were transected. Coronary anatomy identified and assessed.

A unique congenital coronary finding was identified. The RCA was originating normally from the right coronary sinus; however, the left coronary sinus had a blind indentation from which a firm cord-like left main coronary artery was originating and continued for ~2 cm in its ordinary course then branched to normal LAD and left Cx (LCx) arteries (► Fig. 1). The LAD and LCx apparently fill in a retrograde fashion from the right coronary system when cardioplegia was given directly to the ostium of the RCA.

The right coronary ostium was the only coronary transferred. Procedure was completed as usual for a routine ASO. Cross-clamp time was 93 minutes, pump time was 121 minutes, and lowest core temperature was 24°C. Postrepair epicardial echocardiography showed good overall left and right systolic function. Patient was transferred to the intensive care unit with an open chest that was closed after 24 hours with stable hemodynamics.

## Discussion

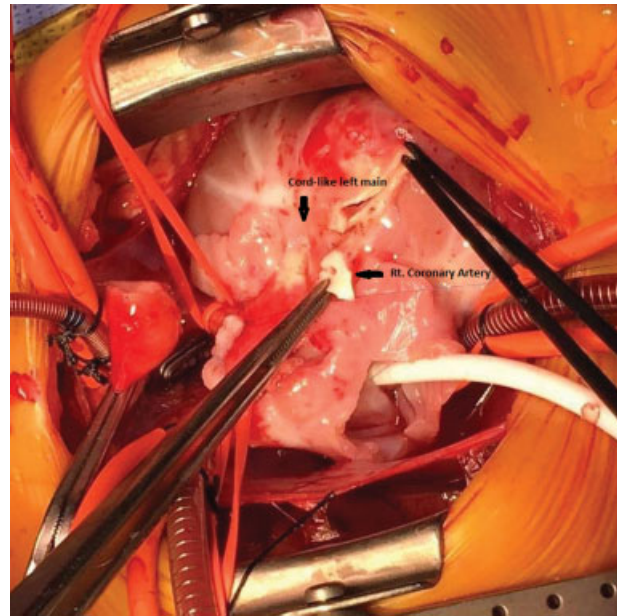
Patient is now 1-year-old, doing well with normal echocardiographic finding. No complications related to single coronary artery was reported in our case.

We reviewed more than 270 literatures through PubMed database about TGA and associated coronary anomalies, but no one reported blind left sinus with left main atresia giving LAD and LCx branches.

Two primary anatomic subcategories were described:

- The origin of the abnormal coronary artery from the opposite aortic sinus (facing sinus).
- Anomalous coronary artery originates from the pulmonary artery. Diagnosis and management of such patterns continue to be challenging.

Certain coronary patterns are associated with adverse outcomes. A single coronary ostium was associated with an increased risk of mortality. This is believed to be due to kinking or stretching of the myocardial sole blood supply during transfer.<sup>4</sup> On the other hand, intramural coronary



**Fig. 1** Intraoperative view showing the cord-shaped left main (arrow), the right coronary ostium (pickup holding).

artery have shown the worst results among all patterns, this was attributed to the increased risk of damage and technical difficulties with the vessel transfer.<sup>4</sup>

## Conclusion

About 5% of patients with dTGA have a single coronary artery, and it is fundamental to identify coronary in those patients. The risk of mortality for patients with such coronary pattern is high due to the possibility of compromising the myocardial sole blood supply during transfer. Assessment of blood flow to all branches intraoperatively is mandatory to choose between either transfer single ostium or bypass grafting to the other coronary system.

## References

- 1 McMahon CJ, el Said HG, Feltes TF, Watrin CH, Hess BA, Fraser CD Jr. Preoperative identification of coronary arterial anatomy in complete transposition, and outcome after the arterial switch operation. *Cardiol Young* 2002;12(03):240–247
- 2 Gittenberger-de Groot AC, Sauer U, Quaegebeur J. Aortic intramural coronary artery in three hearts with transposition of the great arteries. *J Thorac Cardiovasc Surg* 1986;91(04):566–571
- 3 Scheule AM, Jonas RA. Management of transposition of the great arteries with single coronary artery. *Semin Thorac Cardiovasc Surg Pediatr Card Surg Annu* 2001;4:34–57
- 4 Pasquali SK, Hasselblad V, Li JS, Kong DF, Sanders SP. Coronary artery pattern and outcome of arterial switch operation for transposition of the great arteries: a meta-analysis. *Circulation* 2002;106(20):2575–2580
- 5 Massoudy P, Baltalarli A, de Leval MR, et al. Anatomic variability in coronary arterial distribution with regard to the arterial switch procedure. *Circulation* 2002;106(15):1980–1984
- 6 Quaegebeur JM. The Arterial Switch Operation. Rationale, Results and Perspectives. Thesis, Leiden University, The Netherlands; 1986