

# Are Prophylactic Intravenous Antibiotics Required in Routine Shoulder Arthroscopic Surgery? A Systematic Review of the Literature

Njalalle Baraza<sup>1</sup> Jordan Leith<sup>1</sup>

<sup>1</sup>Department of Orthopaedics, University of British Columbia, Vancouver, Canada

Joints 2018;6:54–57.

Address for correspondence Njalalle Baraza, MBChB, FRCS, Department of Orthopaedics, University of British Columbia, 3114 - 910 West 10th Avenue, Vancouver, BC V5Z 1M9, Canada (e-mail: njaleb@doctors.org.uk).

## Abstract

**Purpose** The purpose of this study was to find out from the literature the difference in infection rates between patients who did and patients who did not receive prophylactic antibiotics in arthroscopic shoulder surgery.

**Methods** We conducted a comprehensive search of the literature using Medline Ovid for prospective studies that looked at infection as the primary outcome following shoulder arthroscopy. The articles were then assessed for study design, outcome, and relevance to the specific question as part of the critical appraisal.

**Results** Eight partially relevant articles were obtained from the search, but there were no prospective studies comparing infection in patients who had prophylactic antibiotics versus those who did not in shoulder arthroscopy.

**Conclusion** No compelling evidence exists on the role of prophylactic antibiotics in preventing infections in shoulder arthroscopy.

**Level of Evidence** Level IV, systematic review of level IV studies.

## Keywords

- ▶ shoulder arthroscopy
- ▶ prophylactic antibiotics
- ▶ arthroscopic surgery
- ▶ infection

## Introduction

Shoulder arthroscopy is a well-established technique in dealing with a variety of shoulder conditions. The most common pathologies treated are instability, rotator cuff tears, subacromial impingement, acromioclavicular joint osteoarthritis, and loose bodies within the joint. As with many areas of orthopaedics, intravenous antibiotics are usually administered prior to surgery to reduce the potentially catastrophic sequelae of infection, which in the United States stands at 0.27%.<sup>1</sup> Though there is no doubt that antibiotics have been one of the most important factors in reduction of infection following surgery over the past century, their continued use given advancement in surgical techniques should be looked at in detail. They are not as benign as previously thought, with increasing cases of colitis and other gastrointestinal upsets, phlebitis, allergies, hypersensitivity,<sup>2</sup> and perhaps most worryingly the promotion of antibiotic-resistant strains of bacteria putting at risk vulnerable patient groups.

Shoulder arthroscopy benefits from small incisions, constant lavage with isotonic saline, minimal hardware, and, usually, relatively short operating times, all of which reduce the chances of infection.

The objective of this systematic review was to assess the postoperative infection rate in patients undergoing shoulder arthroscopy who had antibiotics around the time of the procedure and in those who did not, in an attempt to determine definitively whether antibiotics are required when performing routine arthroscopic procedures of the shoulder. The hypothesis was that there would be an increase in infection in patients who had not been administered with prophylactic antibiotics.

## Methods

We conducted a comprehensive search of the literature using Medline Ovid from 1946 to present. Articles published in English-language journals that looked at infection as the

received  
November 17, 2017  
accepted after revision  
February 3, 2018  
published online  
March 13, 2018

DOI <https://doi.org/10.1055/s-0038-1636950>  
ISSN 2282-4324.

Copyright © 2018 Georg Thieme  
Verlag KG Stuttgart · New York

License terms



primary outcome following shoulder arthroscopy were selected and analyzed. The search strategy used is reported in ►Table 1.

The authors then assessed the articles for quality, methods, study design, outcome, and relevance to the specific clinical question.

## Results

Seventy nine articles were obtained from the search. None of the 79 articles directly addressed our main study question by prospectively comparing infection in patients who had prophylactic antibiotics versus those who did not in shoulder arthroscopy. There were eight articles that were partially relevant to our study question (►Fig. 1). Two articles discussed the incidence, risk factors, and prophylaxis of infections following rotator cuff repairs.<sup>3,4</sup> The remaining six articles were only of limited interest to the authors, because they did not address the study question. One was a review article on septic arthritis after arthroscopy,<sup>5</sup> and another was a case report of pseudomonas osteomyelitis of the proximal humerus after arthroscopic rotator cuff repair.<sup>6</sup> One article discussed the incidence of *Propionibacterium acnes* (*P. acnes*) in shoulder arthroscopy;<sup>7</sup> one article looked at deep infection after rotator cuff repair;<sup>8</sup> one article focused on infection following shoulder instability surgery;<sup>9</sup> and one was a cost-benefit analysis of antibiotic prophylaxis in septic arthritis following arthroscopy, though the focus was not solely on the shoulder.<sup>10</sup>

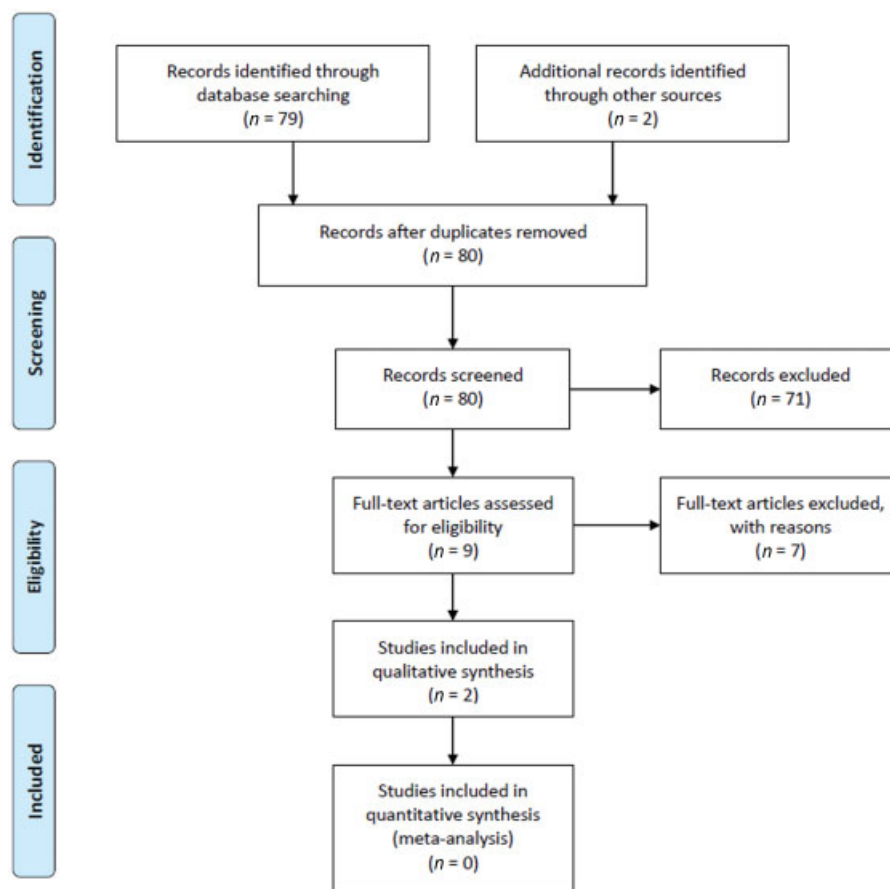
The article by Pauzenberger et al<sup>3</sup> was a retrospective comparative study of 3,294 arthroscopic rotator cuff repairs performed in a single department over a 10-year period. This study was interesting, as in the first half of the study period,

there was no routine perioperative administration of antibiotics, but this changed in the second half of the study period when administration of antibiotics (cephalosporin or clindamycin in the case of allergies) became the norm. Altogether, they had 28 deep infections during the study period (8.5/1000) with the leading pathogen being *Staphylococcus epidermidis* followed by *P. acnes* and *Staphylococcus aureus*. After introduction of perioperative antibiotics, there was a statistically significant reduction in infection rate from 1.54% to 0.28%. There was no statistically significant reduction in infection with *P. acnes* though. They found that other factors that correlated with increased risk of infection were male gender, possible due to different pathogen pattern in males and/or the presence of more body hair, increasing age and prolonged length of surgery. The main weakness of the study, as pointed out by the authors, was the retrospective design. Another weakness, perhaps as a corollary to the first, was the lack of a control group over the same study period to compare rates of infection. This significantly lowered the validity of the study, as several other changes responsible for the drop in infections may have taken place over the study period. Furthermore, the focus was on rotator cuff surgery alone, arguably the most technically demanding and lengthy shoulder procedure, while our question was on all arthroscopic procedures of the shoulder thought to require antibiotics. Nonetheless, it is a valuable study given the length of follow-up and the large number of patients and added some information on expected infection rates following arthroscopic rotator cuff repairs, which are useful when discussing perioperative risks with patients.

Vopat et al<sup>4</sup> performed a retrospective case-control study on patients who had an infection following rotator cuff repair in comparison with a randomly selected group of patients

**Table 1** Search strategy

Database: Ovid MEDLINE(R) Epub Ahead of Print, In-Process, and Other Non-Indexed Citations, Ovid MEDLINE(R) Daily, and Ovid MEDLINE(R) <1946 to Present>	
Search strategy	
1	exp antibacterial agents/ (653813)
2	Antibiotic*.mp. (329304)
3	Arthroscopy and shoulder.mp. (4529)
4	Shoulder arthroscopy.mp. (822)
5	Bankart repair.mp. (531)
6	(Rotator cuff repair and arthroscopy).mp. (901)
7	Joint instability and shoulder.mp. (3454)
8	Rotator cuff injuries/su [Surgery] (169)
9	Surgical wound infection and shoulder.mp. [mp = title, abstract, original title, name of substance word, subject heading word, keyword heading word, protocol supplementary concept word, rare disease supplementary concept word, unique identifier, synonyms] (156)
10	Bankart lesions/(10)
11	1 or 2 (801835)
12	3 or 4 or 5 or 6 or 7 or 8 or 9 or 10 (7788)
13	11 and 12 (79)



**Fig. 1** PRISMA 2009 flow diagram.

who had undergone cuff repair but not suffered an infection. The authors found an increased infection rate with open or mini-open rotator cuff repair when compared with arthroscopic techniques, and reiterated the male gender as another significant risk factor. The overall infection rate was 14/1,822 (7.6/1000). All the patients received prophylactic preoperative intravenous antibiotics. Limitations of the study were mainly related to characteristic of the participants and treatments (there were a mixture of arthroscopic and open cases) and again the lack of a comparison group, so it was not directly relevant to our review.

Bauer et al<sup>5</sup> showed that infection following joint arthroscopy was rare (<1%), but again there was no mention of the role of antibiotics and the article was more focused on the treatment of septic arthritis with no particular interest on shoulder arthroscopy.

The study by Chuang et al<sup>7</sup> highlighted the high incidence of *P. acnes* skin colonization on arthroscopic portal sites and the inoculation of this pathogen within the deep tissues despite the use of perioperative antibiotics, though because of its low virulence it does not always manifest itself as a clinical infection.

Aydin et al<sup>6</sup> reported a rare case of pseudomonas osteomyelitis in the shoulder after arthroscopic rotator cuff repair, and in an age of antibiotic overuse, it is a reminder of the

potential of unusual organisms to cause infection to the shoulder.

Athwal et al<sup>8</sup> detailed infections following rotator cuff repair, but majority of them underwent open repair. Similarly, the work done by Sperling et al<sup>9</sup> explored infection after instability surgery, although it did not limit the analysis to patients who only underwent arthroscopic surgery. Finally, D'Angelo and Ogilvie-Harris<sup>10</sup> reported a cost-benefit analysis in infection prevention for arthroscopy of both the knee and the shoulder. The authors concluded that prevention of infection with prophylactic antibiotics may be beneficial from an economic standpoint, albeit prophylaxis should be balanced against the risks and increasing cost of widespread antibiotic use in a complication that is rare.

## Discussion

The use of prophylactic antibiotics in shoulder arthroscopy that involves implants has become routine. Certainly, in the past, when procedures were lengthy, incisions larger, and equipment not as ergonomic, there was a higher chance of the patient contracting an infection. Antibiotics have reduced this potential for infection<sup>3</sup> and have, therefore, been adopted in arthroscopic practice, but their continued widespread use does, however, pose potentially serious

risks: gastrointestinal upsets, phlebitis, allergies, promotion of antibiotic-resistant strains of bacteria, and hypersensitivity,<sup>2</sup> not to mention the cost.

In recent times, with the advent of subspecialty training and expertise, improved instrumentation and operative techniques have meant a reduction in the length of procedures, hardware required, and anecdotally a reduction in the rate of infections. Furthermore, it has been shown that one of the most common pathogens found around the shoulder, *P. acnes*, inoculates portal sites and colonizes deep tissue irrespective of perioperative broad-spectrum antibiotic use and skin prepping solution.<sup>7,11</sup> Conversely, the other two commonly found pathogens *S. aureus* and *S. epidermidis* are readily controlled with chlorhexidine-based skin preparation and the use of broad-spectrum intravenous antibiotics. Despite a low rate of infection with *P. acnes* in shoulder arthroscopic surgery, its continued presence raises concern, as it is implicated as the main infection-causing pathogen following open surgical procedures of the shoulder.<sup>9,12–15</sup>

In addition to antibiotics and skin prepping solution, superficial infections of the shoulder may be influenced by the presence of nonabsorbable sutures in the skin or subdermis.<sup>9</sup> Stitch abscesses and sinuses have long been known to occasionally occur following wound closure with nonabsorbable sutures, and in shoulder arthroscopy their use is now relatively uncommon, with most surgeons opting for adhesive strips or an absorbable subcuticular suture. In many modern units, shoulder arthroscopy is done expeditiously, with a standard aseptic prepping technique, portal site closure method, often as a day case and it is important that surgeons now look at new evidence regarding the use of perioperative antibiotics in shoulder arthroscopy. Unfortunately, there is no study in the literature or in trial registries comparing the infection rate in these two groups of patients undergoing shoulder arthroscopy. Ideally, this question would be answered by a prospective randomized control trial.

Given the rapid advances that have taken place over the past decade, our greater understanding of the risks of casual antimicrobial administration, and the changing surgical landscape, there is now a real need for an up to date study comparing infection rates in patients who receive and those who do not receive perioperative antibiotics in routine shoulder arthroscopic procedures.

#### Conflict of Interest

None.

#### References

- 1 Yerosian MG, Arshi A, Terrell RD, Wang JC, McAllister DR, Petrigliano FA. Incidence of acute postoperative infections requiring reoperation after arthroscopic shoulder surgery. *Am J Sports Med* 2014;42(02):437–441
- 2 Mader JT, Cierny G III. The principles of the use of preventive antibiotics. *Clin Orthop Relat Res* 1984;(190):75–82
- 3 Pauzenberger L, Grieb A, Hexel M, Laky B, Anderl W, Heuberger P. Infections following arthroscopic rotator cuff repair: incidence, risk factors, and prophylaxis. *Knee Surg Sports Traumatol Arthrosc* 2017;25(02):595–601
- 4 Vopat BG, Lee BJ, DeStefano S, et al. Risk factors for infection after rotator cuff repair. *Arthroscopy* 2016;32(03):428–434
- 5 Bauer T, Boisrenoult P, Jenny JY. Post-arthroscopy septic arthritis: current data and practical recommendations. *Orthop Traumatol Surg Res* 2015;101(8, Suppl):S347–S350
- 6 Aydın N, Şirin E, Aydemir AN, Zengin G. Pseudomonas osteomyelitis of the proximal humerus after arthroscopic rotator cuff repair. *Acta Orthop Traumatol Turc* 2014;48(06):685–689
- 7 Chuang MJ, Jancosko JJ, Mendoza V, Nottage WM. The incidence of Propionibacterium acnes in shoulder arthroscopy. *Arthroscopy* 2015;31(09):1702–1707
- 8 Athwal GS, Sperling JW, Rispoli DM, Cofield RH. Deep infection after rotator cuff repair. *J Shoulder Elbow Surg* 2007;16(03):306–311
- 9 Sperling JW, Cofield RH, Torchia ME, Hanssen AD. Infection after shoulder instability surgery. *Clin Orthop Relat Res* 2003;(414):61–64
- 10 D'Angelo GL, Ogilvie-Harris DJ. Septic arthritis following arthroscopy, with cost/benefit analysis of antibiotic prophylaxis. *Arthroscopy* 1988;4(01):10–14
- 11 Saltzman MD, Nuber GW, Gryzlo SM, Marecek GS, Koh JL. Efficacy of surgical preparation solutions in shoulder surgery. *J Bone Joint Surg Am* 2009;91(08):1949–1953
- 12 Zeller V, Ghorbani A, Strady C, Leonard P, Mamoudy P, Desplaces N. Propionibacterium acnes: an agent of prosthetic joint infection and colonization. *J Infect* 2007;55(02):119–124
- 13 Topolski MS, Chin PY, Sperling JW, Cofield RH. Revision shoulder arthroplasty with positive intraoperative cultures: the value of preoperative studies and intraoperative histology. *J Shoulder Elbow Surg* 2006;15(04):402–406
- 14 Sperling JW, Kozak TK, Hanssen AD, Cofield RH. Infection after shoulder arthroplasty. *Clin Orthop Relat Res* 2001;(382):206–216
- 15 Patel A, Calfee RP, Plante M, Fischer SA, Green A. Propionibacterium acnes colonization of the human shoulder. *J Shoulder Elbow Surg* 2009;18(06):897–902