

Suboccipital craniectomy and duraplasty for Arnold-Chiari malformation 1: experience with 26 patients

Fabiana Policarpo¹, Jose Carlos Lynch¹, Celestino Esteves¹,
Ricardo Andrade¹, Vicente Temponi¹

Hospital Federal dos Servidores do Estado, Rio de Janeiro, RJ, Brasil.

ABSTRACT

Objective: Observe whether the suboccipital foramen magno decompression, duraplasty and microsurgery lyses of arachnoid bands are a safe and an effective treatment. **Method:** A retrospective study was carried out with 26 consecutive patients with CM1 malformations diagnosed, evaluated and operated at the Neurosurgical department of Servidores do Estado Hospital (HSE), from 1986 to 2010. The radiological studies, patient records, surgical descriptions, and when available, surgical videos, were reviewed, creating a database from which information pertinent to the present study was collected. The follow-up varied from 8 to 168 months (mean, 48 months). **Results:** Twenty-six patients underwent posterior fossa decompression with duraplasty. In this series, there is no operative death. We noticed beneficial outcome in 69.2% of patients, and 4 cases of transient postoperative complications. **Conclusion:** This experience with 26 cases CM1 proved that suboccipital craniectomy; duraplasty with autologous pericranium and microlysis of adhesions is a safe and effective procedure.

KEYWORDS

Decompression surgical, Arnold-Chiari malformation/physiopathology, Arnold-Chiari malformation/surgery, syringomyelia.

RESUMO

Craniectomia suboccipital e duroplastia para o tratamento da malformação de Arnold-Chiari tipo 1: experiência com 26 pacientes

Objetivo: Observar se a descompressão cirúrgica do foramen magno associada à duroplastia é um procedimento seguro e eficaz para o tratamento da malformação de Arnold-Chiari tipo 1. **Método:** Realizaram-se revisão retrospectiva dos prontuários, descrições cirúrgicas e imagens de 26 pacientes com malformação de Arnold-Chiari 1 operados no Hospital dos Servidores do Estado (HSE) no período entre 1986 e 2010. **Resultados:** O tratamento em 26 pacientes (68%) constituiu-se de craniectomia suboccipital, remoção do arco posterior de C1 e duroplastia. Os mesmos procedimentos foram acrescidos de laminectomia de C2 em 8 indivíduos (32%). Nesta série, não ocorreu nenhum óbito cirúrgico e observou-se melhora sintomática em 69,2% dos pacientes. **Conclusão:** A craniotomia occipital com a remoção do arco de C1 e/ou laminectomia de C2 e duroplastia mostrou-se eficaz, com baixa morbidade e sem mortalidade.

PALAVRAS-CHAVE

Descompressão cirúrgica, malformação de Arnold-Chiari/fisiopatologia, malformação de Arnold-Chiari/cirurgia, siringomielia.

Introduction

The Chiari malformation 1 (CM1) is regarded as a pathological hindbrain maldevelopment characterized by downward herniation of the cerebellar tonsils at least 3 to 5 mm below the foramen Magnum.^{4,10,22}

There has been open debate on the best operative treatment of this disease. Ellenbogen *et al.*⁵ described over 20 different practiced operations directed at CM1, but the optimal surgical management of CM1 is still unclear. Nowadays there is two main accepted techniques to treat the CM1: suboccipital decompression with duraplasty (PFDD) and

suboccipital decompression without duraplasty (PFD).^{3,8,9,11-18,20,23,24,26-28} This paper presents our experience with suboccipital decompression with duraplasty and microsurgery lyses of arachnoid bands in 26 consecutive patients.

Material and method

A retrospective study was carried out with 26 consecutive patients with CM1 diagnosed, evaluated and operated at the Neurosurgical Department of HSE, from

1. Neurosurgical Department of Hospital Federal dos Servidores do Estado, Rio de Janeiro, RJ, Brazil.

1996 to 2010. The radiological studies, patient records, surgical descriptions, and when available, surgical videos, were reviewed, creating a database from which information pertinent to the present study was collected. The follow-up varied from 8 to 168 months (mean, 48 months). This paper is a retrospective study; it has inherent biases and drawbacks; only a large prospective study can overcome this weakness.

Surgical procedure: In all cases the same microsurgery technique was used, following these general steps: general anesthesia with a carefully endotracheal intubation, then the patient is carefully placed in ventral decubitus position resting on the thoracolumbar support, and the head placed in the Mayfield. The procedure starts with the use of a 4,5x loupe and co-axial lightning. With a scalpel, a rectilinear midline incision is made starting in the superior occipital line and extending down to C3/C4 level. The fascia is opened in midline with a scalpel and the paravertebral muscles are carefully disinserted and laterally retracted with a periosteum elevator. With the autostatic retractors the exposure and the suboccipital scama, the posterior arch of C1 and the spinous processes and lamina of the C2 are visualized. Removal of the posterior arch of C1 is performed with the use of air drill and Laksell rongeur, if the cerebellar tonsils are at or below C2, the spinous processes and lamina of the C2 is removed as well. We perform a limited suboccipital craniectomy (4 x 4 cm) to enlarge the foramen magnum (FM) and allow for both decompression and maintenance of the posterior fossa neural elements.

During the whole procedure, careful hemostasia is performed with bipolar forceps under saline irrigation to keep the field bloodless, to prevent adhesions that can be induced around the spilled blood. At this moment, surgical microscope is introduced, and using a 10 to 16x magnification the dura mater is sectioned in Y-shaped fashion allowing access to neural element. The free border of the dura mater is sutured in the paravertebral musculature. Following, we made the microlysis of the adhesions that involves the brainstem, spinal cord and posterior inferior artery with extremely care to lyses only the adhesions without damage functional tissue or vessels, avoiding complications and, if necessary, the reduction or amputation of cerebellar tonsils, establishing an outlet for the fourth ventricle. Duraplasty is performed with pericranium to prevent straitening of the dural sac diameter and adhesions to the medulla or spinal cord. (Figures 1 A, B, C and D e Figures 2 A, B, C and D) Valsalva maneuver is performed aiming to detect the existence of a cerebral spinal fluid (CSF) leakage, which is sutured if present. Biological glue has been recently used on the suturing line with the purpose of preventing CFS fistula. The closure of the paravertebral musculature and fascia is performed in 3 planes to prevent muscle atrophy and cervical pain; the skin is sutured with 3.0 nylon.

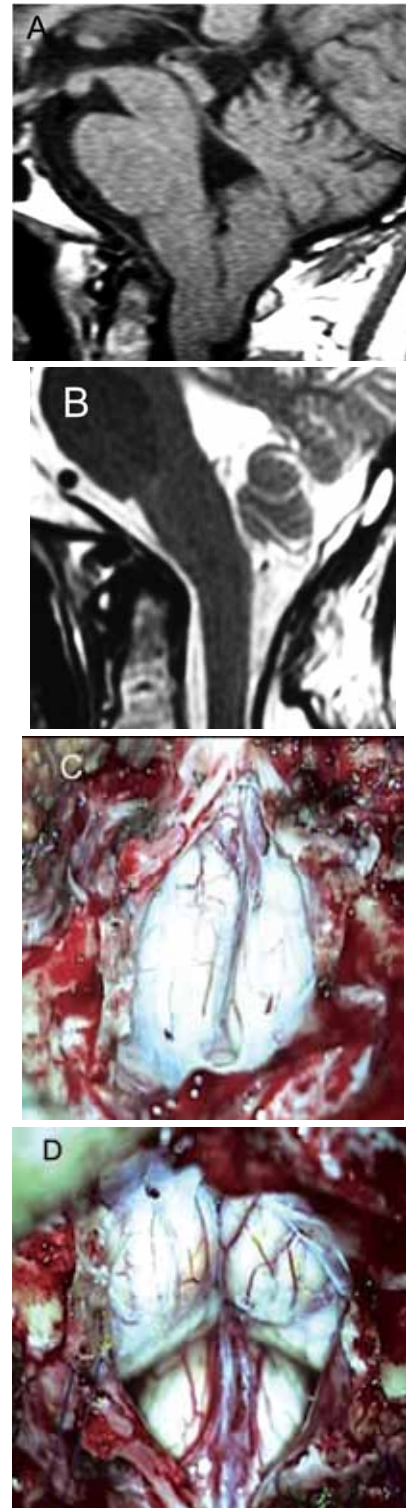


Figure 1 – (A) Preoperative sagittal T1 MR imaging demonstrating cerebellar tonsil herniation through the FM. (B) Postoperative sagittal T2 imaging after FM decompression and partial reduction of cerebellar tonsils, showing the CSF around brainstem and cerebellum, indicating that adequate decompression was achieved. (C) Operative image of the same patient demonstrating herniation of both cerebellar tonsils through the FM. (D) Operative image after partial subpial aspiration of cerebellar tonsils and lyses of adhesion, revealing reduction of the tonsils size and the spinal medullary junction.

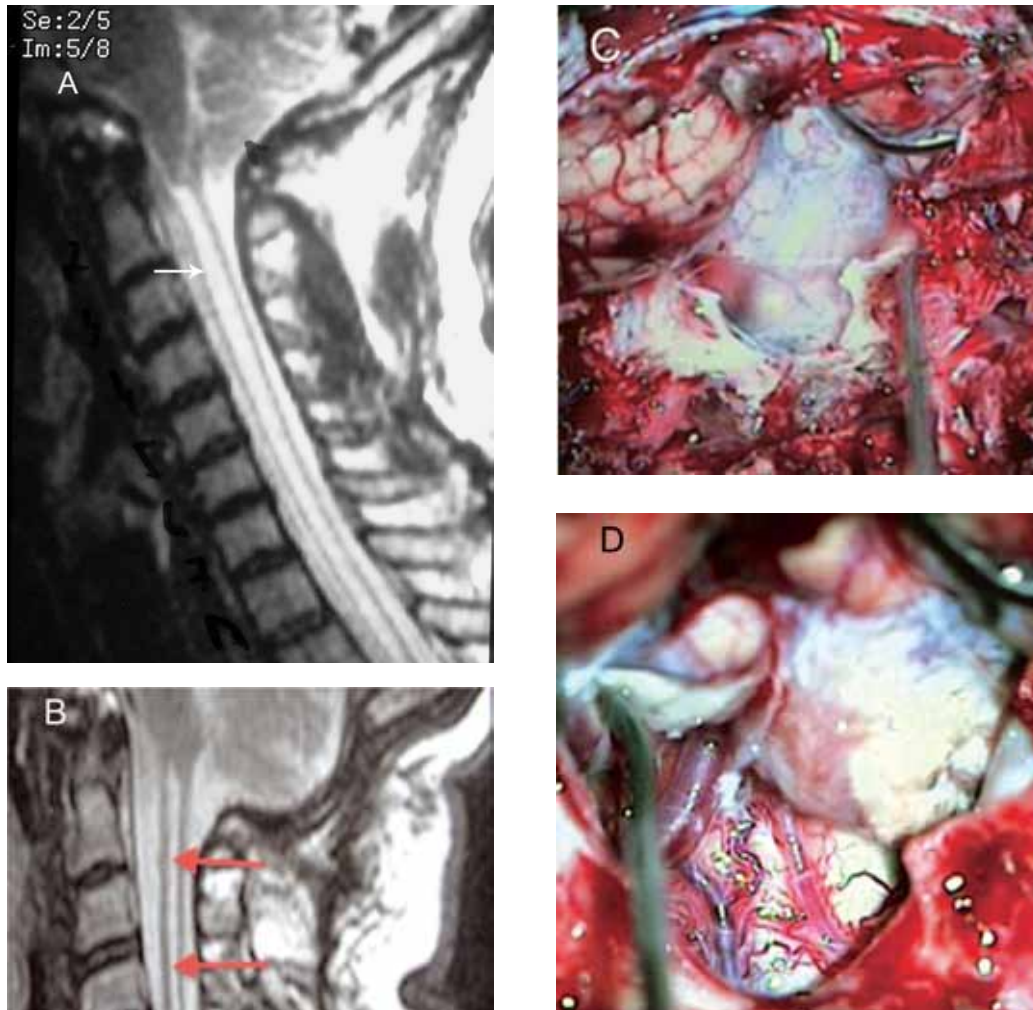


Figure 2 - (A) Sagittal T2 RM revealing CM with compression of brainstem and syringomyelia (arrow). (B) Post-operative T2 RM showing foramen magno decompression and decreased of the syringomyelia (arrows). (C) Intraoperative photographs demonstrating herniation of both tonsils. (D) Operative view of the posterior inferior artery, after tonsillectomy.

Results

In this series, there were 14 men and 12 women ranging in age from 5 to 72 years (Figure 3).

The duration of the symptoms varied from 2 months to 14 years (Figure 4). The signs and symptoms can be appreciated in the table 1.

The syringomyelia was present in 10 individuals (38.4%). Scoliosis was detected in 6 patients (23%). We diagnosed 4 cases (15%) of basilar invagination; one of them needed a trans oral odontectomy followed by posterior fixation.

Eighteen patients (69.2%) underwent posterior fossa decompression and removal of the posterior arch of C1 with duraplasty. In 8 patients (30.7%), because the cerebellar amygdalae reach the level of C2, we added C2 laminectomy. In 6 (23%) patients, we added tonsillectomy to improve the CSF flow.

There is no operative death in this series, but occurred 4 (15.3%) cases of postoperative transient complications without definitive neurological repercussion: one case of meningitis was cured with antibiotics. One patient developed CSF fistula that needed operative closure, another one with postoperative cerebellar ptosis needed cranioplasty, and a case of pseudo meningocele that resolved without further treatment.

During the follow up, we observed early beneficial outcome in 18 patients (69.2%), stabilization of the disease in 8 individuals (30.7%). Of this group, 6 (23.3%) showed late deterioration. In 10 patients diagnosed with syringomyelia only 3(30%) had a sustained improvement, as oppose as in the individuals without syringomyelia that present a permanent improvement in 10 individuals (62.5%) of the cases. Two patients died for clinical problems not related to CM1. One died of upper GI bleeding 3 years after the surgery and the other died of pulmonary cancer.

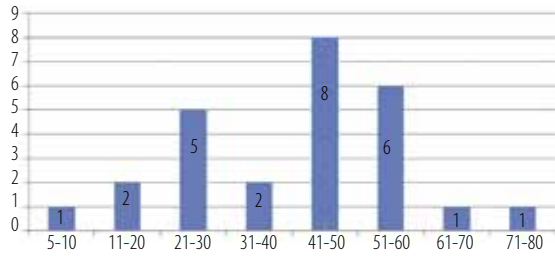


Figure 3 – Bar graphs revealing the age of 26 patients with CMI.

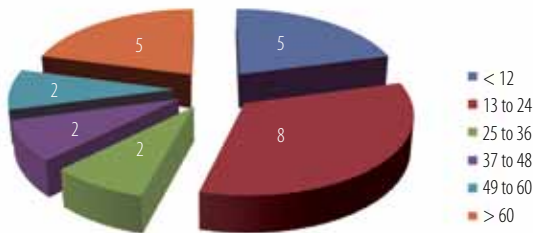


Figure 4 – Pie chart showing duration of signs and symptoms (in months) of 26 patients with CMI.

Table 1 – Sing and symptoms of 26 patients with CMI

	n	%
Paralysis	16	64
Hiperreflexia	13	52
Babinski	12	48
Arms paresis	12	48
Headache	12	48
Ataxia	11	44
Disestesias	11	44
Nistagmo	4	16
Dismetria	3	12
Hands muscle atrophy	2	8
Torcicolo	2	8
S. Horner	2	8
Disartria	2	8
Disfagia	2	8
Diplopia	2	8

Discussion

There are several mechanisms to explain pathogenesis of syringomyelia^{5,7} but this discussion is beyond the scope of this article.

There has been open debate on the best operative treatment of this disease.^{3,6,8,9,11-18,20,23,24,26-28}

The majority published series showed the benefits of the association of suboccipital craniectomy to enlarge the FM and duraplasty in achieving good surgical results.^{1,2,5,6,8,13-15,19-21,23,24,26-28}

But duraplasty and intradural manipulation have been associated with morbidity in certain series and some surgeons are advocating bony decompression only, as there appears to be a subset of patients who respond to this more simple intervention.^{3,9,11,13,14,24,28} The literature shows a low complication rate after non duraplasty decompression, but several patients submitted to bony decompression alone did not improved and needed reoperations.^{5,13,16}

The advantage of opening the dura is that it provides the necessary exposure to allow the microlysis of the adhesions that involves the brainstem, spinal cord and posterior inferior artery and if necessary the reduction or tonsillectomy. The microlysis of the adhesion is an important part of surgery. We are not in agreement with the authors who claim that a carefully performed microsurgery intradural operation creates more scarring and subsequent failure than an extradural procedure.

Bindal *et al.*² concluded that symptoms secondary to brain stem compression seemed reversible with decompressive surgery with duraplasty, whereas results with syringomyelia were much less dramatic with the same procedure.

Saez *et al.*²¹ presented the surgical decompression and duraplasty experience of 60 cases. They reported beneficial outcome in 65% of adult patients. The incidence and quality of postoperative improvement were greater initially but tended to decrease after several years.

In the experience of Paul *et al.*¹⁸, 69 patients underwent suboccipital craniectomy and C 1-3 laminectomy. In addition to the decompression, a fascial graft was interposed between the edges of the dural incision. They reported early improvement of the preoperative symptoms in 82% of patients.

Tubbs *et al.*^{26,27} recommend that patients with CM1 and syringomyelia undergo a decompressive surgery and duraplasty, if the veils are present, they should be fenestrate.

Milhorat and Bolognese¹³ and Milhorat *et al.*¹⁴ report that the most effective procedure with minimal complications has been a tailored osseous decompression of the craniocervical junction, duraplasty employing autologous pericranium, and microlysis of arachnoidal adhesions and tonsillar shrinkage as determined by intraoperative color Doppler ultrasonography.

McGirt *et al.*¹² advocated decompression with duraplasty only for the patients with tonsillar herniation to or below C2 and in the cases with associated syringomyelia. They used ultrasound in 279 cases of suboccipital

and C1 bony decompression alone, normal systolic pulsation of the tonsils and expansion of subarachnoid space was observed in 46% of the patients.

Mutchnick *et al.*¹⁶ performed a review of CM1 decompressions in 121 patients, 56 underwent PFD and 64 patients underwent PFDD. Of the 56 PFD patients, 7 (12.5%) needed a subsequent PFDD for symptomatic recurrence and they concluded PFD was associated with a higher rate of repeated decompression but they believe that may be justified by the significantly lower morbidity rate.

Furtado *et al.*⁶ preferred a durotomy in addition to bone decompression at the FM. This preference, they believe, is based in the presence of arachnoidal veils at the foramen of Magendie that also contribute to obstruction of CSF flow at the FM.

Among Us, Silva *et al.*⁸ preferred a craniectomy, aspiration of the tonsils and dural graft, creating a large cisterna magna. Taricco e Melo²⁵ performed PFDD plus fourth ventricle shunting in 29 individuals. They noticed improvement in 84% of them. Romero e Pereira²⁰ operated 6 patients with PFD and 10 with PFDD and suggested that patients with syringomyelia may have a higher like hood of improvement after PFDD.

The aforementioned studies clearly showed that optimal surgical management of CM1 is still unclear. This current experience with 26 cases of CM1 with suboccipital craniectomy, duraplasty with autologous pericranium and microlysis of adhesions proved a safe and effective procedure with symptomatic improving of 69.2%, result similar to others published series in the literature.^{2,16,18,21} In patients with syringomyelia, we observed that the improvement were much less dramatic with the same procedure. To date, there is no a clear answer if the patients, after an adequate FM decompression, but with a maintained syringomyelia should be reoperated and which procedure should be done. We did not reoperated a single patient with a maintained syringomyelia.

Conclusion

The neurosurgeon can elect either PFDD or PFD as the appropriate treatment, but the surgery must enlarge the foramen magnum and allow for both decompression and maintenance of the posterior fossa neural elements and reestablish the CSF flow. A further investigation is needed to define with clarity which surgery is better for a specific individual. What is appropriate for one patient is not necessarily appropriate for other.

The use of color Doppler US during surgery to taylor the foramen Magno decompression and the necessity of

duraplasty is an interesting new area of research with potentially important clinical implications, but more work is necessary before definitive conclusions can be made.

References

1. Alden TD, Ojemann JG, Park TS. Surgical treatment of Chiari I malformation: indications and approaches. *Neurosurg Focus.* 2001;11(1):E2.
2. Bindal AK, Dunsker SB, Tew JM Jr. Chiari I malformation: classification and management. *Neurosurgery.* 1995;37(6):1069-74.
3. Caldarelli M, Novegno F, Vassimi L, Romani R, Tamburrini G, Di Rocco C. The role of limited posterior fossa craniectomy in the surgical treatment of Chiari malformation type I: experience with a pediatric series. *J Neurosurg.* 2007;106(3 Suppl):187-95.
4. Carmel PW, Markesbery WR. Early descriptions of the Arnold-Chiari malformation. The contribution of John Cleland. *J Neurosurg.* 1972;37(5):543-7.
5. Ellenbogen RG, Armonda RA, Shaw DW, Winn HR. Toward a rational treatment of Chiari I malformation and syringomyelia. *Neurosurg Focus.* 2000;8(3):E6.
6. Furtado SV, Thakar S, Hegde AS. Correlation of functional outcome and natural history with clinicoradiological factors in surgically managed pediatric Chiari I malformation. *Neurosurgery.* 2011;68(2):319-27.
7. Gardner WJ, Angel J. The mechanism of syringomyelia and its surgical correction. *Clin Neurosurg.* 1958;6:131-40.
8. Silva JA, Melo LR, Araújo AF, Santos Jr AA. Resolution of syringomyelia in ten cases of "up-and-down Chiari malformation" after posterior fossa decompression. *Arq Neuropsiquiatr.* 2010;68(5):694-9.
9. James HE, Brant A. Treatment of the Chiari malformation with bone decompression without durotomy in children and young adults. *Childs Nerv Syst.* 2002;18(5):202-6.
10. Koehler PJ. Chiari's description of cerebellar ectopy (1891). With a summary of Cleland's and Arnold's contributions and some early observations on neural-tube defects. *J Neurosurg.* 1991;75(5):823-6.
11. Krieger MD, McComb JG, Levy ML. Toward a simpler surgical management of Chiari I malformation in a pediatric population. *Pediatr Neurosurg.* 1999;30(3):113-21.
12. McGirt MJ, Attenello FJ, Dato G, Gathinji M, Atiba A, Weingart JD, et al. Intraoperative ultrasonography as a guide to patient selection for duraplasty after suboccipital decompression in children with Chiari malformation type I. *J Neurosurg Pediatr.* 2008;2(1):52-7.
13. Milhorat TH, Bolognese PA. Tailored operative technique for Chiari type I malformation using intraoperative color Doppler ultrasonography. *Neurosurgery.* 2003;53(4):899-905; discussion 905-6.
14. Milhorat TH, Chou MW, Trinidad EM, Kula RW, Mandell M, Wolpert C, et al. Chiari I malformation redefined: clinical and radiographic findings for 364 symptomatic patients. *Neurosurgery.* 1999;44(5):1005-17.
15. Munshi I, Frim D, Stine-Reyes R, Weir BK, Hekmatpanah J, Brown F. Effects of posterior fossa decompression with and without duraplasty on Chiari malformation-associated hydromyelia. *Neurosurgery.* 2000;46(6):1384-9.
16. Mutchnick IS, Janjua RM, Moeller K, Moriarty TM. Decompression of Chiari malformation with and without

- duraplasty: morbidity versus recurrence. *J Neurosurg Pediatr.* 2010;5(5):474-8.
17. Oldfield EH, Muraszko K, Shawker TH, Patronas NJ. Pathophysiology of syringomyelia associated with Chiari I malformation of the cerebellar tonsils. Implications for diagnosis and treatment. *J Neurosurg.* 1994;80(1):3-15.
 18. Paul KS, Lye RH, Strang FA, Dutton J. Arnold-Chiari malformation. Review of 71 cases. *J Neurosurg.* 1983;58(2):183-7.
 19. Rhoton AL Jr. Microsurgery of Arnold-Chiari malformation in adults with and without hydromyelia. *J Neurosurg.* 1976;45(5):473-83.
 20. Romero FR, Pereira CA. Suboccipital craniectomy with or without duraplasty: what is the best choice in patients with Chiari type 1 malformation? *Arq Neuropsiquiatr.* 2010;68(4):623-6.
 21. Saez RJ, Onofrio BM, Yanagihara T. Experience with Arnold-Chiari malformation, 1960 to 1970. *J Neurosurg.* 1976;45(4):416-22.
 22. Salomão JF, Bellas AR, Leibinger RD, Barbosa AP, Brandão MA. [Symptomatic Chiari type II malformation]. *Arq Neuropsiquiatr.* 1998;56(1):98-106.
 23. Schijman E, Steinbok P. International survey on the management of Chiari I malformation and syringomyelia. *Childs Nerv Syst.* 2004;20(5):341-8.
 24. Stevenson KL. Chiari Type II malformation: past, present, and future. *Neurosurg Focus.* 2004;16(2):E5.
 25. Taricco MA, Melo LR. Retrospective study of patients with Chiari: malformation submitted to surgical treatment. *Arq Neuropsiquiatr.* 2008;66(2A):184-8.
 26. Tubbs RS, McGirt MJ, Oakes WJ. Surgical experience in 130 pediatric patients with Chiari I malformations. *J Neurosurg.* 2003;99(2):291-6.
 27. Tubbs RS, Smyth MD, Wellons JC 3rd, Oakes WJ. Arachnoid veils and the Chiari I malformation. *J Neurosurg.* 2004;100(5 Suppl Pediatrics):465-7.
 28. Yeh DD, Koch B, Crone KR. Intraoperative ultrasonography used to determine the extent of surgery necessary during posterior fossa decompression in children with Chiari malformation type I. *J Neurosurg.* 2006;105(1 Suppl):26-32.

Endereço para correspondência

José Carlos Lynch
 Rua Jardim Botânico, 600/605
 22461-000 – Rio de Janeiro, RJ, Brasil
 E-mail: cneuroamericas@uol.com.br