

Chronic subdural hematoma treatment with adjustment of programmable valve in idiopathic normal pressure hydrocephalus patient: a case report

Matheus Fernandes de Oliveira¹, Rodolfo Casimiro Reis¹,
Fernando Campos Gomes Pinto¹, José Marcus Rotta¹

Hospital do Servidor Público Estadual de São Paulo, São Paulo, Brazil.

ABSTRACT

Chronic subdural hematoma (CSDH) is a common entity in daily neurosurgical practice. It is considered a benign condition. Idiopathic normal pressure hydrocephalus (INPH) is characterized by gait disturbance, dementia and/or urinary incontinence added to dilation of ventricular system due to disturbance of cerebrospinal fluid (CSF) circulation with normal CSF pressure. We describe an experience of a conservative treatment of subdural hematoma based in the physiopathology and ability to control the pressure in programmable valves. The adjustment of programmable valves in the treatment of INPH allow us the therapeutic control of hydrocephalus and an important tool to manage complications, especially overshunting and undershunting.

KEYWORDS

Hydrocephalus, hematoma/complications, hematoma subdural.

RESUMO

Tratamento de hematoma subdural em paciente com hidrocefalia de pressão normal idiopática com ajuste da válvula programável: relato de caso

O hematoma subdural crônico é uma entidade neurocirúrgica comum, podendo ocorrer como complicação da derivação ventricular em pacientes com hidrocefalia de pressão normal idiopática. Descrevemos nossa experiência de tratamento conservador de hematoma subdural em paciente com derivação ventriculoperitoneal. O ajuste da pressão da válvula permite tanto a otimização terapêutica de pacientes com hidrocefalia de pressão normal idiopática quanto o manejo não invasivo de complicações de menor gravidade, principalmente hipodrenagem e hiperdrenagem.

PALAVRAS-CHAVE

Hidrocefalia, hematoma/complicações, hematoma subdural.

Introduction

Chronic subdural hematoma (CSDH) is one of the most common entities in daily neurosurgical practice. It is considered a benign condition, often affecting the elderly population.¹ Hematomas which are symptomatic or present a thickness greater than 1 centimeter should be conducted with surgical management, usually performed by frontal and/or parietal burr holes, while asymptomatic ones with thickness lesser than 1 centimeter can be managed conservatively.¹

Idiopathic normal pressure hydrocephalus (INPH) is a condition characterized by gait disturbance, dementia and/or urinary incontinence without causative disorders added to dilation of ventricular system due to disturbance of cerebrospinal fluid (CSF) circulation with normal CSF pressure.^{2,3} Ventricular CSF shunting is the main operative procedure in the management of INPH, and shunting with programmable valves is indicated, once the drainage pressure can be measured and controlled.^{2,3}

However, the surgical approach to INPH may cause complications, especially undershunting, infections, seizures, and overshunting. When the valve pressure is too low, there is excessive drainage, creating negative pressure inside skull, sometimes causing rupture of veins in subdural space, creating nontraumatic subdural hematomas or hygromas.^{4,5}

We describe an experience of a conservative treatment of subdural hematoma based in the physiopathology and ability to control the pressure in programmable valves.

Case description

We describe the case of a 83-year-old man with history of progressive dementia for 2 years associated to urinary incontinence and gait disturbance, being followed in Neurosurgery department, proceeding to diagnosis and treatment of INPH. He presented at computadorized tomography communicant hydrocephalus (Figure 1).

Before shunting, his physical examination revealed a Mini Mental Status of 15/30, Time up and GO of 41 seconds and Japanese Normal Pressure Hydrocephalus Grading Scale-revised (JNPHGS-R) of 3. After performing Tap test, he improved his Mini Mental to 19, his Time Up and Go to 30 seconds and remained with the same urinary complaints. The CSF pressure was 200 mmHg.

He was then elected for programmable valve shunting with Strata® Regular Valve, without any clinical

or immediate complication in the postoperative period. The settled valve pressure was then 110 mmHg.

After three months performing clinical follow-up, no change in valve pressure had been done and he referred moderate headache, being investigated with a new computadorized tomography, which revealed bilateral fronto-parietal hematomas (Figure 1). He was promptly admitted in Neurosurgery department and screened to access his clinical profile. The valve pressure was then 20 mmHg.

Once the patient was clinically stable, awake, without no other neurological deficits and under continuous monitoring, we chose to adjust the valve to a higher setting (140 mmHg) and observe the evolution of the subdural hematoma, although the common decision in this situation should be the surgical evacuation of the clot with bilateral burr holes.

He spent ten days in hospital performing tomographic control, revealing an impressive recovery of ventricular volume and brain complacency (presence of sulci and gyri) (Figure 1). The headache was then fully controlled.

He was discharged to continue follow up in a routine basis.

Discussion

A nontraumatic subdural hematoma or hygroma was seen in 14 (9.5%) of 147 patients with INPH in one study.⁵ Other larger series showed an incidence of subdural hematomas or hygromas of between 4 and 16% after shunting in patients with NPH.¹

The ability to treat subdural fluid collection in patients with NPH by adjusting the valve to a higher setting is a clear advantage of adjustable valves. Once fluid collection has been resorbed, the opening pressure can slowly be lowered in response to symptoms and signs of underdrainage and to minimize the risk of the redevelopment of a hematoma or a hygroma.³

It is clear, however, that the advantage of adjusting valves should be analyzed together with patient clinical status, once volumous subdural collections causing altered consciousness or neurological deficits must be promptly surgically drained.

In selected cases, nevertheless, the capacity of reprogramming the valve give us a valuable tool in the conduction of these shunting complications, avoiding additional surgical procedures and anesthetic injuries.

The adjustment of programmable valves in the treatment of INPH allow us not just the therapeutic control of hydrocephalus, but also an important tool to manage complications, especially overshunting and undershunting.

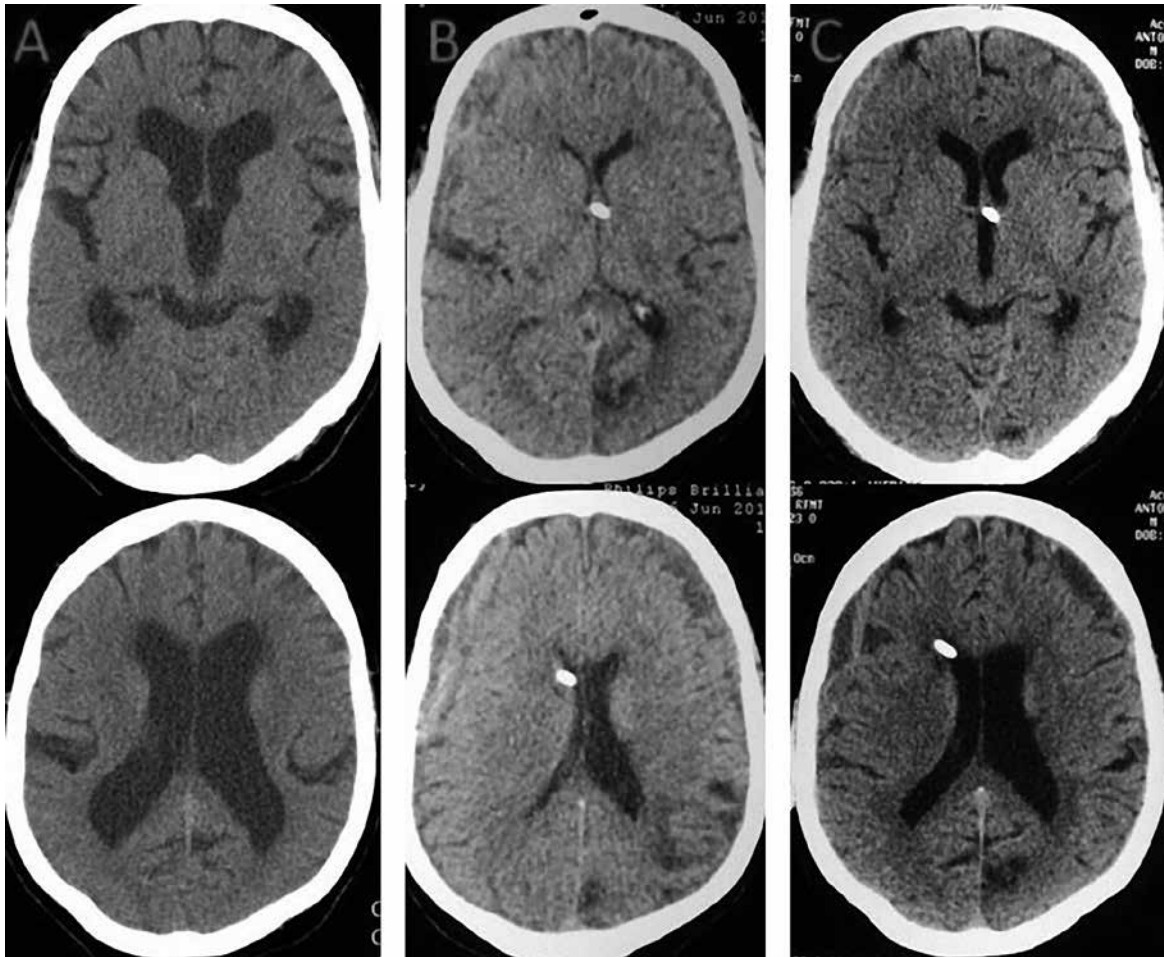


Figure 1 – Skull computadorized tomography of the subject before shunting (column A), in the admission with moderate headache due to bilateral chronic subdural hematomas (column B) and before discharge, with remarkable recovery of sulci and gyri (column C).

The treatment of chronic subdural hematomas by adjusting the shunting valve and avoiding extra surgical procedures, thus lowering morbidity, although already known and described in literature, represents a pertinent picture in daily neurosurgical management, given the increased number of shunting surgeries for the treatment of INPH.

Conflicts of interest

The authors declare no conflicts of interest.

References

1. Santarius T, Kirkpatrick PJ, Koliass AG, Hutchinson PJ. Working toward rational and evidence-based treatment

of chronic subdural hematoma. *Clin Neurosurg.* 2010;57: 112-22.

2. Carmel PW, Albright AL, Adelson PD, Canady A, Black P, Boydston W, et al. Incidence and management of subdural hematoma/hygroma with variable- and fixed-pressure differential valves: a randomized, controlled study of programmable compared with conventional valves. *Neurosurg Focus.* 1999;7(4):e7.
3. Zemack G, Romner B. Adjustable valves in normal-pressure hydrocephalus: a retrospective study of 218 patients. *Neurosurgery.* 2002;51(6):1392-400.
4. Kamano S, Nakano Y, Imanishi T, Hattori M. Management with a programmable pressure valve of subdural hematomas caused by a ventriculoperitoneal shunt: case report. *Surg Neurol.* 1991;35(5):381-3.
5. Samuelson S, Long DM, Chou SN. Subdural hematoma as a complication of shunting procedures for normal pressure hydrocephalus. *J Neurosurg.* 1972;37(5):548-51.

Correspondence address

Matheus Fernandes de Oliveira
Rua Pedro de Toledo, 1800, Vila Clementino
04039-002 – São Paulo, SP, Brazil
E-mail: mafernoliv@yahoo.com.br