

# ***Dissecting aneurysm of the distal superior cerebellar artery – Case report and assessment of endovascular treatment***

Arquimedes Cavalcante Cardoso<sup>1</sup>, Eduardo Leitão de Almeida Lima<sup>2</sup>,  
Thiago Mendes Barbosa<sup>2</sup>

Department of Neurosurgery at Getúlio Vargas Hospital; Med Imagem Hospital, Teresina, PI, Brazil.

## **ABSTRACT**

*Dissecting aneurysms located in peripheral regions of the cerebellar arteries are rare, and few cases have been described in the literature. Surgical treatment of these lesions may become difficult due to its relatively inaccessible location. Thus, the approach of these aneurysms through endovascular therapy may be an alternative treatment. We described a case of ruptured dissecting aneurysm located in the distal portion of the superior cerebellar artery, which was treated with endovascular embolization. We also discuss the results of endovascular therapy for this type of injury.*

## **KEYWORDS**

*Aneurysm dissecting, therapeutic embolization, subarachnoid hemorrhage.*

## **RESUMO**

***Aneurisma dissecante da artéria cerebelar superior distal – Relato de caso e avaliação do tratamento endovascular***

*Aneurismas dissecantes localizados em regiões periféricas das artérias cerebelares são de ocorrência incomum e poucos casos têm sido descritos na literatura. O tratamento cirúrgico dessas lesões pode se tornar difícil por causa de sua localização relativamente inacessível. Assim, a abordagem desses aneurismas por terapia endovascular pode ser um método alternativo de tratamento. Descrevemos um caso de aneurisma dissecante roto localizado na porção distal da artéria cerebelar superior que foi tratado com embolização endovascular. Discutimos, também, os resultados da terapia endovascular para esse tipo de lesão.*

## **PALAVRAS-CHAVE**

*Aneurisma dissecante, embolização terapêutica, hemorragia subaracnóidea.*

1 Neurosurgeon, Ph.D. at Federal University of Piauí (UFPI), Teresina, PI, Brazil.

2 Medicine student at UFPI, Teresina, PI, Brazil.

## Introduction

Aneurysms located on distal portions of the cerebellar arteries are rare.<sup>1</sup> Only about 0.2% of all intracranial aneurysms arise from the distal region of the superior cerebellar artery (SCA).<sup>2,3</sup> Dissecting peripheral aneurysms of the SCA are very uncommon and only a limited number have been previously described.<sup>4</sup> These lesions may be difficult to treat surgically owing to their inaccessibility and to the frequent inability to preserve the involved parent artery. An equivalent endovascular therapeutic approach becomes an alternative method of treatment.<sup>5</sup>

## Case report

A 38-year-old woman, looking healthy, presented a history of one day with headache, dizziness and vomiting. The pain was intense, located in the fronto-temporal region and came at night when the patient lay down to sleep. Her medical history did not include hypertension, *diabetes mellitus*, dyslipidemia, or episodes of head trauma. She did not have a history of smoking, alcoholism or chronic drug use. In no time the patient showed signs of motor impairment and loss of consciousness. She sought treatment at two hospitals, but was unsuccessful in diagnosis. She was treated only with analgesics for relief of headaches, which soon turned to ache. On a third hospital, 24 hours after the initial event, the patient was taken to the Neurology service, where she underwent a CT scan which revealed a subarachnoid hemorrhage. Angiography through magnetic resonance revealed a dissecting aneurysm of the right superior cerebellar artery, distal located of the basilar artery in the ambiens cistern topography (Figures 1A and 1B). Despite the young age and low surgical risk, we did not opt for an open surgical approach. The proposed treatment to this patient was a platinum coil embolization of the aneurysm, together with the parent artery embolization (Figures 2A and 2B). After 15 days of hospitalization, the patient was discharged with stable general framework, with no motor deficit, complaining only of mild diplopia and blurred vision, which were not present at the time of hospitalization. CT three months after the embolization coil shows the presence and absence of bleeding signals (Figure 3). Eight months after the procedure, the patient was in good general condition, without new episodes of headache, without complaints or neurologic motor deficits, complete improvement of diplopia and blurred vision, and capable of doing her normal work activities.

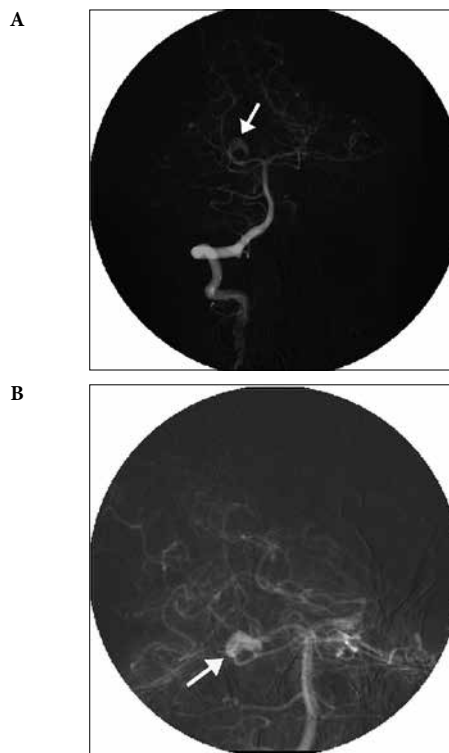


Figure 1 – (A, B) Preoperative cerebral angiography showing a dissecting aneurysm (arrow) of the distal superior cerebellar artery in the ambiens cistern topography.

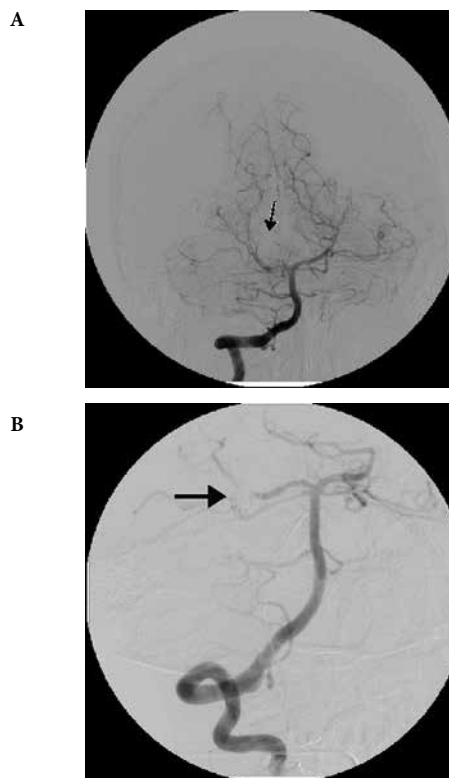


Figure 2 – (A, B) Postoperative cerebral angiography showing the disappearance of the aneurysmal image (arrow) after embolization of the aneurysm and parent artery.

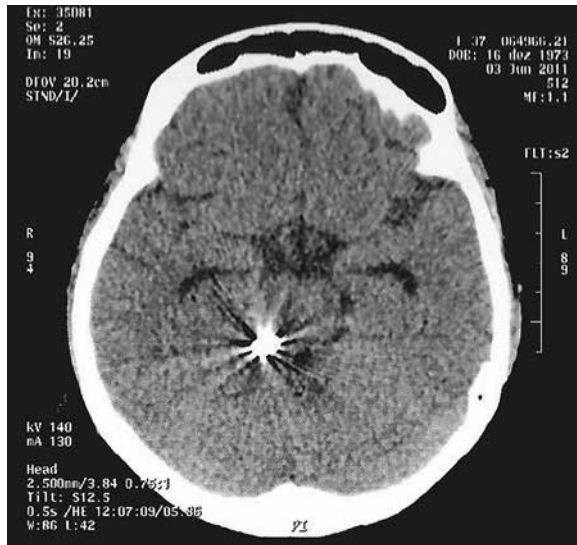


Figure 3 – Hyperdense material located in the right ambiens cistern topography (aneurysm embolization).

## Discussion

The SCA can be divided into four segments: 1) The anterior pontomesencephalic segment or the anterior pontine segment, which lies below the oculomotor nerve; 2) The lateral pontomesencephalic segment or the ambient segment, which courses below the trochlear and above the trigeminal nerve; 3) The cerebellomesencephalic segment or the quadrigeminal segment, which courses in the groove between the cerebellum and the upper brain stem; 4) The cortical segment, equivalent to the hemispheric, vermian, and marginal branches, which distributes to the cerebellar surface.<sup>6,7</sup> Peripheral SCA aneurysms can be either true saccular lesions or dissecting aneurysms. Saccular aneurysms of the distal SCA have been described most commonly involving the cortical or hemispheric segment at the level of the superior vermian branches. On the other hand, SCA dissecting and fusiform aneurysms are described more commonly in the cerebellomesencephalic and pontomesencephalic arterial segments.<sup>8-10</sup>

Superior cerebellar artery aneurysms typically manifest with subarachnoid hemorrhage (SAH). However, an isolated fourth nerve palsy occasionally has been reported.<sup>11,12</sup> The trochlear nerve, located beneath the tentorium, is vulnerable to injuries related to aneurysms involving the nearby posterior cerebral artery (P2 and P3 segments) or to SCA.<sup>13</sup> Angiographically, dissecting aneurysms have an appearance of “pearl and string” and this is due to the presence of blood within the wall of the artery.<sup>14,15</sup> When presenting with subarachnoid hemorrhage (SAH), the diagnosis of a dissecting aneurysm of the SCA can be difficult, requiring serial angiograms to identify progressive change in the affected vascular seg-

ment.<sup>8</sup> The diagnosis of ruptured peripheral aneurysm of the superior cerebellar artery should be considered when subarachnoid hemorrhage predominates in the perimesencephalic and superior cerebellar cisterns. The need to demonstrate the presence or absence of a surgical neck and to ascertain the proximity of the aneurysm to major branches are also relevant concerns for surgical planning.<sup>5</sup>

Surgical management of distal SCA aneurysms is challenging and is associated with high morbidity and mortality rates. Many complications are related to lower cranial nerve dysfunction because of the intimate relationship between these aneurysms and the cranial nerves.<sup>4,16</sup> Open surgical treatment of peripheral aneurysms of the superior cerebellar artery often requires parent artery occlusion with trapping. According to several surgical reports, occlusion of the superior cerebellar artery appears to be well tolerated, since there is generally good collateral circulation between the superior cerebellar artery and both posterior inferior cerebellar and anterior inferior cerebellar arteries through the vermian arcade, which often permits reconstitution of the distal branches of the superior cerebellar artery if more proximal occlusion of that artery occurs.<sup>5,17</sup>

The endovascular therapy may be a good alternative for the treatment of SCA aneurysms. Endovascular occlusion with detachable coils is feasible with good angiographic and clinical results and with low morbidity.<sup>5,18</sup> The main limitations of this technique concern intracranial aneurysms with wide necks because of the risk of coil migration from the aneurysmal lumen to the parent vessel and the presence of a narrowed parent artery, which may prevent the progression of the microcatheter. In these cases, parent artery occlusion has been suggested as an alternative treatment. Collateral blood flow may limit ischemic infarctions and outcome is usually good.<sup>1,19</sup> Parent artery occlusion by transarterial embolization can provide an equivalent therapeutic result without subjecting the patient to the hazards of anesthesia and craniotomy.<sup>5,18</sup>

Aneurysms involving the superior cerebellar artery are rare, there is little information in the literature about their assessment, treatment and monitoring. Through this case report we showed that the endovascular occlusion of the aneurysm or parent artery with coils is a viable alternative to open surgery and can achieve good clinical and angiographic results, and a low morbidity.

## References

1. Peluso JP, van Rooij WJ, Sluzewski M, Beute GN. Distal aneurysms of cerebellar arteries: incidence, clinical

- presentation, and outcome of endovascular parent vessel occlusion. *AJNR Am J Neuroradiol.* 2007;28(8):1573-8.
2. Matricali B, Seminara P. Aneurysm arising from the medial branch of the superior cerebellar artery. *Neurosurgery.* 1986;18(3):350-2.
  3. Murtagh F, Balis GA. CT localization of posterior fossa bleeding sites in subarachnoid hemorrhage. *Surg Neurol.* 1981;16:211-7.
  4. Nussbaum ES, Defillo A, Zelensky A, Stoller R, Nussbaum L. Dissecting peripheral superior cerebellar artery aneurysms: Report of two cases and review of the literature. *Surg Neurol Int.* 2011;2:69.
  5. Chaloupka JC, Putman CM, Awad IA. Endovascular therapeutic approach to peripheral aneurysms of the superior cerebellar artery. *AJNR Am J Neuroradiol.* 1996;17(7):1338-42.
  6. Hoffman HB, Margolis MT, Newton TH. The superior cerebellar artery. In: Newton TH, Potts DG, editors. *Radiology of the skull and brain, angiography.* St Louis: CV Mosby; 1974. p. 1809-30.
  7. Hardy DG, Peace DA, Rhoton AL Jr. Microsurgical anatomy of the superior cerebellar artery. *Neurosurgery.* 1980;6(1):10-28.
  8. Araki T, Fujiwara H, Murata H, Sampei T, Taki W. [Subarachnoid hemorrhage due to ruptured dissecting aneurysm of peripheral superior cerebellar artery]. *No Shinkei Geka.* 2002;30(12):1345-51.
  9. Iko M, Kazekawa K, Aikawa H, Onizuka M, Tanaka A. [Case of ruptured superior cerebellar artery dissection treated by endovascular embolization]. *No To Shinkei.* 2007;59(1):72-5.
  10. Itoyama Y, Uemura S, Hamada J, Man-tani A, Ushio Y. [Aneurysm arising from the cortical branch of the superior cerebellar artery: case report]. *No Shinkei Geka.* 1990;18(9):867-70.
  11. Collins TE, Mehalic TF, White TK, Pezzuti RT. Trochlear nerve palsy as the sole initial sign of an aneurysm of the superior cerebellar artery. *Neurosurgery.* 1992;30(2):258-61.
  12. Agostinis C, Caverni L, Moschini L, Rottoli MR, Foresti C. Paralysis of fourth cranial nerve due to superior-cerebellar artery aneurysm. *Neurology.* 1992 ;42(2):457-8.
  13. Pipegras DG. Posterior cerebral and superior cerebellar artery aneurysms. In: Apuzzo MJL, editor. *Brain Surgery.* New York: Churchill Livingstone;1993. p.1083-111.
  14. Anson JA, Lawton MT, Spetzler RF. Characteristics and surgical treatment of dolichoectatic and fusiform aneurysms. *J Neurosurg.* 1996;84(2):185-93.
  15. Atalay B, Altinors N, Yilmaz C, Caner H, Ozger O. Fusiform aneurysm of the superior cerebellar artery: short review article. *Acta Neurochir.* 2007;149(3): 291-4.
  16. Lubicz B, Leclerc X, Gauvrit JY, Lejeune JP, Pruvo JP. Endovascular treatment of peripheral cerebellar artery aneurysms. *AJNR Am J Neuroradiol.* 2003;24(6):1208-13.
  17. Takahashi M. *Atlas of vertebral angiography.* Baltimore: Md University Park Press; 1973.
  18. Haw C, Willinsky R, Agid R, TerBrugge K. The endovascular management of superior cerebellar artery aneurysms. *Can J Neurol Sci.* 2004;31(1):53-7.
  19. Khayata MH, Aymard A, Casasco A, Herbreteau D, Woimant F, Merland JJ. Selective endovascular techniques in the treatment of cerebral mycotic aneurysms. Report of three cases. *J Neurosurg.* 1993;78(4):661-5.

**Correspondence address**

Eduardo Leitão de Almeida Lima  
 Av. Ferroviária, 2872, Ilhotas  
 64014-080 - Teresina, PI, Brazil  
 Telephone: 55 86 8828-5118  
 E-mail: reialima@hotmail.com