

# Approaches to the third ventricle

Ricardo Brandão Fonseca<sup>1</sup>, Peter McLaren Black<sup>2</sup>, Hildo Azevedo Filho<sup>3</sup>

Harvard Medical School, Boston, MA, USA and Hospital da Restauração, Pernambuco University, Recife, PE, Brazil.

## ABSTRACT

*The authors review the main technical approaches to the third ventricle, the most common surgical indications and their results. The traditional open techniques are characterized by low rate of residual lesion and risk, although low, epilepsy postoperatively. Endoscopic techniques has gained wide acceptance by patients and neurosurgeons because of the low rates of complications and reduced hospital stay, however one still observes a higher rate of residual lesions, even asymptomatic. All the techniques mentioned have excellent results for surgical approaches to the third ventricle. We observe that the choice of technique will depend mainly on the familiarity of the surgeon and his service with each of these techniques.*

## KEYWORDS

*Therapeutical approaches, third ventricle, cerebral ventricle neoplasms, neuroendoscopy.*

## RESUMO

### **Acessos ao terceiro ventrículo**

*Os autores revisaram as principais formas de abordagem do terceiro ventrículo, as indicações cirúrgicas mais comuns e seus resultados. As técnicas abertas tradicionais são caracterizadas pelo baixo índice de lesões residuais e baixo risco de epilepsia pós-operatória. As técnicas endoscópicas têm ganhado espaço pelas baixas taxas de complicações e redução de dias de internamento, apesar de taxas maiores de lesões residuais, mesmo assintomáticas. Todas as técnicas mencionadas para os acessos ao terceiro ventrículo têm excelentes resultados. Observamos que a escolha da técnica utilizada dependerá, principalmente, da familiaridade do cirurgião e do seu serviço com cada uma delas.*

## PALAVRAS-CHAVE

*Conduas terapêuticas, terceiro ventrículo, neoplasias do ventrículo cerebral, neuroendoscopia.*

## Introduction

The third ventricle is a 2 x 3 cm located in the center of the brain surrounded by critical structures. Inevitably, all approaches to the third ventricle require passing through some neural structures.<sup>1</sup>

Since the first descriptions about approaches to the third ventricle to the present day, access to that region continues to be a challenge to neurosurgeons. Walter E. Dandy described the early concepts of the interhemispheric approach for a third ventricular tumor in his classic monograph titled “*Benign Tumors in the Third Ventricle of the Brain: Diagnosis and Treatment*”.

New and less invasive techniques, such as endoscopy, emerged but not yet replaced the more traditional microsurgical techniques, such as the transcortical and transcallosal approach.

In this work, the authors make a review of the anatomy of the third ventricle, the main indications

for surgery with their results and the approaches most commonly used nowadays.

## Anatomy of the third ventricle

The third ventricle is the deepest midline cavity. Its roof consists of the fornix telachoroidea, velum interpositum, choroidal arteries, and internal cerebral veins. Its anterior wall consists of the optic chiasm, lamina terminalis, anterior commissure, and rostrum of the corpus callosum. The posterior wall consists of the splenium of the corpus callosum, the pineal body, pulvinar, quadrigeminal plate, and superior cerebellar vermis. Its lateral walls consist of the thalamus and epithalamus, and finally, its floor consists of the infundibulum, tuber cinereum, mamillary body, posterior perforated substance, and tegmentum of the midbrain. The foramen of

1. Observer Fellowship, Department of Neurosurgery. Brigham and Women's Hospital; Harvard Medical School, Boston, MA, USA.
2. Franc D. Ingraham Professor of Neurosurgery. Department of Neurosurgery, Harvard Medical School, Boston, MA, USA.
3. Chairman, Department of Neurosurgery, Hospital da Restauração, Pernambuco University (UPE), Recife, PE, Brazil.

Monro includes the choroid plexus, medial posterior choroidal artery, internal cerebral vein, thalamostriate vein, and superior choroidal vein. The floor of the third ventricle indicates the optic recess, infundibular recess and aqueduct of Sylvius from anteriorly.

The posterior wall reveals the suprapineal recess, habenula commissure, pineal recess and posterior commissure from superiorly.<sup>2</sup>

## Surgical indications

There are different types of tumors that can be located on the third ventricle. Since the most frequent lesions, as colloid cysts (Figure 1), craniopharyngioma, glioma, even the less frequent, as choroid plexus papilloma, meningioma, dermoid/epidermoid tumors, sarcoidosis, metastatic disease, cysticercosis and vascular diseases.

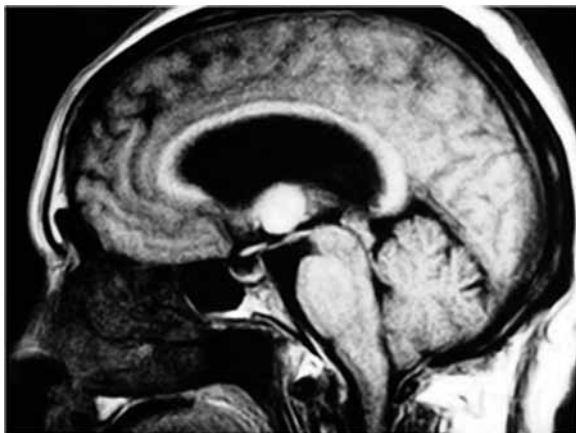


Figure 1 – MRI showing colloid cyst of the third ventricle.  
(Source: Dr. Azevedo-Filho's file)

### Colloid cysts

Typically their clinical presentation is formed with headaches. Among all these diseases, the colloid cysts are distinguished not only by their frequency – corresponding to 0.5% to 1% of brain tumors, but also because, even today, there is controversy about surgical indications and techniques.<sup>3,4</sup>

Surgery of the colloid cyst is surrounded by some controversy to this day. There are several ways to treat this illness: observation only, shunts, microsurgery (transcallosal and transcortical approaches), endoscopy surgery and aspiration of the cyst using stereotactic needles.

Observation: the only observation is advocated in those older patients, asymptomatic and without ventriculomegaly. This conduct is questionable due to the risk of sudden death or rapid deterioration in sen-

sorium.<sup>5,6</sup> The colloid cysts of the third ventricle should always be operated when symptomatic. Symptomatic cysts can lead to a sudden deterioration of consciousness level in up to 34% of patients.<sup>7</sup> However, the surgical indications for colloid cyst as an incidental finding in asymptomatic patients remain a controversial topic. Some authors indicate only periodic monitoring with imaging because the natural history of incidental cysts shows a favorable clinical outcome.<sup>8,9</sup> So, surgery would indicate when the imaging findings showed any change in lesion size or the patient had any sign or symptom of alert or hydrocephalus develops.

On the other hand, other authors warn that even asymptomatic, these cysts are not infrequently can cause sudden death or cause the patient to a vegetative state and delaying treatment; what could be avoided by early treatment. Some authors argue that patients in whom asymptomatic colloid cysts are diagnosed can be cared for safely with observation and serial neuroimaging. If a patient becomes symptomatic, the cyst is enlarging or hydrocephalus develops, prompt neurosurgical intervention is necessary to prevent the occurrence of neurological decline.<sup>8,9</sup>

The use of just shunts would be only a palliative treatment for intracranial hypertension and does not preclude a possible cyst growth. In addition, the patient is still subjected to all the complications inherent in shunts as obstruction and infection mainly.

Stereotactic aspiration: since its description in 1978, aspiration of the cyst using stereotactic needles has also been studied extensively. Early reports showed promising results, but the rate of residual and recurrent cysts was unacceptably high in subsequent studies.

## Transcortical surgery, transcallosal surgery and endoscopy

Regarding surgical techniques for treatment of colloid cyst, the endoscopic approach to the treatment of colloid cysts is safe, effective and well accepted by patients. This technique has shown an improvement in their results. However, although asymptomatic, recurrences (11.4%) cast a shadow that persists over the long term results and therefore the dispute with the traditional microsurgical treatment remains open.<sup>10</sup> Since its description in 1983 the use of endoscopy for removing third ventricular colloid cysts has gained popularity.<sup>11</sup> Several series have demonstrated the use of the endoscope to remove colloid cysts in the third ventricle is a safe and effective approach compared with transcallosal craniotomy. The endoscopic approach is associated with a shorter opera-

tive time, shorter hospital stay, and lower infection rate than the transcallosal approach. However, more patients treated endoscopically needed a reoperation for residual cyst. For Horn *et al.*<sup>12</sup> the endoscope can be considered as a first-line treatment for these lesions, with the understanding that a small number of these patients may need a transcallosal craniotomy to remove residual cysts.

On the other hand, Shapiro *et al.*<sup>13</sup>, on his work, said the despite the endoscopic surgery has been reported to be more cost-effective and safer than open craniotomy for resection of colloid cysts, it has a 5%-10% conversion rate to craniotomy, a 5% recurrence rate, a 5%-10% ventricular shunting rate, a 5%-10% epilepsy rate, and a 3-4 day hospital stay. Shapiro *et al.*<sup>13</sup> developed an interhemispheric, transcallosal, subchoroidal, fornix-sparing approach that allowed safe total resection of the colloid cyst and that appeared to be superior to the endoscopic approach.

The transcortical surgery has been a good approach too and is still widely used, preferably when there is ventricular dilatation. The risk of postoperative epilepsy and unnecessary neural injury away some neurosurgeons of this technique. Transcortical approach-related complications in the neurosurgical literature include seizures, hemiparesis, memory loss, confusion, and mutism.<sup>14</sup>

The strategy for colloid cyst removal is cyst wall opening, removal of the contents, dissection of the cyst wall from the choroid plexus with bipolar coagulation under low setting, and dissection of the cyst wall from the delicate wall of the third ventricle. Simple cyst aspiration alone is not an adequate treatment for this condition.

Other tumors, including craniopharyngiomas, pituitary adenomas, optic gliomas, astrocytomas, and, rarely, epidermoids and meningiomas, can be found in the anterior third ventricle. The microsurgical strategy for resection is as described for the abovementioned lesion. In general, there is a relatively well-defined cleavage plane between the wall of the third ventricle and the tumor. Central enucleation using the ultrasonic aspirator and micro-tumor rongeurs followed by lateral dissection of the capsule is the standard methodology when working in these corridors.<sup>1</sup>

**Astrocytomas:** despite the high prevalence of colloid cysts, pilocytic astrocytoma in some works is the most common lesion of the third ventricle region, reaching 22,2%. Its treatment is usually surgical, with the aim of radical resection to be permanently cured. A transcallosal approach has accepted as a good surgery option with excellent outcomes.<sup>14</sup>

**Craniopharyngioma:** this tumor is relatively common in the anterior third ventricle. On a study with 100 "Tumors in and Around the Anterior Third ventricle", has seen 46 craniopharyngioma and the minimally invasive anterior interhemispheric was chosen.<sup>15</sup> However, the major authors prefer the interhemispheric, anterior

transcallosal, transforaminal approach and its results are often rewarding. On a study with 144 patients with craniopharyngiomas, among the 30 patients who were operated on using this approach, no ischemic damage to the brain was observed during the postoperative period. In eight cases, deep double longitudinal grooves along the exposed corpus callosum, formed by stretched pericallosal arteries, were identified.<sup>16</sup>

**Ependymomas:** although no series has specifically examined ependymomas of the third ventricle, a review of the literature reveals an incidence of less than 8% among localized intracranial ependymomas. Approximately three-quarters of all intracranial ependymomas occur in the posterior fossa.<sup>17</sup>

Oppenheim *et al.*<sup>18</sup> shown that ependymomas represent 2% to 6% of all intracranial neoplasms. Only a small percentage of these occur in the third ventricle. Similarly, of tumors in the third ventricle, ependymomas are very rare. Yet the relative success that can be achieved by resection combined with radiotherapy – with preservation of neurological function – makes this a category worthy of note. Clearly, ependymomas should not be omitted from the differential diagnosis of tumors of the third ventricle. The transcallosal approach has been used with good results.<sup>18</sup>

**Choroid plexus tumors:** these tumors are uncommon, representing approximately 0.5% of intracranial tumors in all age groups. Choroid plexus neoplasms typically arise in the lateral ventricle. In adults, tumors are found in the fourth and third ventricle, and less frequently, the cerebellopontine angle. Most tumors are classified as benign choroids plexus papiloma on histological examination; 10% to 30% are classified as malignant choroids plexus carcinoma.<sup>19</sup> Total surgical excision is the treatment of choice for these tumors. The recommended surgical approach depends on the location of the lesion. An anterior transcallosal approach has been favored by many neurosurgeons.<sup>20,21</sup>

**Meningioma:** the first report of meningioma affecting the third ventricle was by Higier in 1913. Since then, several other reports have been published, with 47 cases reported in the literature review done by Renfro *et al.*<sup>22</sup> The prognosis of intraventricular meningiomas depends on total removal of the lesion and this is the most important factor in preventing recurrence. The most accepted access has been the transcallosal approach to these lesions.<sup>23</sup>

## Surgical techniques

The choice of the third ventricle approach basically depends on the exact location of the lesion, the differen-

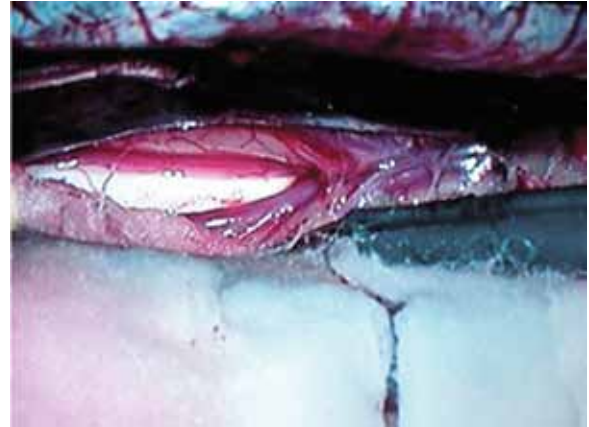tial diagnosis, lesion size, patient's clinical status and anatomical knowledge.

We do not consider here the access to the posterior portion of the third ventricle, such as infratentorial supracerebellar, therefore consider how access to the pineal region.

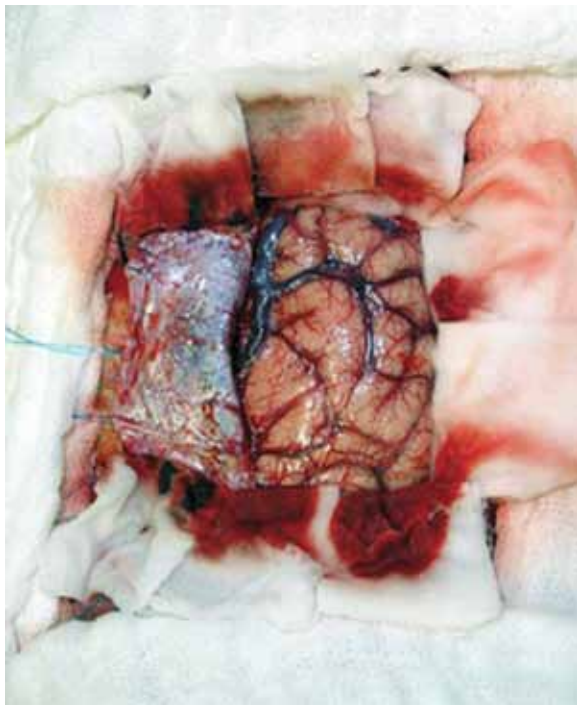
So we have basically three major approaches to the third ventricle: transcortical, transcallosal and endoscopic approaches. Less used, would be the sub-frontal via lamina terminalis access and esteroatactic techniques.

Classically, **at transcallosal approach**,<sup>24</sup> the craniotomy is placed two-thirds in front and one-third behind the coronal suture. The dura-mater is opened and reflected with its base toward the sinus. The position of the bone flap takes advantage of the fact that in most hemispheres, there exist an area relatively devoid of major draining veins just in front of the coronal suture (Figure 2). The next step in the approach is the interhemispheric dissection. Identification of the paired pericallosal arteries and the glistening white surface of the corpus callosum complete the initial interhemispheric approach (Figure 3). Next, an incision is made through the corpus callosum to access the lateral ventricle. The classic incision is 2 cm long, 2.5 cm behind the genu of the corpus callosum, reliably placing the foramen of Monro in the operative field. The incision is made between the pericallosal arteries (Figure 4). Once through the corpus callosum, anatomical landmarks

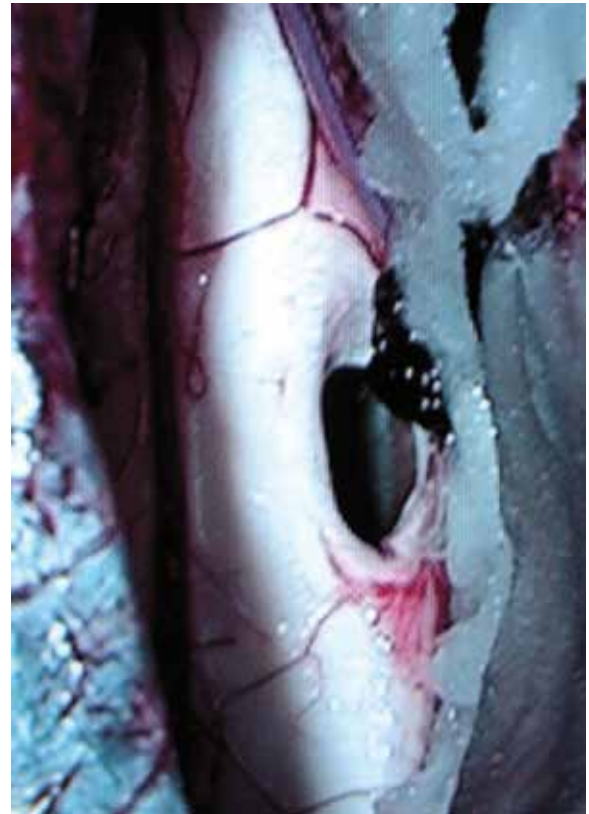are used to determine which ventricular space has been entered. The thalamostriate vein and foramen of Monro are used for localization. If the vein appears to the right of the foramen, then the right lateral ventricle has been entered; if it appears to the left, then the left lateral ventricle has been entered; and if no vein is visualized, then a cavum septum has been encountered.



*Figure 3 – Corpum callosum and pericallosal arteries.  
(Source: Dr. Azevedo-Filho's file)*



*Figure 2 – Opened dura mater with the base towards the sinus.  
(Source: Dr. Azevedo-Filho's file)*



*Figure 4 – Corpum callosum opened.  
(Source: Dr. Azevedo-Filho's file)*

## The transcortical approach

The patient is placed in the supine position with the head at a 30° angle. The free 4-5 cm bone flap is placed over the central portion of the middle frontal gyrus and must be large enough to permit retraction of the middle frontal gyrus in two directions. The flap is based on the coronal suture, with the medial border 2 cm off the midline and the posterior border 2 cm behind the coronal suture. In cases with small ventricles, tumor in both lateral ventricles, and tumor in the body of the lateral ventricle, surgery may be better performed via a transcallosal route or a combination of approaches.<sup>25</sup>

**The surgical indications for endoscopic approaches** are the same as those for conventional craniotomy approaches to the third ventricle. While a transcortical approach is favored for hydrocephalic patients, a transcallosal approach is used when the lateral ventricle is very small. Tumors in the third ventricle, such as colloid cysts, craniopharyngiomas, ependymomas, epidermoids, dermoids, germinomas, cysticercosis, hamartomas, or granulomatous lesions, can be biopsied or removed with these techniques. A transcortical endoscopic approach can also be used for surgical lesions in the lateral ventricular system such as meningiomas, ependymomas, astrocytomas, choroids plexus papillomas, dermoids, epidermoids, neurocytomas, cysticercosis, and others.<sup>26</sup>

## Endoscopic technique

The transcortical transventricular approach is made via a burr hole placed at the non-dominant frontal area, 1-inch lateral to the midline along the coronal suture. A folded vinyl tube, which can be expandable to a 1-cm tube by unfolding, is placed into the lateral ventricle toward the tumor under an image guidance system. The transcallosal approach is made via a burr hole placed along the lateral margin of the superior sagittal sinus at the non-dominant frontal area. The surgical corridor is made along the interhemispheric fissure. A rolled, cigarette-shaped, cotton patty is placed anteriorly and posteriorly along the surgical trajectory to keep the corridor open. The corpus callosum is opened, and the tumor is removed with surgical instruments inserted through the supported corridor parallel with the endoscope, which is mounted to an endoscope holder.<sup>26,27</sup>

After entering the lateral ventricle, we have three options for accessing the third ventricle: **transforaminal, transcoroideo transvelum interpositum and interforaminal** approaches.

The transchoroidal approach is based on opening the choroidal fissure that is located between the fornix and the thalamus to expose the roof of the third ventricle by gently mobilizing the fornix to the contralateral side.

The transcallosal transchoroidal approach was ideally suited to access the foramen of Monro and the middle and posterior thirds of the third ventricle. Exposure of the anterior third ventricle was limited by the columns of the fornix and by the presence of parietal cortical draining veins.<sup>28</sup>

In the neurosurgical literature, the complications related to the transchoroidal approach include infarction in the basal ganglia, mutism, and hemiparesis; complications related to the interforaminal approach include transient memory loss and hemiparesis.

In their work, Türe *et al.*<sup>28</sup> shown that the high incidence of posteriorly located ASV-ICV junctions is a significant factor influencing the successful course of surgery. Precise planning of the surgical approach is possible, because the location of the junction is revealed on preoperative neuroradiological studies, in particular on magnetic resonance venography. It can therefore be determined in advance which foramen of Monro qualifies for posterior enlargement to gain the widest possible access to the third ventricle.

In the interforaminal approach, the septum pellucidum is identified and split strictly midline by blunt dissection until the thick fibers of the fornix were visible. The interforaminal raphe division was also dissected in a blunt manner from the level of the foramen of Monro to the junction between the column of the fornix and the anterior commissure. Care was taken not to dissect too far anteriorly beyond the anterior commissure or posterior to the foramen of Monro.<sup>29</sup>

Although access quite feared by some neurosurgeons, the interforaminal approach offers excellent visualization of the entire 3rd ventricle, without the dependence on hydrocephalus or an extensive extra-axial mass to enhance the exposure. With proper planning and technique, it may be accomplished with a minimum of physiological consequence.<sup>30</sup>

## Complications

In general, the techniques transcortical and transcallosal have similar results, differing basically, such as seizures. Transcortical approach-related complications in the neurosurgical literature include seizures, hemiparesis, memory loss, confusion, and mutism. Transcallosal approach-related complications in the neurosurgical literature include hemiparesis, memory loss, akinetic mutism, and disconnection syndromes.<sup>14</sup>

The authors that prefer the technique transcallosal, argue a lower risk of seizures.<sup>31</sup> But, in an important work has been shown that the most common complications were paresis (37%), abulia/aphasia (28%), memory loss (18%), and cognitive change (17%) and occurred independently of the chosen approach. Over 75% of complications resolved within 12 months. The permanent neurological complication rate determined by a staff neurologist was 19.7%. Seizure attributable to surgery occurred following 8% of transcortical and 25% of transcallosal operations.<sup>32</sup>

Hellwig *et al.*<sup>33</sup> showed an experience with endoscopic technique of 10 years, only two complications in 20 patients. Hemorrhage in one case (not dead), one patient became shunt dependent due to aseptic meningitis postoperatively, only one patient needed a reoperation for recurrence of the cyst.

## Conclusion

When analyzing the results of various approaches to the third ventricle, finds that in all techniques mentioned satisfactory results. What would indicate the technique to be used, therefore, would be the exact topography of the tumor within the third ventricle, respecting the anatomical limitations of each approach and the surgeon's familiarity with the chosen access. The endoscopic technique is improving its results and establishing itself as a reliable method of choice for many neurosurgeons, to access the pathologies of the third ventricle.

It would require prospective studies that could compare the main techniques of approach to the third ventricle, which actually show superiority of one technique over another.

## References

- Wen HT, Rhoton AL Jr, de Oliveira E. Transchoroidal approach to the third ventricle: an anatomic study of the choroidal fissure and its clinical application. *Neurosurgery*. 1998;42(6):1205-17.
- Shizuo O, Samii A, Samii M. Operative techniques for tumors in the third ventricle. *Op Techn Neurosurg*. 2003;6(4):205-14.
- Batnitzky S, Sarwar M, Leeds NE, Schechter MM, Azar-Kia B. Colloid cysts of the third ventricle. *Radiology*. 1974;112(2):327-41.
- Little JR, MacCarty CS. Colloid cysts of the third ventricle. *J Neurosurg*. 1974;40(2):230-5.
- Aronica PA, Ahdab-Barmada M, Rozin L, Wecht CH. Sudden death in an adolescent boy due to a colloid cyst of the third ventricle. *Am J Forensic Med Pathol*. 1998;19(2):119-22.
- Büttner A, Winkler PA, Eisenmenger W, Weis S. Colloid cysts of the third ventricle with fatal outcome: a report of two cases and review of the literature. *Int J Legal Med*. 1997;110(5):260-6.
- de Witt Hamer PC, Verstegen MJ, De Haan RJ, Vandertop WP, Thomeer RT, Mooij JJ, et al. High risk of acute deterioration in patients harboring symptomatic colloid cysts of the third ventricle. *J Neurosurg*. 2002;96(6):1041-5.
- Pollock BE, Huston J 3rd. Natural history of asymptomatic colloid cysts of the third ventricle. *J Neurosurg*. 1999;91(3):364-9.
- Pollock BE, Schreiner SA, Huston J 3rd. A theory on the natural history of colloid cysts of the third ventricle. *Neurosurgery*. 2000;46(5):1077-81.
- Longatti P, Godano U, Gangemi M, Delitala A, Morace E, Genitori L, et al. Cooperative study by the Italian neuroendoscopy group on the treatment of 61 colloid cysts. *Childs Nerv Syst*. 2006;22(10):1263-7.
- Powell MP, Torrens MJ, Thomson JL, Horgan JG. Isodense colloid cysts of the third ventricle: a diagnostic and therapeutic problem resolved by ventriculocopy. *Neurosurgery*. 1983;13(3):234-7.
- Horn EM, Feiz-Erfan I, Bristol RE, Lekovic GP, Goslar PW, Smith KA, et al. Treatment options for third ventricular colloid cysts: comparison of open microsurgical versus endoscopic resection. *Neurosurgery*. 2007;60(4):613-8.
- Shapiro S, Rodgers R, Shah M, Fulkerson D, Campbell RL. Interhemispheric transcallosal subchoroidal fornx-sparing craniotomy for total resection of colloid cysts of the third ventricle. *J Neurosurg*. 2009;110(1):112-5.
- Yasargil MG, Abdulrauf SI. Surgery of intraventricular tumors. *Neurosurgery*. 2008;62(6 Suppl 3):1029-40.
- Hori T, Kawamata T, Amano K, Aihara Y, Ono M, Miki N. Anterior interhemispheric approach for 100 tumors in and around the anterior third ventricle. *Neurosurgery*. 2010;66(3 Suppl Operative):65-74.
- Yasargil MG, Curcic M, Kis M, Siegenthaler G, Teddy PJ, Roth P. Total removal of craniopharyngiomas. Approaches and long-term results in 144 patients. *J Neurosurg*. 1990;73(1):3-11.
- Swartz JD, Zimmerman RA, Bilaniuk LT. Computed tomography of intracranial ependymomas. *Radiology*. 1982;143(1):97-101.
- Oppenheim JS, Strauss RC, Mormino J, Sachdev VP, Rothman AS. Ependymomas of the third ventricle. *Neurosurgery*. 1994;34(2):350-2.
- Felix I, Phudhichareonrat S, Halliday WC, Becker LE. Choroid plexus tumors in children: immunohistochemical and scanning-electron-microscopic features. *Pediatr Neurosci*. 1987;13(5):263-9.
- Jooma R, Grant DN. Third ventricle choroid plexus papillomas. *Childs Brain*. 1983;10(4):242-50.
- Tsutsumi K, Asano T, Shigeno T, Matsui T. [Anterior transcallosal approach for the mass lesions in and around the third ventricle: with particular reference to the method of enlarging the foramen of Monro]. *No Shinkei Geka*. 1995;23(2):137-44.
- Renfro M, Delashaw JB, Peters K, Rhoton E. Anterior third ventricle meningioma in an adolescent: a case report. *Neurosurgery*. 1992;31(4):746-50.
- Costa LB Jr, Vilela MD, Lemos S. [Third ventricle meningioma in a child: case report]. *Arq Neuropsiquiatr*. 2000;58(3B):931-4.

24. Ulm AJ, Russo A, Albanese E, Tanriover N, Martins C, Mericle RM, et al. Limitations of the transcallosal transchoroidal approach to the third ventricle. *J Neurosurg.* 2009;111(3):600-9.
25. Ellenbogen RG. Transcortical surgery for lateral ventricular tumors. *Neurosurg Focus.* 2001;10(6):E2.
26. Hae-Dong J, David JH. Endoscopic approach for third ventricular tumors. *Oper Techn Neurosurg.* 2003;6(4):192-7.
27. Lewis AI, Crone KR, Taha J, van Loveren HR, Yeh HS, Tew JM Jr. Surgical resection of third ventricle colloid cysts. Preliminary results comparing transcallosal microsurgery with endoscopy. *J Neurosurg.* 1994;81(2):174-8.
28. Türe U, Yasargil MG, Al-Mefty O. The transcallosal-transforaminal approach to the third ventricle with regard to the venous variations in this region. *J Neurosurg.* 1997;87(5):706-15.
29. Siwanuwatn R, Deshmukh P, Feiz-Erfan I, Rekate HL, Zabramski JM, Spetzler RF, et al. Microsurgical anatomy of the transcallosal anterior interforaminal approach to the third ventricle. *Neurosurgery.* 2005;56(2 Suppl):390-6.
30. Apuzzo ML, Chikovani OK, Gott PS, Teng EL, Zee CS, Giannotta SL, et al. Transcallosal, interfornicial approaches for lesions affecting the third ventricle: surgical considerations and consequences. *Neurosurgery.* 1982;10(5):547-54.
31. Jeeves MA, Simpson DA, Geffen G. Functional consequences of the transcallosal removal of intraventricular tumours. *J Neurol Neurosurg Psychiatry.* 1979;42(2):134-42.
32. Milligan BD, Meyer FB. Morbidity of transcallosal and transcortical approaches to lesions in and around the lateral and third ventricles: a single-institution experience. *Neurosurgery.* 2010;67(6):1483-96.
33. Hellwig D, Bauer BL, Schulte M, Gatscher S, Riegel T, Bertalanffy H. Neuroendoscopic treatment for colloid cysts of the third ventricle: the experience of a decade. *Neurosurgery.* 2003;52(3):525-33.

**Correspondence address**

Ricardo Brandão Fonseca  
 Av. Cardoso de Sá, 13, ap. 802, Centro  
 56302110 – Petrolina, PE, Brazil  
 Telephone: (55 87) 9606-2010  
 E-mail: ricardoneurocirurgia@uol.com.br