

Microsurgical Resection of Lateral Tuberculum Sellae Meningioma: Operative Video

Duarte N. C. Cândido¹ Paulo E. H. Nakashima¹ Jean Gonçalves de Oliveira³ Luis A. B. Borba^{1,2}

¹Hospital Universitário Evangélico de Curitiba, Department of Neurosurgery, Curitiba, Paraná, Brazil

²Federal University of Parana, Department of Neurosurgery, Curitiba, Paraná, Brazil

³Hospital Beneficência Portuguesa de São Paulo, São Paulo, São Paulo, Brazil

Address for correspondence Luis A. B. Borba, MD, PhD, IFAANS, Rua Gen. Carneiro, 181 - Alto da Glória, Curitiba, Paraná, Brazil. 80060-900 (e-mail: luisborba@me.com).

J Neurol Surg B 2018;79(suppl S2):S221–S222.

Abstract

Tuberculum Sellae Meningiomas (TSMs) are lesions dramatically related to the optic apparatus once the principal clinical complain remains on visual alterations. This is the main picture on decision making to evaluate the best time, risk-benefit, and surgical approaches to the patient treatment. In this video, we present a 65 years old female with 30 days complaint of unilateral (right) complete blindness and complete impaired right eye field test. On physical examination, there were normal pupillary function to light tests. The scans demonstrated the presence of a TSM mostly related to the right optic nerve and encasing it altogether with the right internal carotid artery. Promptly, surgery was addressed using a modified one piece crani-orbital-zygomatic approach with extra-dural anterior clinoidectomy, as this is the procedure of choice of the senior author (LB), with easy access to decompression of the optic canal and nerve. As demonstrated on the video, the optic nerve was encased by the tumor and pushed upwards against the falciform ligament. Complete resection and decompression was established with step by step dissection, starting unroofing the optic canal, opening the ligament and finally with carefully tumor debulking. Pathology demonstrated a grade one meningioma. The patient improved remarkably her visual acuity and visual field tests on the postoperative period, emphasizing the importance of early treatment for nerve function outcome.

The link to the video can be found at: <https://youtu.be/pALZqDUkltQ>.

Keywords

- ▶ tuberculum sellae
- ▶ meningioma
- ▶ skull base
- ▶ optic nerve decompression

Conflict of Interest
None.

Financial Support
The authors had no financial support.



www.thieme.com/skullbasevideos

www.thieme.com/jnlsvideos

received
October 15, 2017
accepted after revision
December 7, 2017
published online
January 18, 2018

DOI <https://doi.org/10.1055/s-0038-1623528>.
ISSN 2193-6331.

© 2018 Georg Thieme Verlag KG
Stuttgart · New York

License terms



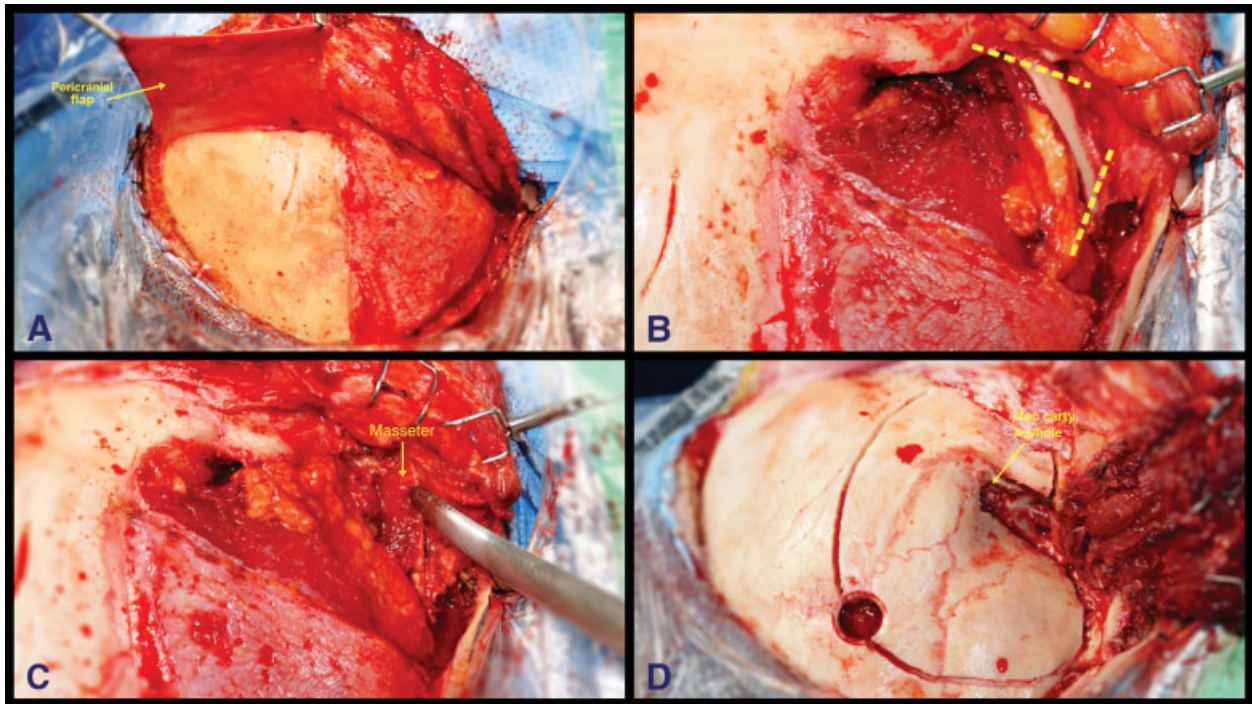


Fig. 1 (A) Archiform incision starting at the tragus and extending to the contralateral midpupillary line behind hairline. Pericranial flap harvested. (B) “V” shape zygomatic arch incision on both anterior and posterior zygoma roots. (C) Masseter muscle preserved attached to the zygoma. (D) MacCarty keyhole behind the frontozygomatic suture and bone cuts performed for the modified one piece craniotomy.

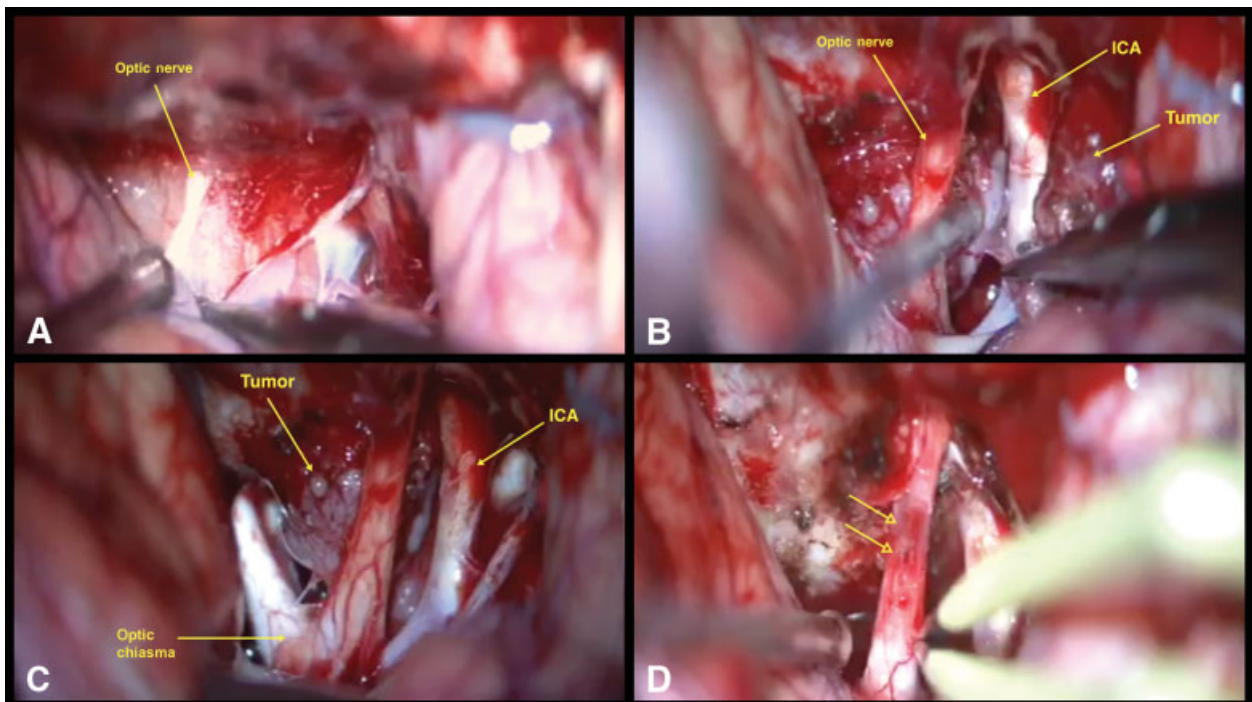


Fig. 2 (A) Optic nerve encased 360 degrees by tumor and pushed upward against the falciform ligament. (B) After dissections of both the neural structures and internal carotid artery (ICA) and the tumor devascularized, it is debulked and splitted in small pieces for secure removal. (C) Final piece still attached to the tuberculum sellae under the right optic nerve. (D) Arrows demonstrating the nerve contusion at the falciform ligament caused by tumor growth. The optic canal is all opened and the anterior clinoid removed.