

# Paraspinal Lumbar Spine Approach - Wiltse Access

## *Abordagem paravertebral da coluna lombar - acesso de Wiltse*

Nícollas Nunes Rabelo<sup>1</sup> Bruno Nascimento Bettencourt da Silva<sup>1</sup> Luciano José Silveira Filho<sup>1</sup>  
George Santos dos Passos<sup>1</sup> Vitor Hugo Honorato Pereira<sup>1</sup> Luiz Antônio Araujo Dias Junior<sup>1</sup>  
Luiz Antônio Araujo Dias<sup>1</sup> Koji Tanaka<sup>1</sup>

<sup>1</sup>Department of Neurosurgery, Hospital da Santa Casa de Ribeirão Preto, Ribeirão Preto, SP, Brazil

Address for correspondence Nícollas Nunes Rabelo, MD, Av. Antonio Diederichsen, n. 190, apt. 193, Jardim América, CEP: 14020-250, Ribeirão Preto, SP, Brazil (e-mail: nicollasrabelo@hotmail.com).

Arq Bras Neurocir 2017;36:167–171.

### Abstract

**Introduction** Technical developments in spinal surgery have reduced the number of surgical incisions and of the length of time for the procedure.

**Objective** Describe topographical landmarks, anatomy and characteristics of the Wiltse access, a paraspinal approach to the lumbar spine.

**Methods** A review of the literature was performed using as databases: PubMed, Embase, Science Direct, the Cochran Database and Google Scholar. Total 22 papers met the inclusion criteria, and they were all published between 1959 and 2016.

**Discussion** The Wiltse approach is performed by median skin incision with lateral muscle dissection between the multifidus and the longissimus muscles, in a natural pathway. This approach allows access to the pedicles and to the lateral recess, enabling the performance of posterior spinal fusion and decompression and minimally invasive discectomy techniques. This access is less traumatic than the median approach, and it is ideal for lower levels, like L4–5 and L5-S1.

**Conclusion** The authors strongly encourage this approach because they believe that, when well-indicated, the benefits outweigh the disadvantages and complications due to the fact that it is a less invasive procedure.

### Keywords

- ▶ Wiltse access
- ▶ lumbar spine
- ▶ paraspinal approach
- ▶ spine surgery

### Resumo

**Introdução** Os desenvolvimentos técnicos na cirurgia da coluna vertebral têm proporcionado a redução das incisões cirúrgicas e da duração do procedimento.

**Objetivo** Descrever marcos topográficos, anatômicos e características do acesso de Wiltse, uma abordagem da coluna vertebral lombar.

**Métodos** A revisão bibliográfica foi realizada utilizando como banco de dados: PubMed, Embase, Science Direct, banco de dados Cochran e Google Scholar. Foram encontrados 22 trabalhos que atenderam aos critérios de inclusão, todos publicados entre 1959 e 2016.

**Discussão** A abordagem de Wiltse é realizada pela incisão cutânea mediana com dissecação muscular lateral entre o músculo multifidus e o músculo longissimus, na via

received  
February 5, 2017  
accepted  
May 9, 2017  
published online  
July 12, 2017

DOI <https://doi.org/10.1055/s-0037-1604267>.  
ISSN 0103-5355.

Copyright © 2017 by Thieme Revinter  
Publicações Ltda, Rio de Janeiro, Brazil

License terms



**Palavras-chaves**

- ▶ acesso de Wiltse
- ▶ coluna lombar
- ▶ abordagem paraespinal
- ▶ cirurgia da coluna vertebral

natural. Esta abordagem permite o acesso aos pedículos e ao recesso lateral, e a realização de fusão posterior e descompressão de fratura da coluna vertebral e técnicas de discectomia minimamente invasivas. Este acesso é menos traumático do que a abordagem mediana, e é ideal para níveis mais baixos, como L4-5 e L5-S1.

**Conclusão** Os autores recomendam esta abordagem, pois acreditam que os benefícios desta técnica, quando bem indicada, superam as desvantagens e complicações por ser esta menos invasiva.

**Introduction**

Different approach methods to spinal surgery have been developed to reduce the aggressiveness of the current surgical approach.

Authors like Mathieu and Dermirleau, in 1936, described one technique in which the spine access to the sacrospinous muscle was lateral. In their approach, a hole was drilled through the ilium, and an iliac graft was driven through this hole to engage the transverse process of L5. Watkins, in 1953, first described an approach that was lateral to the sacrospinalis. In this approach, he took a thin flake of bone off the ilium with the entire sacrospinalis group of muscles attached. Thus, the iliocostalis, the longissimus, and part of the multifidus could be retracted upward and medially, out of way. Ray<sup>4</sup> described a far lateral approach to the spine, which he calls “the paralateral approach”. Like Watkins’ approach, it was lateral to all three muscles of the sacrospinalis group between the iliocostalis and the quadratus lumborum. In this approach, the muscles are split, differing from Watkins’ approach, in which a flake of bone is left attached at its medial end, and is turned cranially and medially. If, at the L5 level, the crest of the ilium is in the way, Ray recommends the removal of bone from the posterior iliac spine as necessary.<sup>1-4</sup>

The paravertebral approach, initially described by Leon Wiltse in California in 1968 as two paramedian skin incisions and then, posteriorly, a single median incision, is a surgical approach that results in less tissue injury, and that has provided a postoperative outcome with less pain, less bleeding and less damage to the muscles. These lower morbidity characteristics of the Wiltse approach stand as an alternative to the large incisions used in the past, allowing better results in surgery of the lumbar spine.<sup>4</sup>

The purpose of this review is to describe the topographical landmarks, anatomy and characteristics of the Wiltse access, a paraspinal approach to the lumbar spine.

**Material and Methods**

We performed a review of the literature using PubMed, Science Direct, Embase, Clinical Trials, Ebsco, and Scielo databases. We selected articles from the period between 1959 and 2016. There were total 22 papers that met the inclusion criteria. These were studies that described the original technique of lateral access to the posterior spine, by Wiltse, and compared the midline and paraspinal posterior approaches.

**Technique**

This spine posterolateral approach with midline skin incision creates a wall along the sacrospinalis muscle. This anatomical avascular space lies between the multifidus (medial) and the longissimus (lateral) muscles.<sup>5,6</sup>

The procedure was initially described with two cutaneous incisions located at 30 mm from the spinous processes to allow direct access to the osseous structures. But, in 1988, Wiltse extended the indications of this approach, and recommended that a single median incision be performed.<sup>7</sup>

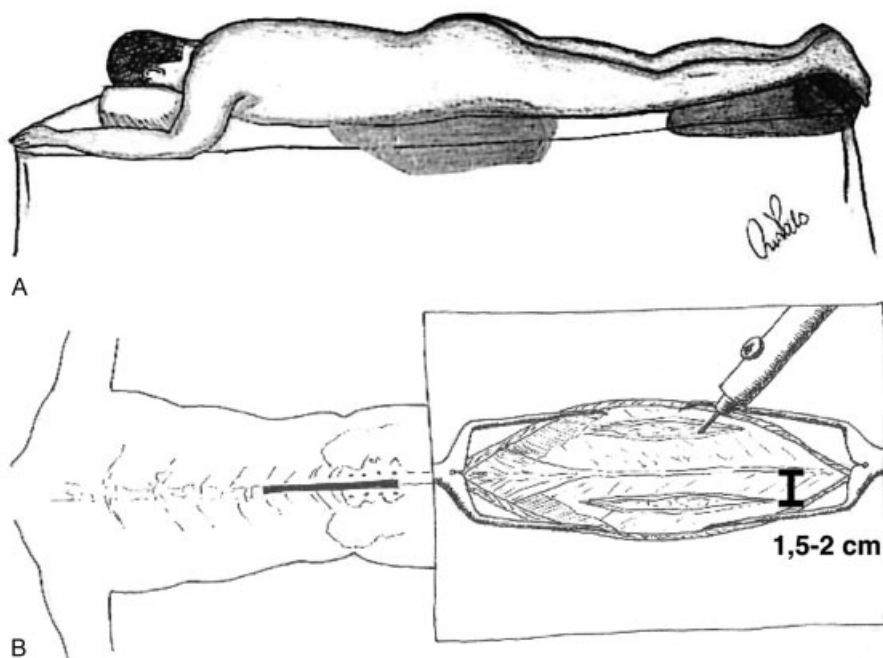
The surgery should be performed with the patient in prone position, with cushions under the pelvis and thorax, and with the table flexed, but this is a matter of individual preference, as long as preservation of physiological lumbar lordosis is maintained during the procedure.<sup>8</sup>

The correct level is localized by fluoroscopy prior to incision. A median longitudinal skin incision is performed in the midline, followed by two longitudinal incisions in the muscular aponeurosis, in general 1.5–2 cm from the midline. One central skin incision is more cosmetically desirable than two lateral incisions or even a transverse incision. A fingerbreadth dissection is made between the multifidus and the longissimus muscles laterally on either side. A retractor, such as a gelpi, and suture on the bilateral multifidus can be used to facilitate the visualization (▶ Fig. 1).<sup>9</sup>

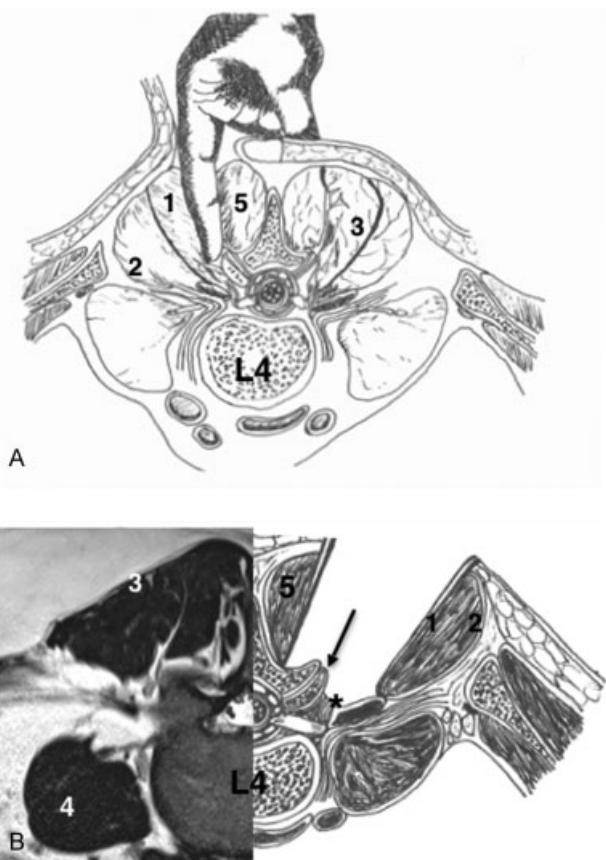
There is a natural cleavage plane between the multifidus and the longissimus muscles, a natural pathway. A finger can be inserted between these muscles at any point at or above the specific level. At the sacral level, the multifidus swings laterally, but it is a much bloodier approach, and there is muscular strain. The thoracic levels are already very thin<sup>10</sup> (▶ Fig. 2).

Little blood loss may occur. For better exposure, the gelpi retractors need to be repositioned frequently. Extra soft tissue in the bottom of the wound is removed. The laminae of the vertebrae to be fused are exposed well up onto the sloping basis of the adjacent spinous process. The lumbar transverse processes should also be denuded of soft tissue all the way up to their tips and well around their superior and inferior borders, for the visualization of anatomical landmarks like the pedicle and facet joint.<sup>11</sup>

We never place bone in front of the transverse processes. The spinal nerves are just in front of the transverse processes, and may be injured if the exposure is continued around anteriorly. Injury to these nerves is a lot more likely if bone is packed in this area. There seems to be little danger of



**Fig. 1** (A) Patient in prone position, with support on the face, chest, abdomen and lower limbs. (B) Posterolateral approach with midline longitudinal skin incision, followed by 2 longitudinal incisions in muscular aponeurosis, in general, 1.5–2 cm from the midline.



**Fig. 2** (A) The finger can be plunged between multifidus and the longissimus muscle creating one natural wall. Sacrospinalis is the name of the complex of longissimus, iliocostalis and sacrospinales. (B) Two retractors can be used to expose facet joint and pedicle. 1- M. (muscle) Longissimus, 2- M. Iliocostalis, 3- M. Sacrospinalis, 4- M. Psoas Major, 5 - Multifidus, \* - Pedicle, Black arrow - Facet joint.

damaging the spinal nerves if the dissection is kept posterior to the transverse processes, preserving the medial branch of the dorsal nerve. The lumbar arteries and veins pass just above the basis of the transverse processes and also at the angle of the medial point of the sacral spine. These often bleed profusely, and the bleeding can be difficult to stop with cautery. These bleeding areas can be plugged with a wad of surgicel (Ethicon, Sommerville, NJ, US). The vessels coming out of the superior sacral foramen may also bleed profusely, and the bleeding can also be stopped with surgicel.<sup>11</sup>

The surgicel can be removed before closing; however, no harm is done if a small wad of surgicel is left inadvertently. If one is to use cautery at this point, it should be the bipolar type, as unipolar cautery may damage the adjacent spinal nerve. Particular care should be taken not to remove the capsule or damage the adjacent joint at this level, and to preserve the facet joint; neither should the surgeon expose any part of the lamina of the vertebra immediately above the area to be fused. With these precautions taken, any tendency of the fusion to extend upward will be avoided since there will be no instability. Incidentally, we also believe that damage to these facets may account for some of the cases of spondylolisthesis and other problems seen as years go by at the upper ends of the fusions.<sup>12</sup>

Often times, there are not more than a few centimeters of area available for fusion, but every bit of that area should be used. Not only the lateral surfaces of the superior articular process, but the dorsal and lateral areas of the pars interarticularis should also be denuded. The laminae, as far medially as the bases of the spinous processes themselves are not exposed, thereby preserving their ligamentous attachments and some of their blood supply. Preservation of these midline structures and maintenance of adequate circulation and innervation are the main advantages of this approach.<sup>12</sup>

The intervertebral joints within the fusion area are exposed carefully. If the surgeon wishes, the posterior two-thirds of the joint cartilage can be removed. In the case of spondylolisthesis loose element, this cartilage joint should not be removed because this further destabilizes an already unstable area. In spondylolisthesis, always fuse the loose element to S1, since this loose element may rock about with the muscle contractions. Thus, it should be prepared with a rongeur. Never use a hammer and gouge, as they have been known to damage the underlying nerves.<sup>11</sup>

Before closure, any small tags of muscle are snipped off. The muscle itself is closed extremely loosely with small sutures. The fascia is closed securely.<sup>11,12</sup>

It is important to suture the skin edges to the underlying deep fascia, or blood and serum will collect under the portion of skin that has been undermined, and the area will balloon out. If this occurs, the blood and serum may need to be aspirated.<sup>11</sup>

The far lateral zone is defined as that area lateral to the pedicles. This is difficult to approach from the midline, but easily reached through a paraspinal approach. The laminae do not need to be exposed if the rupture is lateral to the pedicles. The medial half or two-thirds of the intertransverse muscle and ligament are removed.<sup>7,8,13</sup>

## Discussion

The Wiltse approach allows further instrumented fusion and decompression with minimal trauma, accurate identification of the natural cleavage plane between the multifidus and longissimus muscles, and reduced postoperative morbidity (→ Fig. 1). When using the Wiltse approach, we recommend performing: a preoperative magnetic resonance imaging (MRI) to plan the distance in skin incisions from the midline to each vertebral level; a computed tomography (CT) of the spine to evaluate bone viability; and dynamic bending and lateral radiographs to assess the mobility of the spaces to be manipulated during surgery.<sup>11</sup>

## Benefits<sup>14-17</sup>

- (1) Reduced chronic low back pain after surgery, with less muscle manipulation.
- (2) Reduces intraoperative damage due to the development of access roads and minimally invasive and less traumatic discectomy techniques.
- (3) Multifidus muscle preservation, vascularization and tissue innervation; optimal exposure of the pedicle does not require specific instruments.
- (4) Reduced length of surgical time.
- (5) It enables the removal of bone graft in the same incision, needs little traction, and causes less muscle ischemia while also providing accessibility to extraforaminal and lateral recess disc herniations.
- (6) The supra and interspinous ligaments are left intact, with less postoperative pain, no dead space, and low incidence of infection;

- (7) This approach is used for the classical herniated disc extraforaminal and lateral recess channel;
- (8) This approach is extremely useful for putting in pedicle screws since it makes aiming the screws medially very easy;
- (9) Through this approach the surgeon has freer access to laterally placed structures, and hence can decompress the nerves more easily than he can through the midline approach;
- (10) Vigorous retraction is not necessary, and hence there is less muscle ischemia;
- (11) Preservation of the nerve of the medial dorsal branch and its transverse spinal and interspinous branches, with superior and inferior anastomosis.
- (12) Useful for interbody fusion surgeries, like posterior lumbar interbody fusion (PLIF) and transforaminal lumbar interbody fusion (TLIF)
- (13) It can be useful for the correction of small deformities, but in more serious cases, it is sometimes necessary to utilize techniques like osteotomy, which can introduce more difficulties to the surgeon.

## Disadvantages<sup>14</sup>

- (1) Familiarity with the surgical approach is required;
- (2) Poor visibility;
- (3) Difficulty to enucleate the intervertebral disc and risk of root injury;
- (4) Tendency to lateralization at the point of entry;
- (5) Necessity to complement with another access if dural access is required.
- (6) It can be performed at thoracic levels, but more experience and familiarity with the anatomy are required. The multifidus muscle becomes thinner with each upward segment, giving the surgeon a greater chance of differentiating his laterality, but this represents a slightly greater technical difficulty. We recommend levels below T7/T8, despite the fact that the multifidus extends from the sacrum to the axis. In fact, low lumbar levels can be very thick and hamper the approach.

## Complications<sup>17,18</sup>

Some of the complications related to this surgical technique can be: infection, hematoma, loosening or breakage of the implants, kyphosis and facet dislocation, and pain disability. However, these complications are common to all surgeries.

## Postoperative Recommendations

The patients submitted to this access are instructed to remain supine for 24 hours, after which they are allowed to sit on the bed. The mean time of the hospital stay is three days. Prophylactic antibiotics and analgesia are commonly used. After three days, kinesiotherapy is started, and the patient can resume his/her daily activities. Rehabilitation starts in the second postoperative month, with exercises controlled by the physiotherapist. After the third month, the patient is referred to aerobics to start a supervised muscular recovery program.<sup>19,20</sup>

## Comparison between the Midline and the Muscle-splitting Approaches

Street and colleagues established, in 2016, with a retrospective study, that patients who underwent surgery performed with the paraspinal approach of Wiltse had decreased risk of wound breakdown and infection, reduced blood loss, and fewer reoperations than the patients submitted to the midline approach. The risk of adjacent segment failure in short posterior constructs is also lower with the Wiltse approach.<sup>20,21</sup>

Mukai and colleagues, in 2013, made a randomized study that was designed to elucidate the time course of the perioperative development of intramuscular multifidus muscle pressure after interfusion body surgery with midline dissection Wiltse approach resultant in low-back pain; however, pain did not differ between the 2 groups.<sup>22</sup>

Buttermann and colleagues, in 2015, mentioned that the midline and paraspinal approaches result in similar outcomes in two-level spinal fusions. They were unable to demonstrate that a paraspinal muscle-splitting approach to two-level fusions was superior to the muscle-stripping midline approach, or that the Wiltse approach was superior to the midline approach. However, the study had low statistical power.<sup>22</sup>

## Conclusion

The paraspinal approach to the lumbar spine was described 40 years ago by median skin incision with lateral muscle dissection between the multifidus and longissimus muscles, in natural pathway. A low rate of surgical complications such as infections, bleeding and postoperative pain have been observed, as well as good anatomy dissection to access the pedicle/facet joint, with less tissue damage and less tissue ischemia.

Even though some papers have controversies regarding the indications, the authors strongly encourage this approach, as they believe that, when well-indicated, the benefits outweigh the disadvantages and complications because it is a less invasive procedure.

## References

- 1 Watkins MB. Posterolateral bonegrafting for fusion of the lumbar and lumbosacral spine. *J Bone Joint Surg Am* 1959;41-A(03): 388–396
- 2 Mathieu P, Demirleau J. Surgical Therapy in painful spondylolisthesis. *Rev Chir Orthop Repar Appar Mot* 1936;23:352
- 3 Watkins MB. Posterolateral fusion in pseudarthrosis and posterior element defects of the lumbosacral spine. *Clin Orthop Relat Res* 1964;35(35):80–85
- 4 Ray CD. The paralateral approach to decompression for lateral stenosis and far lateral lesions of the lumbar spine. Chapter 29. *Lumbar Discectomy and Laminectomy*. Edited by Watkins. Collins, Aspen Publishers; 1987:217–227
- 5 Wiltse LL, Hutchinson RH. Surgical treatment of spondylolisthesis. *Clin Orthop Relat Res* 1964;35(35):116–135
- 6 Wiltse LL. The paraspinal sacrospinalis-splitting approach to the lumbar spine. *Clin Orthop Relat Res* 1973;(91):48–57
- 7 Wiltse LL, Spencer CW. New uses and refinements of the paraspinal approach to the lumbar spine. *Spine* 1988;13(06):696–706
- 8 Wiltse LL, Bateman JG, Hutchinson RH, Nelson WE. The paraspinal sacrospinalis-splitting approach to the lumbar spine. *J Bone Joint Surg Am* 1968;50(05):919–926
- 9 Wiltse LL, Guyer RD, Spencer CW, Glenn WV, Porter IS. Alar transverse process impingement of the L5 spinal nerve: the far-out syndrome. *Spine* 1984;9(01):31–41
- 10 Katz JN. Lumbar disc disorders and low-back pain: socioeconomic factors and consequences. *J Bone Joint Surg Am* 2006; 88(Suppl 2):21–24
- 11 Lin PM, Cautilli RA, Joyce MF. Posterior lumbar interbody fusion. *Clin Orthop Relat Res* 1983;(180):154–168
- 12 Wetzel FT, LaRocca H. The failed posterior lumbar interbody fusion. *Spine* 1991;16(07):839–845
- 13 Zindrick M, Wiltse LL, Assan S, Benson M. Symptomatic disc herniation lateral to the intervertebral foramen. (Scientific Exhibit). American Academy of Orthopaedic Surgeons, New Orleans, Louisiana, February 10–15, 1986
- 14 Rodríguez-Vela J, Lobo-Escolar A, Joven-Aliaga E, et al. Perioperative and short-term advantages of mini-open approach for lumbar spinal fusion. *Eur Spine J* 2009;18(08):1194–1201
- 15 Stremmel AV, Moosmann D, Stoss C. Stabilization of the degenerated lumbar spine in the nonfusion technique with cosmic posterior dynamic system. *WSJ* 2006;1:40–47
- 16 Wrugler-Hauri CC, Kalbarczyk A, Wiesli M, Landolt H, Fandino J. Dynamic neutralization of the lumbar spine after microsurgical decompression in acquired lumbar spinal stenosis and segmental instability. *Spine* 2008;33(09):1050
- 17 Freudiger S, Dubois G, Lorrain M. Dynamic neutralisation of the lumbar spine confirmed on a new lumbar spine simulator in vitro. *Arch Orthop Trauma Surg* 1999;119(3-4):127–132
- 18 Schmoelz W, Onder U, Martin A, von Stremmel A. Non-fusion instrumentation of the lumbar spine with a hinged pedicle screw rod system: an in vitro experiment. *Eur Spine J* 2009;18(10):1478–1485
- 19 Street JT, Andrew Glennie R, Dea N, et al. A comparison of the Wiltse versus midline approaches in degenerative conditions of the lumbar spine. *J Neurosurg Spine* 2016;25(03):332–338
- 20 Tsutsumimoto T, Shimogata M, Ohta H, Misawa H. Mini-open versus conventional open posterior lumbar interbody fusion for the treatment of lumbar degenerative spondylolisthesis: comparison of paraspinal muscle damage and slip reduction. *Spine* 2009;34(18):1923–1928
- 21 Mukai Y, Takenaka S, Hosono N, Miwa T, Fuji T. Intramuscular pressure of the multifidus muscle and low-back pain after posterior lumbar interbody fusion: comparison of mini-open and conventional approaches. *J Neurosurg Spine* 2013;19(06):651–657
- 22 Buttermann GR, Mullin WJ. Two-Level Circumferential Lumbar Fusion Comparing Midline and Paraspinal Posterior Approach: 5-Year Interim Outcomes of a Randomized, Blinded, Prospective Study. *J Spinal Disord Tech* 2015;28(09):E534–E543