

Brain Concussion: New Classifications and Current Physiopathological Knowledge of the Disease

Concussão cerebral: Novas classificações e conhecimento fisiopatológico atual da doença

Daniel Damiani^{1,2}  Durval Damiani³

¹Programa de Pós-Graduação em Neurociências, Universidade Anhembi Morumbi, São Paulo, SP, Brazil

²Programa de Pós-Graduação em Urgências e Emergências, Hospital Israelita Albert Einstein (HIAE), São Paulo, SP, Brazil

³Hospital das Clínicas, Faculdade de Medicina da Universidade de São Paulo (HCFMUSP), São Paulo, SP, Brazil

Address for correspondence Daniel Damiani, Rua Massacá 325, apto. 41, São Paulo, SP, 05465-050, Brazil (e-mail: dani.neurocirurgia@gmail.com).

Arq Bras Neurocir 2019;38:284–291.

Abstract

Keywords

- ▶ concussion
- ▶ brain trauma
- ▶ concussion management
- ▶ axonal injury

Resumo

Palavras-chave

- ▶ concussão
- ▶ traumatismo cranioencefálico
- ▶ manejo da concussão
- ▶ lesão axonal

The present review paper aims to update the definition and classification of cerebral concussion, highlighting its pathophysiological mechanisms. The high prevalence of cerebral concussion in emergency rooms around the world makes it necessary to know its proper management to avoid its late sequelae, which traditionally compromise cognitive aspects of behavior. New evidence on potential neuroprotective treatments is being investigated.

O presente artigo aborda, por meio de revisão bibliográfica, uma atualização acerca das novas definições e classificações da concussão cerebral, destacando seus mecanismos fisiopatológicos. A elevada prevalência da concussão cerebral nas salas de emergências de todo o mundo torna necessário o conhecimento do seu adequado manejo, a fim de se evitem suas sequelas tardias, que tradicionalmente comprometem aspectos cognitivos do comportamento. Novas evidências sobre potenciais tratamentos neuroprotetores estão sendo investigadas.

Introduction

At the beginning of the 20th century, Joseph Babinski had already shown interest in understanding the injury mechanism of cerebral concussions in World War I soldiers. Later, Derek Denny-Brown tried to describe the physiopathology of concussion.¹ The clinical scenario was uncertain, often coursing with transient symptoms, not attributed to cerebral lesions. Currently, cerebral concussion is defined as a complex physiopath-

ological cerebral process induced by external biomechanical forces that cause injuries. Originated by forces directed against the skull, face and/or neck, concussion typically results in rapid and transient neurological dysfunction, which resolves spontaneously and does not necessarily compromise the level of consciousness, as believed in the past. The symptoms of cerebral concussion are directly related to the intensity of the impact, reflecting functional and structural alterations. Until recently, no neuroimaging modality could “see” the brain

received
January 9, 2017
accepted
February 23, 2017

DOI <https://doi.org/10.1055/s-0037-1602691>.
ISSN 0103-5355.

Copyright © 2019 by Thieme Revinter Publicações Ltda, Rio de Janeiro, Brazil

License terms



injury caused by concussion. With the advent of tractography by magnetic resonance imaging, it was concluded that cerebral concussion compromises the integrity of the white matter.^{2,3} There are many symptoms of cerebral concussion, and they may compromise the level of consciousness, motricity, somatic sensitivity, the vestibular system, the psychic apparatus, oculomotricity and vegetative functions. The symptoms may present hours or even weeks after the traumatic injury, which hinders the emergency room professionals from defining its severity at the time the patients arrive at the hospital.^{2,4}

Currently, cerebral concussion is classified as possible, probable and defined. The lesion considered possible occurs when the patient has another clinical cause that better explains the symptoms and cannot be attributed to concussion as it was classically described. In this case, the injury mechanism cannot be clearly established. The symptoms include headache and fatigue during physical activities, which can be attributed to dehydration, migraine, hyperthermia or viral infections. In the lesions considered probable, the symptoms are no longer well explained by other causes than cerebral concussion, but there is presence of comorbidities, such as migraines, sleep disorders, anxiety, mood disorders and attention deficit hyperactivity disorder (ADHD). Finally, in the defined form, the symptoms can only be explained by cerebral concussion.⁵

Epidemiologically, over the last decades, there has been an increase in the prevalence of concussions in emergency rooms. In the United States, the prevalence is around 128/100,000 people.⁶ In the pediatric age group, the estimated incidence is around 304 cases for every 100,000 children, being higher in children between the ages of 5 and 9 years and in males.⁷ In the past 10 years, the incidence has increased by 200%, and this is largely attributed to the concussions resulting from playing sports, including football, soccer, hockey, martial-arts and general contact sports.^{8,9}

Objective

The present article describes the clinical management of cerebral concussion in the emergency room, taking into account the current concepts regarding its definition and classification, including the physiopathology of the injury.

Materials and Methods

A quantitative and descriptive research through a systematic review of the literature was conducted in the following databases: the Latin American and Caribbean Literature on Health Sciences (LILACS, in Portuguese), the National Library of Medicine (PubMed), the Scientific Electronic Library Online (SciELO), the Cochrane Library and the Excerpta Medica Database (EMBASE) in the month of July 2016. The following descriptors obtained from the medical subject headings (MeSH) were used: *concussion*; *brain concussion*; *concussion management*; *concussion and brain trauma*; *traumatic brain injury*; *axonal injury*; and *concussion in an emergency room*.

The following question guided the study: considering the new definitions and classifications for cerebral concussion,

how should it be managed in the emergency room to avoid its chronic consequences?

The inclusion criteria for the research were: updated publications from 2000 to 2016, written in Portuguese, Spanish and English, with access to the full text online. Duplicate articles were eliminated.

For the analysis of the articles included in the present review, the following aspects were observed: year of publication, type of periodical, place where the study was performed, methodology used, and main results.

Development

Injury Mechanism

Concussion is a brain injury triggered by a biomechanical mechanism described in the 20th century. The brain suffers a process of abrupt acceleration and deceleration, in the anteroposterior plane, often associated with rotational movements, colliding against the internal board of the skull, maintaining a relatively fixed point, the brainstem. The most recent studies have observed that in this closed traumatic mechanism there are electrophysiological alterations (compromising neuronal activity) in the ascending reticular activating system (ARAS) and in the diencephalon (→Fig. 1).¹⁰

Physiopathology: Neurometabolic Cascade

The animal models of moderate cranioencephalic trauma (CET) have revealed biochemical alterations compatible with cerebral concussion. The elucidation of the neurometabolic cascade involves cellular bioenergetic, cytoskeletal, and axonal alterations, neurotransmission impairment, delayed cell death, and chronic functional impairment.

Physiopathology of Cerebral Concussion: Acute Stage

Ionic influx and excitotoxicity. In the acute stage of the lesion, there are neuronal influxes of glutamate, calcium and sodium with potassium efflux, observed after the traumatic injury of the plasma membrane. Postconcussion syndrome is marked by a wave of cellular depolarization followed by a phenomenon similar to cortical spreading depression.

Alteration in cerebral blood flow self-regulation. Immediately after the concussion, there will be a reduction in cerebral blood flow, which may take days to normalize. The relative hypoxia occasioned will initiate the process of neuronal excitotoxic damage. The mechanism of reduction of blood flow comprises the loss of brain self-regulation sensitive to trauma, compromising the hypothalamic functions, leading to cellular energetic imbalance associated with sympathetic dysautonomia.

Energy crisis. In an extremely early postconcussion stage, there is an increase in energy consumption by ionic pumps, with relative reduction in the cerebral blood flow, resulting in an uncoupling of energy, that is, an imbalance between supply and cellular energy demand. Calcium influx is the most common and lasting ionic disorder, and is attenuated by mitochondrial calcium sequestration. However, this "blockade" will result in mitochondrial impairment regarding its oxidative metabolism. After this stage of initial hyperglycolysis with energy decoupling, the glycolytic metabolism will be

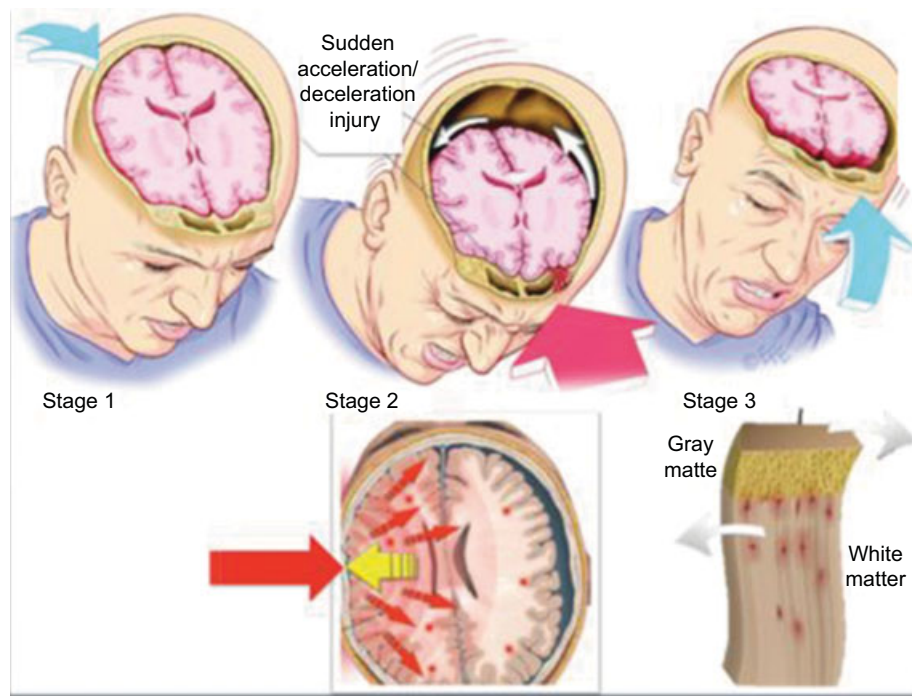


Fig. 1 Injury mechanism attributed to cerebral concussion. Note that there is an acceleration provided by an external force that closes instantaneously before a bulkhead (collision); however, the nervous tissue remains accelerated, colliding against the inner board of the skull, slowing abruptly, and performing a movement contrary to the initial one. At this moment, the heavier gray matter performs its movement slower compared with the white matter, promoting shearing, that is, the stretching of the nerve fibers.

compromised (hypometabolism) for ~ 7 to 10 days after the trauma.

Cytoskeletal injury. Biomechanical forces directed against neuronal and glial structures course with intra-axonal calcium inflow, neurofilament collapse and axonal integrity loss, compromising the anterograde and retrograde molecular flow.

Axonal dysfunction. The lesions to the microtubules and axonal neurofilaments can disrupt the cellular connections, evolving with complete functional loss. Recent studies have shown that non-myelinated axons are more susceptible to traumatic injuries, especially in the corpus callosum region. In the brain still under development, repeated traumatic lesions to the white matter often result in cognitive impairment.¹¹

Neurotransmission impairment. After traumatic injuries, alterations are observed in the subunits of the N-methyl-D-aspartate (NMDA) receptors, resulting in reduction in their electrophysiological, cognitive, and memory consolidation capacity. In animal models, several patterns of calcium inflow are observed, resulting in the activation of genes and phosphorylation that will modify the calcium/calmodulin-dependent signal transductions of protein kinase II (CaMKII), the extracellular signal-regulated kinase- (ERK), the cyclic adenosine monophosphate response element binding (CREB) protein, and the brain-derived neurotrophic factor (BDNF). The imbalance in the binomial excitation-inhibition is also associated with the loss of gamma-aminobutyric acid (GABAergic) interneurons, reflected by the drop in the glutamic acid decarboxylase (GAD67) marker (precursor of GABA synthesis) in the region of the amygdaloidal complex. The postconcussion clinical manifestations associated

with anxiety and posttraumatic stress disorder seem to be able to reduce this inhibition promoted by GABA.

Cerebral inflammation. After a moderate traumatic injury, there is activation of proinflammatory genes with microglia infiltration. When analyzed microscopically, the black substance of the mesencephalon has intense inflammatory activity, with excitotoxicity mediated by glutamate, corroborating with the physiopathological mechanism of posttraumatic Parkinson disease. The attenuation of the neuroinflammatory mechanism has been the target of several therapeutic proposals, since there is an increase in proinflammatory interleukin (IL), such as IL-6, tumor necrosis factor α (TNF α) and IL-1 β , and several substances are being tested, such as: lithium, N-acetylcysteine and minocycline, all with promising results.¹²⁻¹⁴

Cell death. Cell death is a final phenomenon in the process of traumatic brain injury observed in cerebral concussions, especially in recurrent lesions. It is not yet clear the exact moment when acute concussion injuries become chronic: hippocampal atrophies and loss of dopaminergic neurons, clinically manifested in the form of cognitive deficit, persistent headache, sleep disorders and reduction in concentration are observed (\rightarrow Fig. 2).^{15,16}

Physiopathology of Cerebral Concussion: Chronic Stage

The aspects regarding the chronification of the lesions associated with cerebral concussion are related to recurrent traumas. Studies with professionals who play contact sports reveal that successive, recurrent traumas are responsible for neuronal degenerative lesions, including the accumulation of

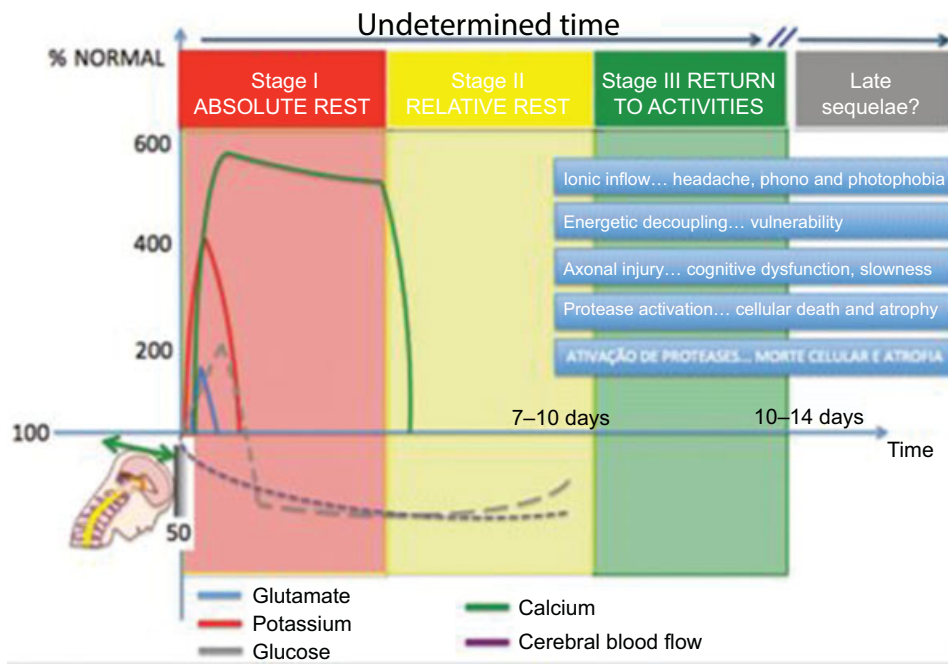


Fig. 2 Neurometabolic cascade associated with cerebral concussion. Note the temporal evolution of ionic disarrangements compromising neuron neurophysiology, which is related to the postconcussion clinical symptoms. Giza and Hovda¹⁷ describe three stages of cerebral concussion, and in the first two, the patient should stay at rest (absolute and relative respectively). However, the duration of the clinical stages of cerebral concussion is individualized. The figure only provides an approximate temporal mean for each of these phases, and clinical reevaluation is recommended. Chronically, cerebral concussions may lead to functional impairment, including ADHD, depression, psychoses, chronic headache, and even suicide. Modified from Giza and Hovda, 2014.¹⁷

tau protein. The early return to sports activities after a cerebral concussion aggravates the aforementioned metabolic damage (acute stage), inducing neuronal apoptosis. Studies with professional fighters demonstrated that the repetition of trauma, with strokes directed to the skull, evolve with cortical and hippocampal atrophy associated with ventriculomegaly. Animal studies reveal that a single severe cerebral concussion can result in chronic evolution of brain damage, with cell death and atrophy in one year.^{17,18}

The physiological protein degradation depends on the ubiquitin-proteasome system for its proper functioning, requiring energy in the form of adenosine triphosphate (ATP). Since there is energy decoupling due to a cerebral concussion, there will be failure of the ubiquitin-proteasome system, resulting in the accumulation of non-degradable toxic material, which is currently considered the precursor mechanism of posttraumatic neurodegeneration.^{19,20} There are several reports of cerebrospinal fluid (CSF) and tissue deposition of phosphorylated tau protein, in addition to extracellular amyloid and CSF deposits after cerebral concussion.²¹

As described, the chronic mechanisms triggered by cerebral concussion will manifest clinically in the form of a slowness in reasoning, loss of concentration, aggressiveness, impulsiveness, cognitive dysfunction, sleep alteration and emotional lability, including depression, which is a direct reflex of neurotransmission impairment. Tractography neuroimages can detect, already in early stages, the white-fiber compromise resulting from the concussion. It is not yet known to what extent an axonal injury can be repaired. Myelination seems to protect the axon against trauma; however, in repeated

concussions, with no time for axonal recovery, immature or even incomplete myelination, it is not possible to avoid the sequelae of the initial trauma.²²⁻²⁵

Symptomatology. Respecting the topography of the lesion. Any portion of the nervous system may be affected by cerebral concussion, leading to its characteristic clinical presentation. Several regions are commonly affected concomitantly, resulting in a wide variety of symptoms.

Cortical structures. Due to its anatomical location, the frontal lobe is frequently affected by concussion, presenting cognitive dysfunction. The diagnosis is made through neurocognitive and neuropsychological tests. The affected temporal lobe may present memory deficits with anterograde amnesia and impairment of the consolidation of long-term memory. During the verbal and visual memory tests, in more than 75% of the cases, positron emission tomography (PET) and single-photon emission tomography (SPET) present alterations. The lesions to the parietal lobe traditionally result in complex impairments, such as: aphasia, apraxia, alexia, agraphia, dyscalculia and dysesthesia.^{2,26}

Subcortical structures. The concussive lesions that affect the hypothalamus may be characterized by autonomic, endocrine, sexual (erectile) dysfunctions, as well as analgesic and circadian rhythm dysfunctions. Hypopituitarism is described as a lesion to the hypophysial stem, with consequent hormonal deficit, involving the adenohypophysis and the neurohypophysis. Damiani et al²⁷ describe that hypocortisolism may mimic postconcussion syndrome, and it should be considered in the clinical investigation.²⁷ Milroy et al²⁸ describe changes in the sleep-wake cycle, often manifested in the form of dyssomnias

and/or parasomnias resulting from cerebral concussion.²⁸ After trauma, appetite alterations can also be observed, often leading to central obesity due to hyperphagia and gastroparesis. Mortality increases significantly if there is central diabetes insipidus, compromising electrolyte balance, which must be controlled with desmopressin acetate (DDAVP, Ferring GmbH, Kiel, Germany).^{2,27} Lesions to the base cores may course with choreoathetosis, dystonia, chorea, hypertonic-hypokinetic movements, aphasia, hemiparesis and emotional lability.^{29,30}

Trigeminal-facial structure. One of the main symptoms associated with cerebral concussion is the presence of recurrent and persistent headache. The lesion often involves the trigeminal-vascular system, with subcortical cellular alteration. Headache has several characteristics, and may present in a migraine, tensional, cluster, occipital or supraorbital form. Commonly, headache is accompanied by nausea and vomiting, malaise and abdominal pain. The physiopathology of this type of headache involves injury to the trigeminal-vascular system associated with the distension of the dural vessels, with the presence of spreading depression. The treatment for postconcussion headache includes: biofeedback, psychotherapy, non-steroidal anti-inflammatory drugs, triptans, ergotamine, opioids, muscle relaxants and selective serotonin reuptake inhibitors.^{31,32}

Cerebellar structure. Purkinje cells are especially susceptible to blow-counterblow lesions, with neuronal loss in the first 24 hours after the trauma. The symptoms attributed to cerebellar lesions include: dysdiadochokinesia, positive Romberg test, dysmetria, intention tremor, dysphemia, motor incoordination and cognitive-affective dysfunction.³³

Clinical Management in the Emergency Room

The diagnosis of cerebral concussion is clinical. It is a lesion of diffuse nature, without focal manifestations upon clinical examination.³⁴ Loss of consciousness only occurs in ~ 10% of the cases, while anterograde and/or retrograde amnesia occurs in 30 to 50% of the cases. Headache occurs in most cases (~ 85%). It is noteworthy that the symptoms may not be present at the time of patient admission; they may appear hours after the trauma, or only be diagnosed after neurocognitive or neuropsychological tests.

In the emergency room, clinical measures should be established as a priority, according to the treatment protocols recommended by Advanced Trauma Life Support (ATLS), following this sequence: A (airway/cervical stabilization); B (respiration); C (circulation); D (neurological status); E (exposure). Once diagnosed or suspected, concussion should be handled with frequent clinical reassessments. Special attention should be given to those patients with lowering levels of consciousness (or prolonged periods of unconsciousness after head trauma), seizures, focal neurological signs and/or suspicion of cervical injury.

Due to the impact, there is a risk of subdural and extradural hematomas, bone fractures and/or cerebral contusion, with the need for neuroimaging exams, usually computed tomography (CT) of the skull without contrast. Less than 10% of the patients present bleeding in the neuroimaging exam, and less than 2% of them require neurosurgical intervention.⁵

Table 1 New Orleans and Canadian CT Head Rule criteria used as warning signs for indication of cranial computed tomography in cases of cerebral concussion

NEW ORLEANS CRITERIA — GLASGOW COMA SCALE 15
Headache
Vomit
Age > 60 years
Alcohol or drug intoxication
Persistent anterograde amnesia
Convulsion
Traumatic lesion to the soft tissues or bone lesion above the clavicle
CANADIAN CT HEAD RULE CRITERIA — GLASGOW COMA SCALE 13–15 FOR PATIENTS AGED ≥ 16 YEARS
✓HIGH risk of neurosurgical intervention:
Glasgow coma scale < 15 2 h after the trauma
Open or sinking cranial fracture
Cranial base fracture: rhino/otorrhea; raccoon eye; Battle
Two or more vomit episodes
Age > 65 years old
✓MODERATE risk of neurosurgical intervention
Retrograde amnesia ≥ 30 minutes
Injury mechanism: collision; vehicle ejection; fall > 1 m high; fall > 5 steps

In the clinical practice, two scales are recommended to evaluate these patients in the emergency room regarding the need for cranial CT: the New Orleans criteria and the Canadian CT Head Rule, both validated in prospective studies. The presence of at least one criterion in any of the scales is indicative of the need for a neuroimaging exam (► **Table 1**).^{10,35–37}

A useful tool developed for the diagnosis of cerebral concussion in sports is called Sport Concussion Assessment Tool, Third edition (SCAT3). It is a list of 22 relevant symptoms. In cases of suspicion of cerebral concussion, the presence of only one symptom concludes the diagnosis. A new scale called childSCAT3 was developed for children aged between 5 to 12 years with suspicion of cerebral concussion.³⁸

Patients with cerebral concussion diagnosis should remain at rest to reduce the cerebral metabolic demand, which could otherwise exacerbate cellular lesions.³⁹ The observation period will depend on the severity of the trauma, represented by the symptomatology presented. Patients with a normal neurological examination should be observed for ~ 2 hours.⁴⁰ It is always useful to leave written guidance on warning signs for the presence of intracranial lesions with later manifestations: intense headache, vomiting, dizziness, postural instability, or loss of fluid through the nose or ear. It should also be clear to the patient and caregivers that headache and irritability are absolutely frequent for a few days after cerebral concussion, and may manifest over the subsequent days, not being a cause for concern. Regarding the drowsiness that the patient may

present in the days after the trauma, it is also a common postconcussion sign, but it is still unclear whether waking the patient overnight has any benefits. It is recommended that patients do not return to their daily activities until the headache and malaise have improved.¹⁰

In the presence of new symptoms, such as hemiplegia, dizziness and drowsiness, after cerebral concussion, a clinical reassessment with neuroimaging is mandatory, to discard subdural and/or extradural hematomas. With the hypothesis of axial collections discarded, posttraumatic ischemic strokes should be considered, commonly due to traumatic injuries of the carotid and/or vertebral arteries. Once the aforementioned lesions have been discarded, the migraine-like phenomenon may be considered as an etiology for the new signs and symptoms.^{10,41,42}

Some neuroimaging findings may prolong the observation time, requiring the hospitalization of the patient. The presence of a small cerebral contusion or even discrete subarachnoid hemorrhage is observed in ~5% of the cases. Generally, these lesions do not result in functional impairment, only persistent headache, requiring that the patient be observed for a longer period (~12 hours on average). In the presence of intracranial lesions such as those mentioned, a neuroimaging evaluation is indicated for the comparison with the initial image.¹⁰

Management of postconcussion syndrome. This syndrome is characterized by a constellation of symptoms observed in victims of cerebral concussions in the days following trauma. Headache and irritability occur frequently, followed by dizziness, anterograde/retrograde amnesia and somnolence. About 25% of these patients still present symptoms 1 year after the concussion.

Anxiety and depression are described by more than one third of the victims, and are more intense in hypochondriac patients. Imbalance and dizziness reflect vestibular concussion, which can be evidenced in the vestibulo-ocular reflex (VOR) test.

The pharmacotherapy indicated for the victims of cerebral concussion is poorly studied. The use of medications that interfere little with the level of consciousness is recommended. Common analgesics are used for headache, and non-hormonal anti-inflammatory drugs should be avoided in the initial stage of the trauma, due to the potential risk of hemorrhage. Opioids should not be used, since they impair neuronal regeneration and are associated with chronic pain in patients. Labyrinth system depressants are used (preferably those with an associated antiemetic effect): promethazine, betahistine dihydrochloride, meclizine, diphenhydramine and flunarizine. Serotonin reuptake inhibitors are also widely used, however, with poorly-studied results. For individuals who already suffer from migraine and who develop chronic postconcussion headache, several drugs are used: triptans, anticonvulsants, β -adrenergic blockers, steroids and calcium channel blockers.^{5,10,43} Neuropsychological and neurocognitive approaches should be performed after the first week of trauma. Complaints of lack of attention, impulsiveness and hyperactivity are often already observed in this stage. Suicidal ideation is a possible consequence of cranial trauma, reinforcing the need for psychiatric follow-up.⁴⁴ Neuropsychological follow-up can be useful, as well as the prescription of psychostimulants.⁵

Temporal Classification of Concussions

Current studies classify cerebral concussions in stages (periods of time) of recovery based on the physiopathological knowledge and the neurometabolic cascade described before. However, the same authors consider that each individual has his/her own particularities, and this subdivision is only a generalization. In this context, stage I comprises a temporal variation of zero to 5 days, constituting a period in which the individual is unfit to return to his/her daily activities, and is usually very symptomatic, requiring analgesic medications. Stage II varies from 2 to 10 days, and the patient remains symptomatic, limiting his/her daily activities, restricting the workload, but already participating again in his/her routine. The return to studies should also be gradual, and the resting time is considered relative. Medications should be removed gradually. Ultimately, in stage III, which consists of a period ranging between 7 and 14 days, the patient no longer has symptoms related to cerebral concussion, and should no longer take medications. In those athletes who are victims of trauma, this is the ideal time to return to sports. Special attention should be given to those athletes who experience the symptoms of the concussion again when they return to their routines, and they should be instructed to do so more gradually. It is recommended that these athletes should initially be subjected to mild aerobic exercises, evolving to sport-specific exercises that require balance and movement control, and training in the field of play and without contact with opponents (minimizing possible new traumas), but, at the same time, improving their agility and cognition. Finally, after this evolution, and being asymptomatic, the athlete will be able to return to normal training and competition (→ Fig. 2).⁴⁵⁻⁴⁷

Drugs with Neuroprotective Potential

Once the physiopathological mechanisms involved in cerebral concussion have been recognized, several drugs become promising to interrupt the harmful neurometabolic cascade. The therapeutic targets include: reduction of glutamatergic excitotoxicity, limitation of the damage caused by the production of free radicals and lipid peroxidation, and, finally, reduction of the permeability caused by the breakdown of the blood-brain barrier. Since the 1980s, several studies have tested magnesium sulfate, calcium channel blockers, bradykinin inhibitors, immunoreceptor blockers, vitamins, anti-inflammatories and minerals, with frustrating results in humans.^{48,49} Despite previous results, some pharmacoprotective possibilities continue to be investigated:

1. Magnesium sulfate. Its action mechanisms include the blockage of N-methyl-D-aspartate (NMDA) glutamate receptors and calcium-dependent receptors, and reduction of the neuroinflammatory cascade associated with cranioencephalic trauma. However, in human studies, there was an increase in mortality.
2. Progesterone. This drug can reduce the oxidative stress to the cell membranes, with decreased lipid peroxidation and blood-brain barrier breakage. Recent studies,

however, have shown no benefit of their administration in humans.

3. Erythropoietin. This hormone has potential neuroprotective activity by several mechanisms, and continues to be investigated for its best form of administration in cases of CET.
4. Ziconotide (SNX-111; Prialt) is an atypical analgesic agent for the amelioration of severe and chronic pain. These are drugs that act in the reduction of calcium accumulation in the cerebral cortex and in the white matter, including the restoration of mitochondrial function. However, clinical studies have been interrupted due to the increased mortality in humans. Calcium antagonists with greater selectivity, such as SNX-185, continue to be investigated.
5. Substance P and neurokinin A receptor antagonists. They are drugs with neuroprotective potential, because they reduce cellular edema, as well as capillary permeability, with improved motor and cognitive functions after CET. Clinical studies are still underway.
6. Minocycline. An antibiotic with a post-CET immunomodulator effect, as well as antioxidant and anti-inflammatory effects. Studies are underway to prove its efficacy in humans.
7. Cyclosporine. It is an immunosuppressant with neuroprotective effects, because it stabilizes the mitochondrial function, reducing the production of free radicals and preventing the cellular calcium inflow. In animal models, there are proven benefits of cyclosporine in cases of CET; however, in humans, its benefits are still being investigated.^{48,50}
8. Toll-like receptors. They are receptors of the immunologic innate response that activate the intracellular inflammatory cascade. The blockade of these receptors is being investigated with potential benefits in cases of CET.^{48,51}
9. Vitamins, minerals and antioxidant agents (omega-3). These drugs, including B-complex vitamins and nicotinamide, showed benefits in animal models, reducing cortical lesion and inflammation. They still need studies that prove their efficacy in humans.
10. Micronutrients (zinc and magnesium). Both zinc and magnesium are necessary for proper cell functioning, and their neuroprotective effect after CET is still being investigated.⁴⁸

Conclusion

The clinical diagnosis of cerebral concussion is often difficult. The symptoms are extremely varied, and go beyond the classic compromise of the level of consciousness. The injury mechanism involves the sudden acceleration and deceleration with axonal shearing, which can irreversibly compromise the cortical functioning. In the present work, the authors present the cellular alterations resulting from cerebral concussion and its potential treatment in the emergency room. To date, the physiopathological correlated mechanism did not have a recommended therapeutic algorithm. The relative or absolute physical and cognitive rest in the first days protects the nervous system from the phenomenon of the "second lesion." Anti-inflammatories should be avoided due to the risk of bleeding, and analgesia should be recommended for symptomatic relief. The patient should maintain

the rest at the discretion of the clinician, and should be alerted to the fact that the symptoms may arise in the first hours after the trauma. New pharmacological possibilities are being studied for early intervention to minimize the possible cognitive sequelae.

Conflicts of Interest

The authors have none to declare.

References

- 1 Bogousslavsky J, Tatu L. French neuropsychiatry in the Great War: between moral support and electricity. *J Hist Neurosci* 2013;22(02):144-154
- 2 Toledo E, Lebel A, Becerra L, et al. The young brain and concussion: imaging as a biomarker for diagnosis and prognosis. *Neurosci Biobehav Rev* 2012;36(06):1510-1531
- 3 McCrory P. Sports concussion and the risk of chronic neurological impairment. *Clin J Sport Med* 2011;21(01):6-12
- 4 Sharp DJ, Jenkins PO. Concussion is confusing us all. *Pract Neurol* 2015;15(03):172-186
- 5 Kutcher JS, Giza CC. Sports concussion diagnosis and management. *Continuum (Minneapolis)* 2014;20(6 Sports Neurology):1552-1569
- 6 Bazarian JJ, McClung J, Shah MN, Cheng YT, Flesher W, Kraus J. Mild traumatic brain injury in the United States, 1998-2000. *Brain Inj* 2005;19(02):85-91
- 7 Koepsell TD, Rivara FP, Vavilala MS, et al. Incidence and descriptive epidemiologic features of traumatic brain injury in King County, Washington. *Pediatrics* 2011;128(05):946-954
- 8 McCreary M, Hammeke T, Olsen G, Leo P, Guskiewicz K. Unreported concussion in high school football players: implications for prevention. *Clin J Sport Med* 2004;14(01):13-17
- 9 Clay MB, Glover KL, Lowe DT. Epidemiology of concussion in sport: a literature review. *J Chiropr Med* 2013;12(04):230-251
- 10 Ropper AH, Gorson KC. Clinical practice. Concussion. *N Engl J Med* 2007;356(02):166-172
- 11 Giza CC, Maria NS, Hovda DA. N-methyl-D-aspartate receptor subunit changes after traumatic injury to the developing brain. *J Neurotrauma* 2006;23(06):950-961
- 12 Siopi E, Cho AH, Homsy S, et al. Minocycline restores sAPP α levels and reduces the late histopathological consequences of traumatic brain injury in mice. *J Neurotrauma* 2011;28(10):2135-2143
- 13 Chen G, Shi J, Hu Z, Hang C. Inhibitory effect on cerebral inflammatory response following traumatic brain injury in rats: a potential neuroprotective mechanism of N-acetylcysteine. *Mediators Inflamm* 2008;2008:716458
- 14 Yu F, Wang Z, Tchantchou F, Chiu CT, Zhang Y, Chuang DM. Lithium ameliorates neurodegeneration, suppresses neuroinflammation, and improves behavioral performance in a mouse model of traumatic brain injury. *J Neurotrauma* 2012;29(02):362-374
- 15 Koenigs M, Huey ED, Raymond V, et al. Focal brain damage protects against post-traumatic stress disorder in combat veterans. *Nat Neurosci* 2008;11(02):232-237
- 16 Hutson CB, Lazo CR, Mortazavi F, Giza CC, Hovda D, Chesselet MF. Traumatic brain injury in adult rats causes progressive nigrostriatal dopaminergic cell loss and enhanced vulnerability to the pesticide paraquat. *J Neurotrauma* 2011;28(09):1783-1801
- 17 Giza CC, Hovda DA. The new neurometabolic cascade of concussion. *Neurosurgery* 2014;75(04, Suppl 4):S24-S33
- 18 Smith DH, Chen XH, Pierce JES, et al. Progressive atrophy and neuron death for one year following brain trauma in the rat. *J Neurotrauma* 1997;14(10):715-727
- 19 Wan C, Chen J, Hu B, et al. Downregulation of UBE2Q1 is associated with neuronal apoptosis in rat brain cortex following traumatic brain injury. *J Neurosci Res* 2014;92(01):1-12

- 20 Hawkins BE, Krishnamurthy S, Castillo-Carranza DL, et al. Rapid accumulation of endogenous tau oligomers in a rat model of traumatic brain injury: possible link between traumatic brain injury and sporadic tauopathies. *J Biol Chem* 2013;288(23):17042–17050
- 21 Magnoni S, Esparza TJ, Conte V, et al. Tau elevations in the brain extracellular space correlate with reduced amyloid- β levels and predict adverse clinical outcomes after severe traumatic brain injury. *Brain* 2012;135(Pt 4):1268–1280
- 22 Johnson VE, Stewart W, Smith DH. Axonal pathology in traumatic brain injury. *Exp Neurol* 2013;246:35–43
- 23 Tang-Schomer MD, Johnson VE, Baas PW, Stewart W, Smith DH. Partial interruption of axonal transport due to microtubule breakage accounts for the formation of periodic varicosities after traumatic axonal injury. *Exp Neurol* 2012;233(01):364–372
- 24 Prins ML, Hales A, Reger M, Giza CÇ, Hovda DA. Repeat traumatic brain injury in the juvenile rat is associated with increased axonal injury and cognitive impairments. *Dev Neurosci* 2010;32(5-6):510–518
- 25 Longhi L, Saatman KE, Fujimoto S, et al. Temporal window of vulnerability to repetitive experimental concussive brain injury. *Neurosurgery* 2005;56(02):364–374, discussion 364–374
- 26 Stulemeijer M, Vos PE, van der Werf S, van Dijk G, Rijpkema M, Fernández G. How mild traumatic brain injury may affect declarative memory performance in the post-acute stage. *J Neurotrauma* 2010;27(09):1585–1595
- 27 Damiani D, Baptistini BÇ, Damiani D. Impacto do traumatismo cranioencefálico nas funções adeno e neuroipofisárias. *Pediatr Mod* 2008;44(05):186–191
- 28 Milroy G, Dorris L, McMillan TM. Sleep disturbances following mild traumatic brain injury in childhood. *J Pediatr Psychol* 2008;33(03):242–247
- 29 Yilmaz S, Pekdemir M, Sarisoy HT, Yaka E. Post-traumatic cerebral infarction: a rare complication in a pediatric patient after mild head injury. *Ulus Travma Acil Cerrahi Derg* 2011;17(02):186–188
- 30 Landi A, Marotta N, Mancarella C, Marruzzo D, Salvati M, Delfini R. Basal ganglia stroke due to mild head trauma in pediatric age - clinical and therapeutic management: a case report and 10 year literature review. *Ital J Pediatr* 2011;37:2
- 31 Evans RW. Persistent post-traumatic headache, postconcussion syndrome, and whiplash injuries: the evidence for a non-traumatic basis with an historical review. *Headache* 2010;50(04):716–724
- 32 Levy D, Strassman AM, Burstein R. A critical view on the role of migraine triggers in the genesis of migraine pain. *Headache* 2009;49(06):953–957
- 33 Damiani D, Gonçalves VP, Kuhl L, Aloï PH, Nascimento AM. Aspectos funcionais do cerebelo: o fim de um dogma. *Arq Bras Neurocir* 2016;35:39–44
- 34 Tator CH. Concussions and their consequences: current diagnosis, management and prevention. *CMAJ* 2013;185(11):975–979
- 35 Haydel MJ, Preston CA, Mills TJ, Luber S, Blaudeau E, DeBlieux PM. Indications for computed tomography in patients with minor head injury. *N Engl J Med* 2000;343(02):100–105
- 36 Stiell IG, Wells GA, Vandemheen K, et al. The Canadian CT Head Rule for patients with minor head injury. *Lancet* 2001;357(9266):1391–1396
- 37 Smits M, Dippel DW, de Haan GG, et al. External validation of the Canadian CT Head Rule and the New Orleans Criteria for CT scanning in patients with minor head injury. *JAMA* 2005;294(12):1519–1525
- 38 Echlin PS, Tator CH, Cusimano MD, et al. A prospective study of physician-observed concussions during junior ice hockey: implications for incidence rates. *Neurosurg Focus* 2010;29(05):E4
- 39 Wetjen NM, Pichelmann MA, Atkinson JL. Second impact syndrome: concussion and second injury brain complications. *J Am Coll Surg* 2010;211(04):553–557
- 40 Blostein P, Jones SJ. Identification and evaluation of patients with mild traumatic brain injury: results of a national survey of level I trauma centers. *J Trauma* 2003;55(03):450–453
- 41 Sakas DE, Whitwell HL. Neurological episodes after minor head injury and trigeminovascular activation. *Med Hypotheses* 1997;48(05):431–435
- 42 Ryan LM, Warden DL. Post concussion syndrome. *Int Rev Psychiatry* 2003;15(04):310–316
- 43 Mittenberg W, Canyock EM, Condit D, Patton C. Treatment of post-concussion syndrome following mild head injury. *J Clin Exp Neuropsychol* 2001;23(06):829–836
- 44 Fralick M, Thiruchelvam D, Tien HÇ, Redelmeier DA. Risk of suicide after a concussion. *CMAJ* 2016;188(07):497–504
- 45 Giza CÇ, Difiore JP. Pathophysiology of sports-related concussion: an update on basic science and translational research. *Sports Health* 2011;3(01):46–51
- 46 Baugh CM, Kroshus E. Concussion management in US college football: progress and pitfalls. *Concussion* 2016;1(01):CNC6
- 47 Giza CÇ, Kutcher JS, Ashwal S, et al. Summary of evidence-based guideline update: evaluation and management of concussion in sports: report of the Guideline Development Subcommittee of the American Academy of Neurology. *Neurology* 2013;80(24):2250–2257
- 48 Neal MT, Wilson JL, Hsu W, Powers AK. Concussions: What a neurosurgeon should know about current scientific evidence and management strategies. *Surg Neurol Int* 2012;3:16
- 49 Schouten JW. Neuroprotection in traumatic brain injury: a complex struggle against the biology of nature. *Curr Opin Crit Care* 2007;13(02):134–142
- 50 Lulic D, Burns J, Bae EÇ, van Loveren H, Borlongan CV. A review of laboratory and clinical data supporting the safety and efficacy of cyclosporin A in traumatic brain injury. *Neurosurgery* 2011;68(05):1172–1185, discussion 1185–1186
- 51 Hua F, Wang J, Ishrat T, et al. Genomic profile of Toll-like receptor pathways in traumatically brain-injured mice: effect of exogenous progesterone. *J Neuroinflammation* 2011;8:42