




Meningioma of the Fourth Ventricle: Literature Review*

Meningioma do quarto ventrículo: Revisão da literatura

Allan Dias Polverini¹ Rodrigo de Almeida Simon Sola¹  Guilherme Fonseca Bortoluzzi¹
Ismael Augusto Silva Lombardi¹ Giusepe Picone Junior¹ Carlos Roberto de Almeida Junior¹
Carlos Afonso Clara¹

¹ Department of Neurosurgery, Hospital de Amor, Barretos, SP, Brazil
Arq Bras Neurocir 2020;39(1):5–11.

Address for correspondence Rodrigo de Almeida Simon Sola, MSc,
Rua Coronel Bento, 394, Vilas Boas, Campo Grande, MS, 79051-110,
Brazil (e-mail: rodssola@gmail.com).

Abstract

Meningiomas are among the most common central nervous system tumors, with an incidence that ranges from 15% to 40% of intracranial tumors. Of these, only 0.5% to 3% are intraventricular, and the rarest of them occurs in the fourth ventricle.

Fourth-ventricle meningiomas originate generally from the choroid plexus and have no dural adhesions. Most often, they manifest in young patients, around 41 years of age, with a possible predominance in females, through intracranial hypertension and cerebellar syndromes. The treatment consists of surgical resection, which commonly presents good results due to the characteristics of the tumor. So, for better preoperative planning, the radiological differentiation of the most frequent tumors in this location is important.

The most common histologic subtypes are fibroblastic and meningothelial, both grade I according to the World Health Organization (WHO), although there are reports of tumors of grades II and III.

We report a case of meningioma of the fourth ventricle operated in our institution, and we have conducted a literature review, through which we found that 57 cases have been reported so far, with the first one reported in 1938.

Keywords

- ▶ meningioma
- ▶ fourth ventricle
- ▶ infratentorial neoplasms

Resumo

Os meningiomas estão entre as neoplasias mais comuns do sistema nervoso central, com incidência que pode variar entre 15% e 40% dos tumores intracranianos. Apenas 0,5 a 3% deles são intraventriculares, dos quais os mais raros são os do quarto ventrículo. Os meningiomas do ventrículo IV se originam, geralmente, do plexo coroide, e não têm aderências durais. Na maioria das vezes, manifestam-se em pacientes jovens, em torno dos 41 anos, com possível predominância no sexo feminino,

* Work developed at the Orthopedics and Traumatology Service, Centro Médico Hospitalar de Vila Velha (CMHVV), Vila Velha, ES, Brazil.



Palavras-chave

- ▶ meningioma
- ▶ quarto ventrículo
- ▶ neoplasias infratentoriais

por meio de síndromes de hipertensão intracraniana e cerebelar. O tratamento consiste em ressecção cirúrgica, que, comumente, apresenta bons resultados devido às características tumorais. Por isso, para um melhor planejamento pré-operatório, faz-se importante a diferenciação radiológica entre os tumores mais frequentes nessa região.

Os subtipos histológicos mais comuns são fibroblástico e meningotelial, ambos de grau I da Organização Mundial da Saúde (OMS), embora existam relatos de tumores de grau II e III.

Relatamos um caso de meningioma do ventrículo IV operado em nossa instituição, e realizamos revisão da literatura, mediante a qual verificamos que foram relatados 57 casos até o momento, sendo o primeiro de 1938.

Introduction

Meningiomas are meningotheial neoplasms that originate in the arachnoid fibroblast, a squamous cell that covers the arachnoid villi and the Pacchioni granulations. They correspond to at least 15% of all intracranial neoplasms,¹ but may reach 40%,² and are classically adhered to meningeal structures.

Purely intraventricular lesions are rare and have a calculated incidence between 0.5% and 3% of intracranial meningiomas.² Out of these, 77.8% occur in the lateral ventricle trigone, with a higher frequency on the left side; 15.6% occur in the third ventricle; and 6.6%, in the fourth ventricle.^{1,3,4}

It is believed that the meningiomas in the fourth ventricle originate from the choroid plexus, and do not present dural adhesions.^{1,3,5} The first case was described by Cushing and operated by Sachs in 1938.^{3,6,7}

We describe the case of a 31-year-old patient, who was operated at our service for resection of a tumor in the fourth ventricle whose anatomopathological diagnosis indicated meningioma; we also performed a review of the literature.

Case Report

A 31-year-old male patient, from the city of Caçu, state of Goiás, Midwestern Brazil, was referred to Hospital de Amor, in the city of Barretos, with a vertiginous condition that had been progressing for ~ 8 months, associated with nausea and malaise. Upon neurological examination, he manifested dysfunction of cranial nerves IX, X, XI and XII and cerebellar syndrome, which presented in the form of dysbasia, ataxia and dysmetria, and was more pronounced on the left side. The subsequent investigation, with magnetic resonance imaging (MRI) (→Figs. 1, 2 and 3), revealed a solid lesion of lobulated contour and intense enhancement after injection of a paramagnetic contrast medium in the Luschka foramen topography to the left and fourth ventricle. The lesion had thin cerebrospinal fluid fissure between the cerebellar vermis and the tumoral plane, with 4.7 × 4.0 cm in its major axes, compressing the bulb, without contact with adjacent meninx, with no dural tail identification. There was also a slight dilation of the supratentorial cerebral ventricles.

A bilateral suboccipital craniotomy was performed, with the installation of an external ventricular bypass and total macroscopic excision of the lesion (→Figs. 4, 5 and 6), without interurrences. During the intraoperative period, absence of tumor adhesions to the meningeal structures of the posterior fossa was confirmed. A microsurgical resection of the lesion was performed, and we opted for intralesional emptying with the aid of ultrasonic aspiration, followed by resection in fragments of the tumor remnant, without the use of electrophysiological monitoring, which was not available at the time, and avoiding traction maneuvers. Total macroscopic resection of the neoplasm was achieved.

In the postoperative period, the condition evolved with worsening of the dysfunctions of cranial nerves IX, X and XI and grade-III hemiparesis to the left, presenting a slow and progressive improvement. The patient underwent early tracheostomy and gastrostomy.

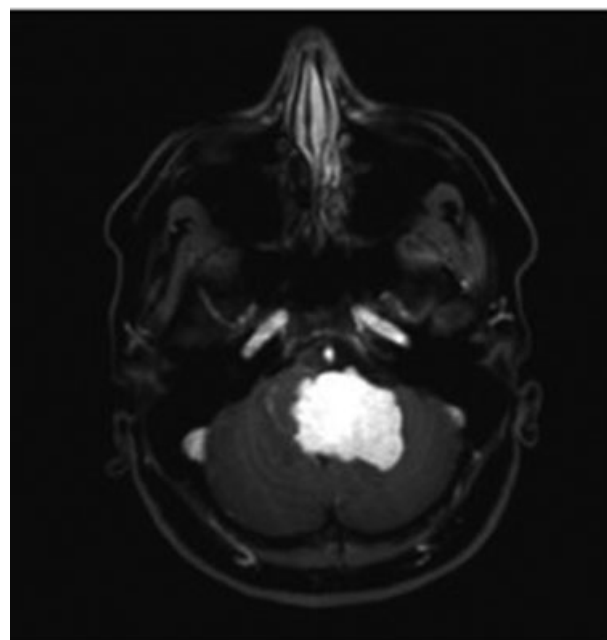


Fig. 1 Encephalon T1-weighted MRI scan with contrast showing tumor mass in the region of the fourth ventricle, with homogeneous enhancement and significant mass effect on the brainstem in the axial section.

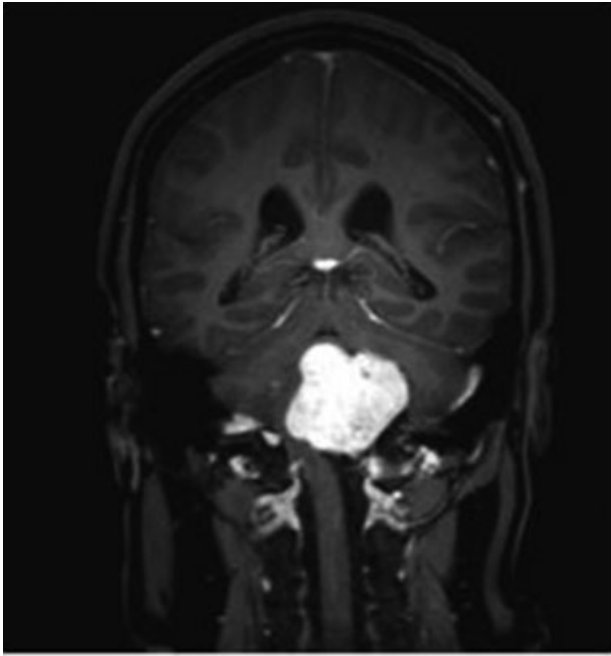


Fig. 2 Encephalon T1-weighted MRI scan with contrast showing tumor mass in the region of the fourth ventricle, with homogeneous enhancement and significant mass effect on the brainstem in the coronal section.

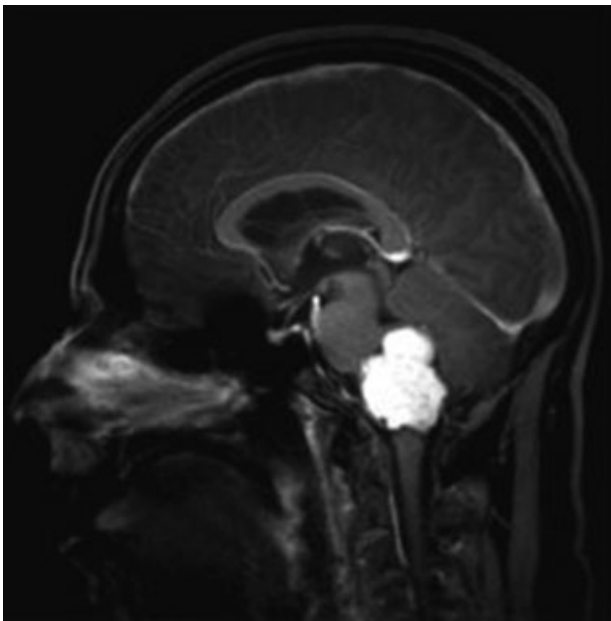

Fig. 3 Encephalon T1-weighted MRI scan with contrast demonstrating tumor mass in the region of the fourth ventricle, with homogeneous enhancement and an important mass effect on the brainstem in the sagittal section.

A picture of bronchopneumonia was diagnosed, with probable aspiration etiology, and urinary tract infection, which were treated satisfactorily, in addition to cerebrospinal fluid fistula associated with hydrocephalus, which was readily treated with a ventricular-peritoneal shunt (VPS) during the same hospitalization. The patient evolved with prolonged hospitalization and was enrolled into an intensive physical rehabilitation program.

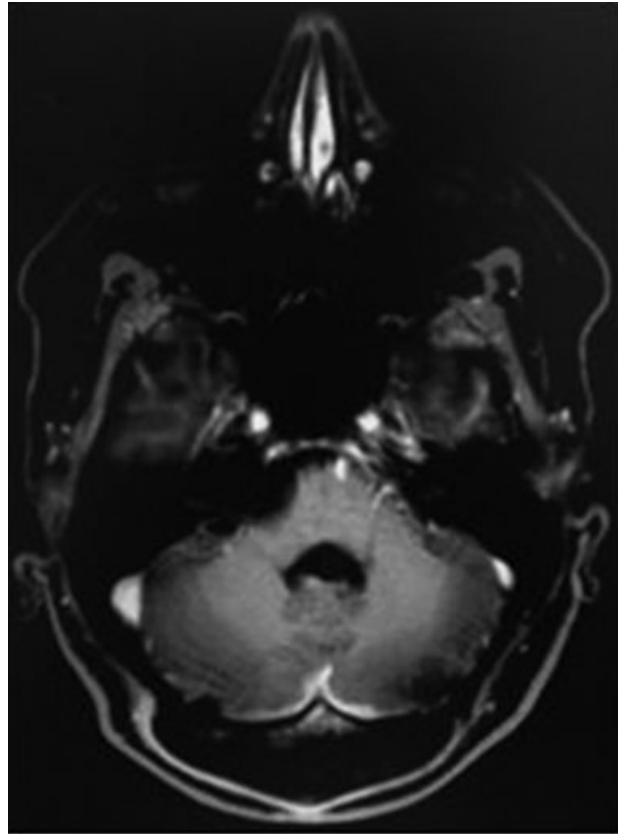


Fig. 4 Postoperative encephalon T1-weighted MRI scan with contrast in the axial section, showing complete resection of the tumor lesion, with centralization of the brainstem and free fourth ventricle.

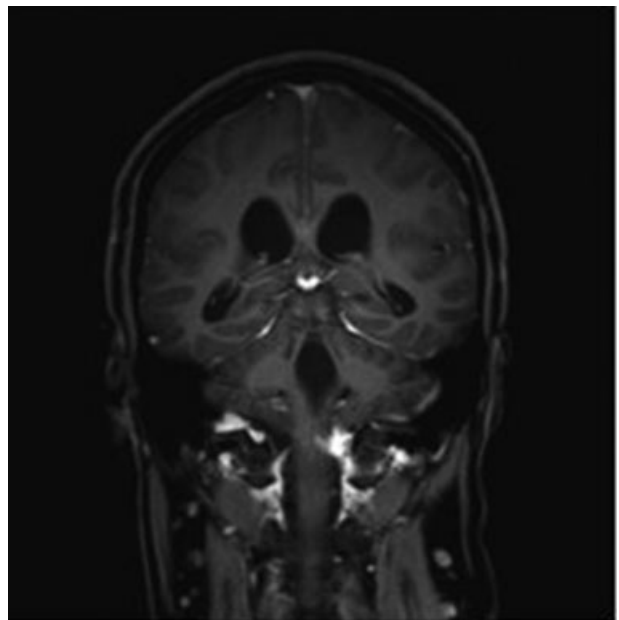


Fig. 5 Postoperative encephalon T1-weighted MRI scan with contrast in the coronal section, showing complete resection of the tumor lesion, with centralization of the brainstem and free fourth ventricle.

The patient followed with progressive improvement of the deficits after hospital discharge, and, around 9 months after the procedure, presented complete recovery of the

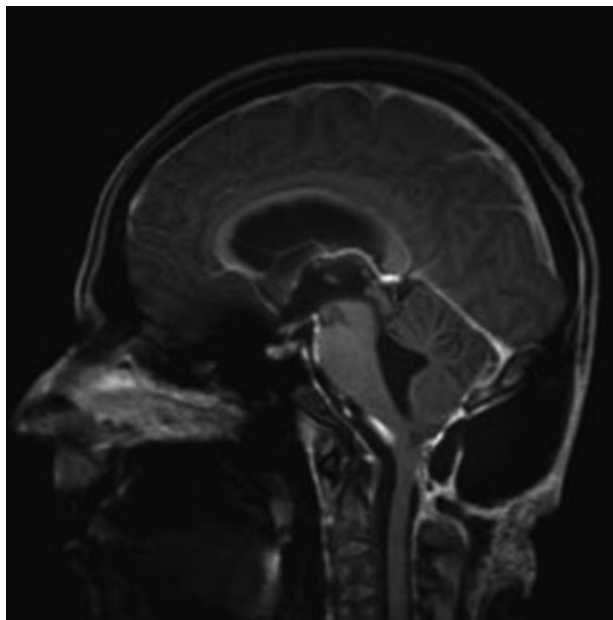


Fig. 6 Postoperative encephalon T1-weighted MRI scan with contrast, in the sagittal section, showing complete resection of the tumor lesion, with centralization of the brainstem and free fourth ventricle.

cranial nerve impairment, significant reversal of motor deficit, and significant improvement in the ataxic frame, maintaining a slight incoordination on the left side.

The histopathologic study revealed that it was a fibroblastic meningioma, grade I according to the World Health Organization (WHO). After 2 years of follow-up, he was referred to the hospital service in his hometown due to dysfunction of the DVS and history of viral meningitis treated in that city months before. The patient was then diagnosed again with meningitis and presented rapid worsening in the clinical condition due to sepsis, which caused his death despite the treatment.

Discussion

Meningiomas of the fourth ventricle are defined as those that have their origin in the local choroid plexus and occupy this ventricular cavity without meningeal implantation.^{1,3,5} In 1963, Abraham and Chandy suggested a classification for posterior fossa meningiomas, without dural implant, consisting of three types: 1) choroid plexus meningiomas, which develop only in the fourth ventricle; 2) choroid screen meningiomas, which develop partially in the interior of the ventricle and partially in the cerebellar hemisphere and vermis; and 3) cisterna magna meningiomas, without dural implantation and with intraventricular extension, which are originate from the most lateral portion of the choroid plexus, outside the Luschka foramen.^{1,8,9} Those classified as types 1 or 2 are deemed true. The case herein reported is an example of ventricle meningiomas classified as Abraham type I, as there is evidence of cerebrospinal fluid fissure between the vertex and the medial portion of the right cerebellar hemisphere with the tumor interface, as well as a more lateralized disposition of the neoplasia on the left.

Some published series have reported a prevalence of female patients, with a 2:1 ratio.^{1,4,10} In this review, we noted an equivalent distribution between genders, with a slight prevalence of females, with 28 cases (48.28%). There were 25 male cases (43.10%), and there was no identification of gender in 5 cases (8.62%).

The overall mean age of the reported cases is 41.64 years old. When analyzed separately by gender, the mean age is discretely different: the female gender is slightly younger (mean age: 41.25 years) than the male gender (mean age: 42.08 years). Some publications suggest a higher incidence in younger female patients.¹

Patients with fourth-ventricle meningiomas usually manifest signs of insidious intracranial hypertension (IH), such as morning headache, nausea, vomiting and vertigo, as well as focal signs most commonly characterized by ataxic syndrome (cerebellar), long tracts,^{2,3,10} and cranial nerve involvement, notably those whose nuclei are located in the point-bulbar segment of the brainstem, such as the presently reported case.

Among the differential diagnosis of fourth-ventricle tumors are metastasis, choroid plexus papilloma, hemangioblastoma, medulloblastoma and ependymoma.^{3,5,11} The radiological differentiation of such lesions is important for the surgical planning, because it implies different levels of difficulty for total excision and, therefore, different initial forms of intraoperative management of the lesions. The characteristics of meningiomas, both in the MRI and in computed tomography (CT), indicate well-circumscribed lesions with regular and mild edges, probably of slow growth, with homogeneous and very intense enhancement by the contrast agent.^{3,6}

The treatment of choice is the microsurgical excision of the lesion, using intralesional emptying, with aid, if possible, given the characteristics of the neoplasia, ultrasonic aspiration or piecemeal resection when necessary, initially avoiding traction maneuvers, and paying special attention to the dissection along the floor of the fourth ventricle, usually with a clear cleavage plane, which, together with the fact that it does not present meningeal fixation, leads to the good results published in the literature, with complete excision of the lesion.¹² Considering the cases with resection volumes reported so far, only four did not indicate complete resection.

Data from the international literature suggest the prevalence of the fibroblastic and meningothelial subtypes, corresponding respectively to 40% and 24% of the cases.¹ In our review, the subtypes classified as WHO grade I correspond to 79.31% of the cases, with a prevalence of fibroblastic (29.31%) and meningothelial (15.52%) meningiomas.

Meningiomas classified as WHO grade II correspond to 17.24% of the cases, with a prevalence of clear cell (6.89%) and atypical (6.89%) meningiomas. Chordoid meningiomas corresponded to 3.44% (3) of the reported cases.^{13,14} Only one anaplastic meningioma (WHO grade III) was reported, whose diagnosis was established in the recurrence of the disease after a long period of remission.¹⁵ The histopathologic classification of the lesion was not available in 5 (8.62%) reported cases.

Through research in the database of indexed journals, as shown in **Table 1**, we detected the existence of 57 cases of

Table 1 Cases reported in the international literature

Case	Publication	Author	Year	Age	Gender	Resection	Histology
1	1	Sachs et al ^{1,3,8,11,18-20}	1938	38	Female	Total	Fibroblastic
2	2	Voguel and Stevenson ⁷	1950	65	Male	Necropsy	Meningothelial
3	3	Haas and Ritter ¹⁶	1954	41	Male	Necropsy	Not available
4	4	Bustamente Zuleta and Londono ¹⁷	1955	12	Male	Subtotal	Laminar trend
5	4	Bustamente Zuleta and Londono ¹⁷		8	Male	Biopsy	Diffuse
6	5	Schaerer and Woosley ¹⁸	1960	42	Female	Total	Not available
7	6	Chafee and Donaghy ¹⁹	1963	38	Female	Total	Meningothelial
8	7	Hoffman et al ²⁰	1972	61	Male	Total	Transitional
9	7	Hoffman et al ²⁰		44	Female	Total	Transitional
10	8	Rodrigues- Carbajal and Palacios ²¹	1974	49	Female	Partial	Meningothelial
11	8	Rodrigues-Carbajal and Palacios ²¹		32	Female	Total	Meningothelial
12	9	Gökalp et al ²²	1981	30	Female	Total	Psammomatous
13	10	Tsuboi et al ²³	1983	30	Female	Total	Fibroblastic
14	11	Nagata et al ²⁴	1988	52	Female	Total	Fibroblastic
15	12	Matsumara et al ²⁵	1988	62	Male	Total	Fibroblastic
16	13	Nakano et al ²⁶	1989	58	Female	Total	Transitional
17	14	Jhonson et al ²⁷	1989	53	Male	Total	Osteoblastic
18	15	Diaz et al ²⁸	1990	5	Female	Total	Meningothelial
19	16	Ceylan et al ⁹	1992	48	Male	Total	Angiomatous
20	17	Delfini and al ²⁹	1992	22	Male	Total	Fibroblastic
21	18	Lima de Freitas et al ³⁰	1994	32	Female	Total	Meningothelial
22	19	Iseda et al ³¹	1997	67	Female	Total	Atypical
23	19	Iseda et al ³¹		47	Female	Total	Transitional
24	20	Cummings et al ³²	1999	72	Male	Total	Fibroblastic
25	21	Chaskis et al ⁶	2001	76	Male	Total	Fibroblastic
26	22	Akimoto et al ¹²	2001	72	Female	Total	Transitional
27	23	Ooigawa et al ¹¹	2004	51	Female	Total	Transitional
28	24	Carlotti et al ³³	2003	23	Female	Total	Clear cells
29	24	Carlotti et al ³³		28	Female	Total	Clear cells
30	25	Bathoe et al ³⁴	2006	Not available	Not available	Not available	Fibroblastic
31	25	Bathoe et al ³⁴		Not available	Not available	Not available	Meningothelial
32	26	Liu et al ⁴	2006	Not available	Not available	Not available	Mixed
33	27	Epari et al ¹⁴	2006	20	Female	Total	Chordoid
34	28	Bertalanffy et al ³⁵	2006	Not available	Not available	Total	Not available
35	29	da Costa et al ³⁶	2007	45	Male	Total	Not available
36	30	Shintaku et al ¹⁵	2007	61	Female	Total	Anaplastic
37	31	Wind and al ¹³	2010	23	Male	Total	Chordoid
38	32	Burgan et al ³⁷	2010	14	Male	Total	Clear cells
39	33	Alver et al ¹	2011	61	Male	Total	Fibroblastic
40	34	Pichierri et al ⁸	2011	30	Female	Not available	Meningothelial
41	34	Pichierri et al ⁸		22	Male	Not available	Fibroblastic

(Continued)

Table 1 (Continued)

Case	Publication	Author	Year	Age	Gender	Resection	Histology
42	34	Pichierri et al ⁸		22	Male	Not available	Fibroblastic
43	35	Zhang et al ³⁸	2012	23	Male	Total	Angiomatous
44	36	Qin et al ⁵	2012	25	Male	Not available	Fibrous
45	37	Takeuchi et al ³	2012	60	Male	Subtotal	Meningothelial
46	38	Zhang et al ¹⁰	2012	40	Female	Not available	Psammomatous
47	38	Zhang et al ¹⁰		43	Female	Not available	Clear cells
48	38	Zhang et al ¹⁰		65	Female	Not available	Fibroblastic
49	38	Zhang et al ¹⁰		60	Female	Not available	Fibroblastic
50	38	Zhang et al ¹⁰		20	Female	Not available	Transitional
51	38	Zhang et al ¹⁰		39	Male	Not available	Fibroblastic
52	38	Zhang et al ¹⁰		50	Male	Not available	Atypical
53	38	Zhang et al ¹⁰		9	Female	Not available	Fibroblastic
54	38	Zhang et al ¹⁰		69	Female	Not available	Fibroblastic
55	38	Zhang et al ¹⁰		57	Male	Not available	Atypical
56	39	Ødegaard et al ²	2013	Not available	Not available	Not available	Not available
57	40	Liu and Kasper ³⁹	2014	60	Male	Total	Atypical

meningiomas of the fourth ventricle, and 40 publications or references to them are in articles in English or Spanish.

Conclusion

Fourth-ventricle meningiomas have little incidence, possibly with a slight prevalence in young women, commonly presenting with progressive symptoms of IH and cerebellar syndrome. The surgical treatment is usually effective and has good results, considering, for that, adequate preoperative planning obtained through the radiological characteristics of the tumors. The low-grade lesions are the majority, although there is a broad spectrum of diagnosed subtypes.

Conflict of Interests

The authors have no conflict of interests to declare.

References

- Alver I, Abuzayed B, Kafadar AM, Muhammedrezai S, Sanus GZ, Akar Z. Primary fourth ventricular meningioma: case report and review of the literature. *Turk Neurosurg* 2011;21(02):249–253
- Ødegaard KM, Helseth E, Meling TR. Intraventricular meningiomas: a consecutive series of 22 patients and literature review. *Neurosurg Rev* 2013;36(01):57–64, discussion 64
- Takeuchi S, Sugawara T, Masaoka H, Takasato Y. Fourth ventricular meningioma: a case report and literature review. *Acta Neurol Belg* 2012;112(01):97–100
- Liu M, Wei Y, Liu Y, Zhu S, Li X. Intraventricular meningiomas: a report of 25 cases. *Neurosurg Rev* 2006;29(01):36–40
- Qin Y, Kanasaki Y, Takasugi M, et al. Primary fourth ventricular meningioma: a case report of an adult male. *Clin Imaging* 2012;36(04):379–382
- Chaskis C, Buisseret T, Michotte A, D'Haens J. Meningioma of the fourth ventricle presenting with intermittent behaviour disorders: a case report and review of the literature. *J Clin Neurosci* 2001;8 (Suppl 1):59–62
- Vogel FS, Stevenson LD. Meningothelial meningioma of the fourth ventricle. *J Neuropathol Exp Neurol* 1950;9(04):443–448
- Pichierri A, Ruggeri A, Morselli C, Delfini R. Fourth ventricle meningiomas: a rare entity. *Br J Neurosurg* 2011;25(04):454–458
- Ceylan S, Ilbay K, Kuzeyli K, Kalelioglu M, Aktürk F, Ozoran Y. Intraventricular meningioma of the fourth ventricle. *Clin Neurol Neurosurg* 1992;94(02):181–184
- Zhang BY, Yin B, Li YX, et al. Neuroradiological findings and clinical features of fourth-ventricular meningioma: a study of 10 cases. *Clin Radiol* 2012;67(05):455–460
- Ooigawa H, Miyazawa T, Otani N, Fukui S, Nawashiro H, Shima K. Usefulness of thallium-201 chloride single photon emission computed tomography for the preoperative diagnosis of fourth ventricle meningioma—case report. *Neurol Med Chir (Tokyo)* 2004;44(12):660–664
- Akimoto J, Sato Y, Tsutsumi M, Haraoka J. Fourth ventricular meningioma in an adult—case report. *Neurol Med Chir (Tokyo)* 2001;41(08):402–405
- Wind JJ, Jones RV, Roberti F. Fourth ventricular chordoid meningioma. *J Clin Neurosci* 2010;17(10):1301–1303
- Epari S, Sharma MÇ, Sarkar C, Garg A, Gupta A, Mehta VS. Chordoid meningioma, an uncommon variant of meningioma: a clinicopathologic study of 12 cases. *J Neurooncol* 2006;78(03):263–269
- Shintaku M, Hashimoto K, Okamoto S. Intraventricular meningioma with anaplastic transformation and metastasis via the cerebrospinal fluid. *Neuropathology* 2007;27(05):448–452
- Haas A, Ritter SA. A post-thyroidectomy fatality due to a silent pedunculated meningioma of the fourth ventricle of the brain. *Am J Surg* 1954;88(02):346–350
- Bustamante Zuleta E, Londono R. [Meningiomas of the fourth ventricle]. *Acta Neurochir (Wien)* 1955;4(03):228–232
- Schaerer JP, Woolsey RD. Intraventricular meningiomas of the fourth ventricle. *J Neurosurg* 1960;17:337–341
- Chaffee B, Donaghy RM. MENINGIOMA OF THE FOURTH VENTRICLE. *J Neurosurg* 1963;20:520–522
- Hoffman JC Jr, Bufkin WJ, Richardson HD. Primary intraventricular meningiomas of the fourth ventricle. *Am J Roentgenol Radium Ther Nucl Med* 1972;115(01):100–104

- 21 Rodríguez-Carbajal J, Palacios E. Intraventricular meningiomas of the fourth ventricle. *Am J Roentgenol Radium Ther Nucl Med* 1974;120(01):27-31
- 22 Gökalp HZ, Ozkal E, Erdogan A, Selcuki M. A giant meningioma of the fourth ventricle associated with Sturge-Weber disease. *Acta Neurochir (Wien)* 1981;57(1-2):115-120
- 23 Tsuboi K, Nose T, Maki Y. Meningioma of the fourth ventricle: a case report. *Neurosurgery* 1983;13(02):163-166
- 24 Nagata K, Basugi N, Sasaki T, Hashimoto K, Manaka S, Takakura K. Intraventricular meningioma of the fourth ventricle—case report. *Neurol Med Chir (Tokyo)* 1988;28(01):86-90
- 25 Matsumura M, Takahashi S, Kurachi H, Tamura M. Primary intraventricular meningioma of the fourth ventricle—case report. *Neurol Med Chir (Tokyo)* 1988;28(10):996-1000
- 26 Nakano S, Uehara H, Wakisaka S, Kinoshita K. Meningioma of the fourth ventricle—case report. *Neurol Med Chir (Tokyo)* 1989;29(01):52-54
- 27 Johnson MD, Tulipan N, Whetsell WO Jr. Osteoblastic meningioma of the fourth ventricle. *Neurosurgery* 1989;24(04):587-590
- 28 Díaz P, Maillo A, Morales F, Gómez-Moreta JA, Hernández J. Multiple meningiomas of the fourth ventricle in infancy: case report. *Neurosurgery* 1990;26(06):1057-1060
- 29 Delfini R, Capone R, Ciappetta P, Domenicucci M. Meningioma of the fourth ventricle: a case report. *Neurosurg Rev* 1992;15(02):147-149
- 30 Lima de Freitas M, Dourado M, Escartín A, Roig C. [Meningioma of the fourth ventricle. Migraine without aura as the first sign]. *Neurologia* 1994;9(03):121-122
- 31 Iseda T, Goya T, Nakano S, Wakisaka S. Magnetic resonance imaging and angiographic appearance of meningioma of the fourth ventricle—two case reports. *Neurol Med Chir (Tokyo)* 1997;37(01):36-40
- 32 Cummings TJ, Bentley RÇ, Gray L, Check WE, Lanier TE, McLendon RE. Meningioma of the fourth ventricle. *Clin Neuropathol* 1999;18(05):265-269
- 33 Carlotti CG Jr, Neder L, Colli BO, et al. Clear cell meningioma of the fourth ventricle. *Am J Surg Pathol* 2003;27(01):131-135
- 34 Bhatoe HS, Singh P, Dutta V. Intraventricular meningiomas: a clinicopathological study and review. *Neurosurg Focus* 2006;20(03):E9
- 35 Bertalanffy A, Roessler K, Koperek O, et al. Intraventricular meningiomas: a report of 16 cases. *Neurosurg Rev* 2006;29(01):30-35
- 36 da Costa LB, Riva-Cambrin J, Tandon A, Tymianski M. Pituitary adenoma associated with intraventricular meningioma: case report. *Skull Base* 2007;17(05):347-351
- 37 Burgan OT, Bahl A, Critcher V, Zaki HS, McMullan PJ, Sinha S. Clear cell meningioma of the fourth ventricle in a child: a case report and literature review. *Pediatr Neurosurg* 2010;46(06):462-465
- 38 Zhang J, Shrestha R, Peizhi Z, Jiang S. Meningioma of the fourth ventricle with exceptional growth pattern. *Clin Neurol Neurosurg* 2013;115(08):1567-1569
- 39 Liu R, Kasper EM. Bilateral telovelar approach: A safe route revisited for resections of various large fourth ventricle tumors. *Surg Neurol Int* 2014;5:16