

Salvage of Necrotic-Appearing Limb after In Utero Endoscopic Lysis of Constriction Bands

M. Abdel-Sattar, BS¹ A. Chon, MD¹ B. Chen, MD² W. Burkhalter, MD³ R.H. Chmait, MD¹

¹Department of Obstetrics and Gynecology, Keck School of Medicine, University of Southern California, Los Angeles, California

²Fetal Diagnostic Institute of the Pacific, Honolulu, Hawaii

³Kapi'olani Orthopaedics, Honolulu, Hawaii

Address for correspondence Ramen H. Chmait, MD, 39 Congress Street, Suite 302, Pasadena, CA 91105 (e-mail: chmait@usc.edu).

Am J Perinatol Rep 2017;7:e74–e78.

Abstract

We report a case of amniotic band syndrome complicated by constriction bands and marked distal swelling of both lower extremities. Color Doppler interrogation of the right lower extremity revealed complete lack of blood flow below the level of the constriction. Upon fetoscopic survey, the right lower extremity beyond the constriction band appeared dusky red and discolored with desquamation, consistent with a necrotic appearance. The constriction bands were cut in utero using endoshears, thereby allowing restoration of blood flow on postoperative day 1. The patient was counseled extensively regarding the possibility of limb dysfunction or amputation. However, the baby was born with functional lower extremities, and at 21 months of age, the child was cruising and jumping on his own. This case demonstrates that there is unique plasticity in fetal limb recovery after a severe ischemic injury that is not otherwise seen in postnatal life. Reperfusion of the necrotic-appearing limb resulted in restoration of appearance and function without apparent deleterious effects on the fetus. We believe the favorable outcome in this case was likely due to timeliness of the in utero lysis of amniotic bands and the plasticity of fetal healing.

Keywords

- ▶ amniotic band syndrome
- ▶ constriction band
- ▶ fetoscopy
- ▶ reperfusion

Case Report

A 28-year-old with an intrauterine pregnancy at 21^{1/7} weeks' gestation was referred for evaluation of amniotic band syndrome (ABS) complicated by constriction bands involving both lower extremities. Bilateral pedal edema had been first noted by the referring provider at 19^{3/7} weeks' gestation. Ultrasound at 21^{1/7} weeks' gestation confirmed ABS with circumferential constriction of both lower extremities and marked distal swelling. The right and left ankle circumferences measured 155 and 211% that of the leg circumferences above the constriction, respectively. Movements of both lower extremities were restricted. Color flow and pulse wave Doppler interrogation of the right lower extremity revealed no arterial or venous flow below the level of the constriction (–Fig. 1a); the left lower extremity distal to the

constriction had arterial and venous flow (–Fig. 1b). The umbilical cord was adherent to the lower extremities. Umbilical vein aneurysm was noted in the region of the cord that was tethered to the lower extremities through the amniotic bands; the umbilical vein measured 1.2 cm in diameter in that region compared with 0.4 cm in other areas. The distal ends of the right fourth and fifth fingers appeared attenuated. The left upper extremity had restricted movement. No other gross abnormalities were seen.

After review of the aforementioned ultrasound findings and discussion of the management options, the patient elected to undergo operative fetoscopy and in utero endoscopic release of the constrictive amniotic bands. The surgery was performed at 22^{0/7} weeks' gestation through a single port. A 3.3-mm diagnostic endoscope (Richard Wolf Inc., Vernon Hills, IL) was used to perform a fetoscopic survey

received
January 30, 2017
accepted after revision
March 10, 2017

DOI <http://dx.doi.org/10.1055/s-0037-1602125>.
ISSN 2157-6998.

Copyright © 2017 by Thieme Medical Publishers, Inc., 333 Seventh Avenue, New York, NY 10001, USA.
Tel: +1(212) 584-4662.

License terms



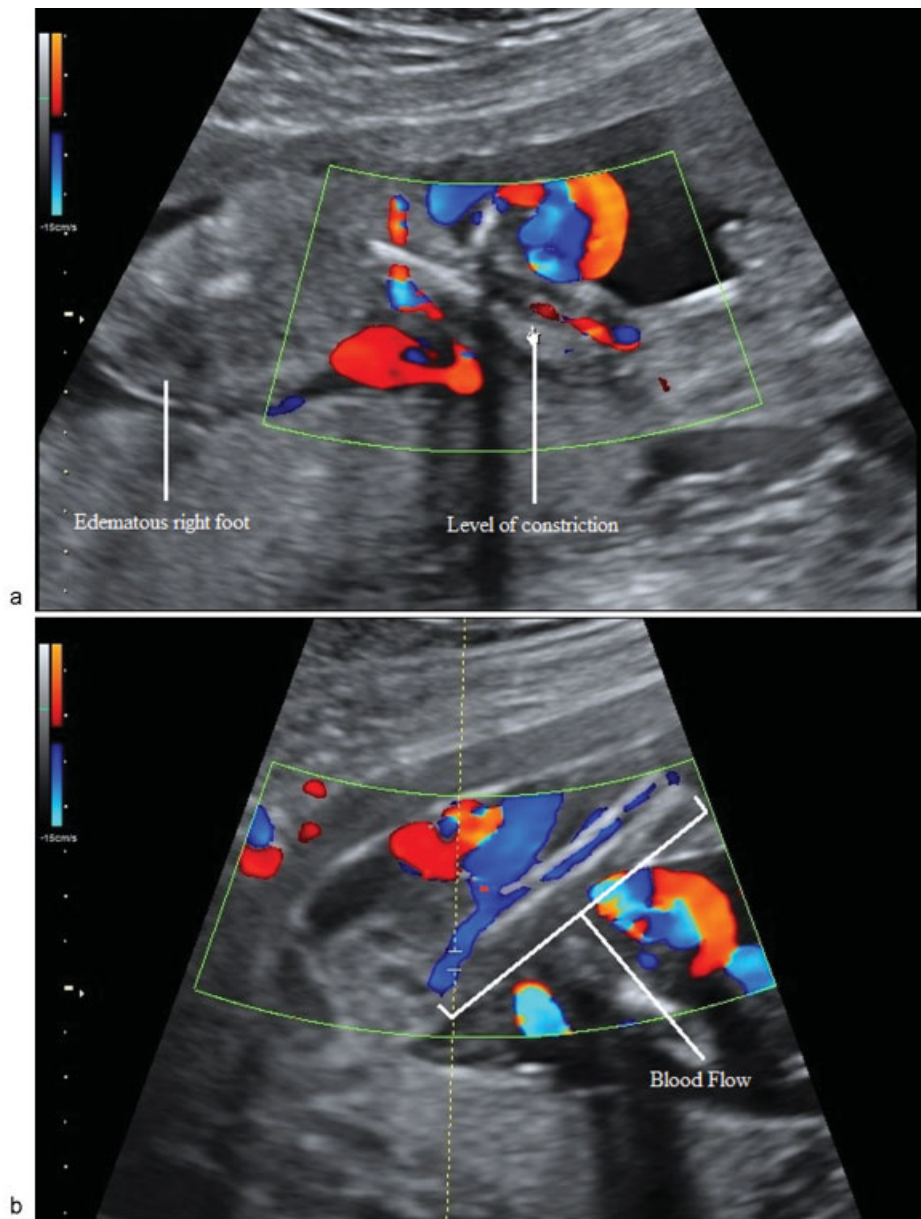


Fig. 1 Preoperative ultrasound images of the right and left lower extremities. (a) Right leg with no evidence of color Doppler waveforms distal to the constriction bands. (b) Color Doppler waveforms present along the entire length of the left lower extremity (bracket).

of the right lower extremity, which revealed a constriction band below the knee (► **Fig. 2a**). The right lower extremity beyond this constriction band appeared dusky red and discolored with desquamation, consistent with a necrotic appearance (► **Fig. 2b**). The left leg also had a constriction band located between the knee and the ankle with distal edema but otherwise normal appearance. Using endoshears delivered through the 5-Fr operating channel of the 3.8-mm operating endoscope (Richard Wolf Inc.), the constriction band of the left extremity was cut and released. This maneuver resulted in release of the umbilical cord. The constriction band on the right lower extremity was cut in multiple locations but remained adherent within the crease, thereby forming a discontinuous band around that leg. The band

could not be fully dissected off because it was adherent to the underlying fetal tissue. Because of the intricate nature of the bands involving the fingers, it was deemed unsafe to release them.

Postoperative ultrasound findings confirmed release of both constriction bands with restoration of blood flow to the right lower extremity (► **Fig. 3**), and release of the umbilical cord. The right and left fetal dorsalis pedis artery pulsatility indexes were 1.47 and 1.81, respectively. At 22 weeks' gestational age, the 2.5 to 97.5 percentile for pulsatility index of the dorsalis pedis artery was 1.72 to 2.71.¹ The umbilical vein aneurysm had decreased in size; the umbilical vein measured 0.78 cm in diameter within the aneurysm compared with 0.36 cm in other areas. The

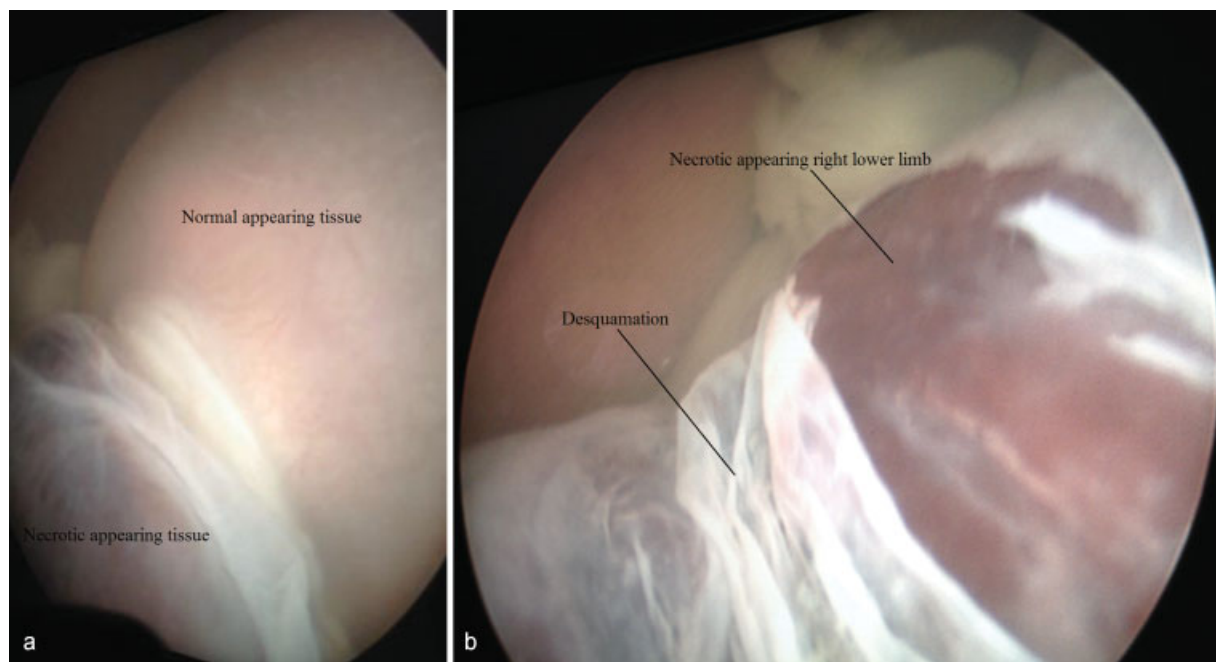


Fig. 2 Fetoscopic view at 22 weeks' gestational age. (a) Constriction band on the lower right extremity. (b) Right lower extremity appeared dusky red with desquamation distal to the constriction band.

patient was counseled extensively regarding the unknown prognosis of reperfusion of the necrotic-appearing right lower extremity as well as the possibility of secondary injury to distal organs. The possibility of profound limb dysfunction or amputation was emphasized. The patient elected to continue the pregnancy. She delivered at 36^{6/7} weeks through cesarean section for breech presentation after preterm premature rupture of membranes.

Neonatal examination revealed deep creases at the distal third of both legs. The feet were perfused but demonstrated edema. Both lower extremities had active flexion and extension at the knees and hips. A neurovascular examination revealed an intact vascular system but limited plantar flexion function (manual muscle testing: 3/5 on the right, 4/5 on the left). The right tibia and fibula had posterolateral angular deformity, marked recurvatum, anterior new bone formation, and no visible lucency or fracture. The right foot exhibited swelling and ecchymosis below the constriction, as well as partial amputation of the big toe.

Within the first 30 days of life, the baby underwent corrective surgery with right small finger partial constriction band excision and Z-plasty due to concern of ischemia. At 3 months of life, the baby underwent bilateral anterior lower extremity Z-plasty reconstruction to address the distal edema. At 10 months of age, the baby suffered an episode of hand-foot-mouth disease complicated by right foot cellulitis requiring 2-day hospital admission and intravenous antibiotics. Likely entry site for infection was a healing lesion on the third right toe in the setting of impaired lymphatic drainage. At 11 months of life, the baby underwent the planned second-stage bilateral posterior lower extremity band excision and Z-plasty reconstruction. At 1 year of life,

the baby was cruising and standing on his own. At 15 months of age, an abscess at the suture line of the posterior left leg was incised and drained. At 17 months, the baby underwent a left fourth web-space syndactyly reconstruction on the left hand with full-thickness skin graft obtained from left groin, left index finger, and left long finger. At 21 months of age, the right leg continues to have improving recurvatum deformity, mild persistent foot swelling, and some residual peroneal weakness (–Fig. 4). The foot is plantargrade with anticipated good long-term function and no further noncosmetic surgeries expected.

Discussion

We report a case of ABS in which a constriction band involving an extremity with a necrotic appearance on fetoscopic survey was released in utero, thereby allowing restoration of blood flow and salvage of the distal limb. Prior case reports have discussed fetal limb salvage after in utero release of constriction amniotic bands on limbs with impaired blood flow.²⁻⁷ However, to our knowledge, no previous case showed complete lack of blood flow in a necrotic-appearing limb with restoration of flow and function after in utero surgical lysis of the constriction band.

In this case, cutting the constriction band in three places resulted in a noncontiguous band that loosened but remained adherent to the right leg. This was enough to restore blood flow on postoperative day 1 and thus, we believe, increase the likelihood of functional improvement of the right lower extremity. In addition, fetal demise was likely averted due to the release of the umbilical cord, which improved the umbilical vein aneurysm.

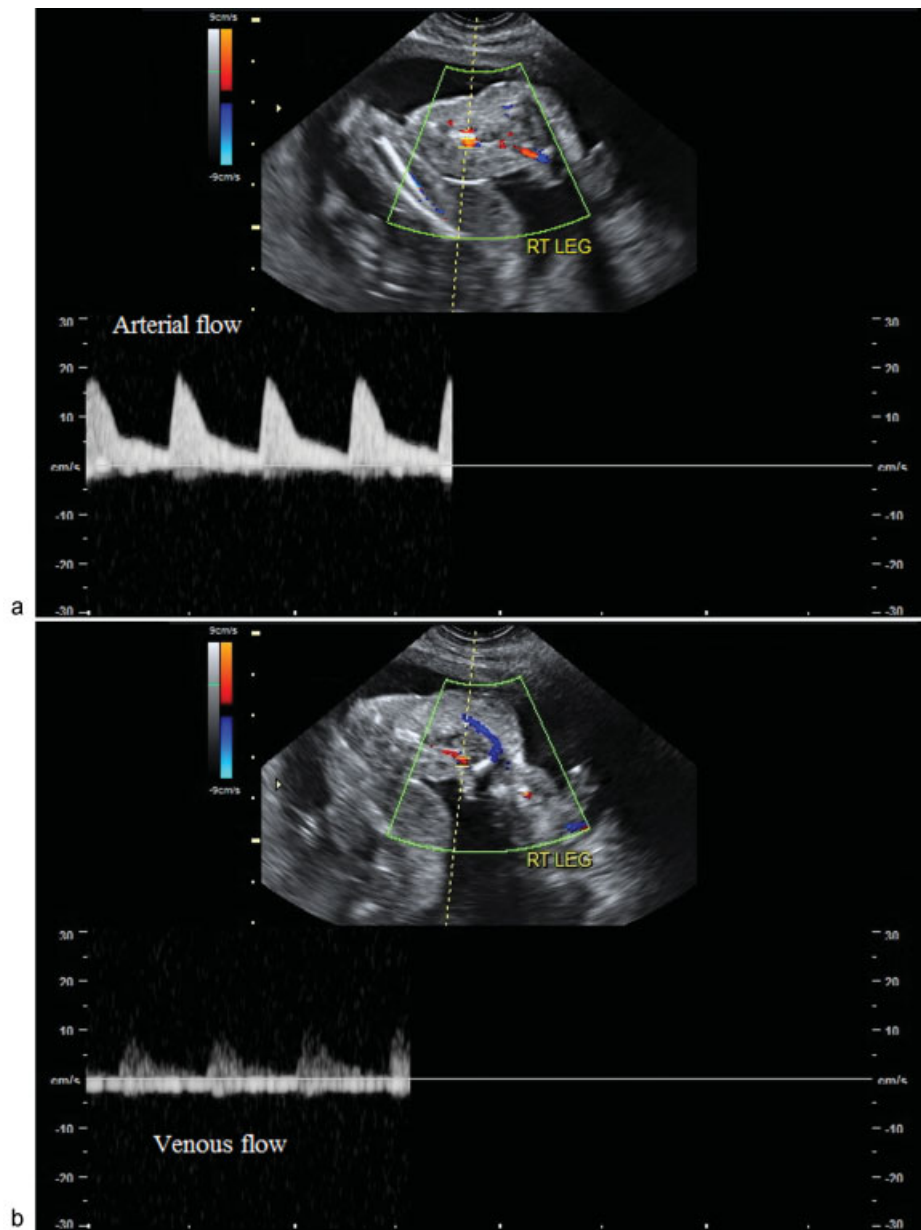


Fig. 3 Postoperative ultrasound images of the right lower extremity demonstrating both arterial (a) and venous (b) color Doppler waveforms distal to the constriction site.

We believe that our case demonstrates that there is increased plasticity in fetal limb recovery after a severe ischemic injury. As it is understood in the adult population, the pathophysiology of acute limb ischemia involves distal tissue ischemia and cell dysfunction and death.⁸ In severely ischemic limbs, amputation is generally preferred to prevent systemic infection, coagulopathy, and/or renal damage. In prenatally acquired limb ischemia, surgical management is often required after birth for reconstruction or amputation of the involved extremity. However, in contrast to the management of adult limb ischemic injury, some argue for delayed neonatal amputation since the eventual line of demarcation may be some way distal to the original line of ischemia.^{9,10}

In this case, the fetus had absent arterial and venous Doppler signals with a necrotic appearance of the lower right limb at 22 weeks' gestation. This could be considered class III irreversible limb ischemia, which is consistent with major tissue loss, permanent nerve damage, and profoundly anesthetic and paralyzed limb.¹¹ Such patients typically require amputation because major muscle necrosis and nerve deficits produce a nonfunctional limb despite revascularization attempts.^{11,12} Revascularization attempts are not only unlikely to salvage a functional limb, but may also actually lead to increased morbidity due to systemic inflammation with multiorgan dysfunction.^{11,13} However, in our case, reperfusion of the necrotic-appearing limb resulted in restoration of appearance and function without apparent

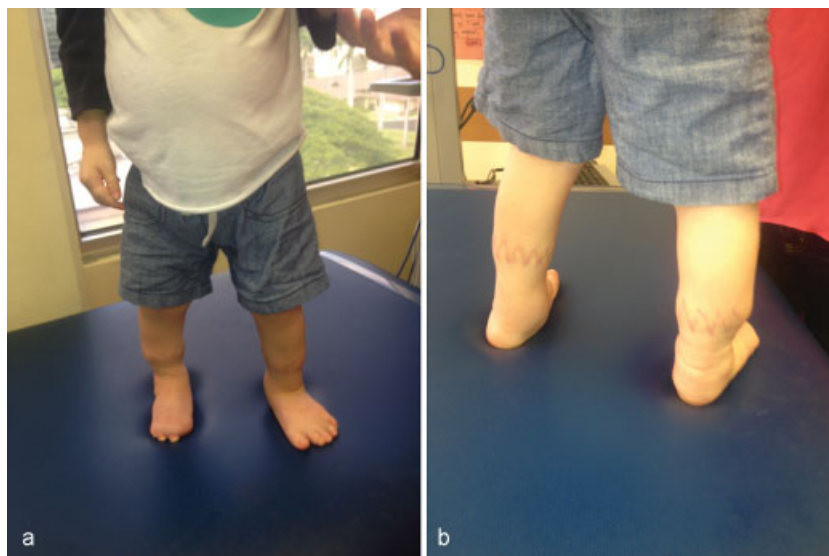

Fig. 4 Lower extremities at 21 months of life. (a) Anterior view. (b) Posterior view.

deleterious effects on the fetus. We believe that the favorable outcome in this case was likely due to timeliness of the in utero lysis of amniotic bands and the plasticity of fetal healing.

References

- 1 Zhao Y, Zhang M, Zhou Q, Tang K, Wang L, Gong Z. Fetal dorsalis pedis artery velocimetry in the second and third trimesters. *J Ultrasound Med* 2013;32(07):1227–1232
- 2 Quintero RA, Morales WJ, Phillips J, Kalter CS, Angel JL. In utero lysis of amniotic bands. *Ultrasound Obstet Gynecol* 1997;10(05):316–320
- 3 Keswani SG, Johnson MP, Adzick NS, et al. In utero limb salvage: fetoscopic release of amniotic bands for threatened limb amputation. *J Pediatr Surg* 2003;38(06):848–851
- 4 Richter J, Wergeland H, DeKoninck P, De Catte L, Deprest JA. Fetoscopic release of an amniotic band with risk of amputation: case report and review of the literature. *Fetal Diagn Ther* 2012;31(02):134–137
- 5 Ronderos-Dumit D, Briceño F, Navarro H, Sanchez N. Endoscopic release of limb constriction rings in utero. *Fetal Diagn Ther* 2006;21(03):255–258
- 6 Soldado F, Aguirre M, Peiró JL, et al. Fetoscopic release of extremity amniotic bands with risk of amputation. *J Pediatr Orthop* 2009;29(03):290–293
- 7 Peiró JL, Carreras E, Soldado F, et al. Fetoscopic release of umbilical cord amniotic band in a human fetus. *Ultrasound Obstet Gynecol* 2009;33(02):232–234
- 8 Hirsch AT, Haskal ZJ, Hertzler NR, et al; American Association for Vascular Surgery; Society for Vascular Surgery; Society for Cardiovascular Angiography and Interventions; Society for Vascular Medicine and Biology; Society of Interventional Radiology; ACC/AHA Task Force on Practice Guidelines Writing Committee to Develop Guidelines for the Management of Patients With Peripheral Arterial Disease; American Association of Cardiovascular and Pulmonary Rehabilitation; National Heart, Lung, and Blood Institute; Society for Vascular Nursing; TransAtlantic Inter-Society Consensus; Vascular Disease Foundation. ACC/AHA 2005 Practice Guidelines for the management of patients with peripheral arterial disease (lower extremity, renal, mesenteric, and abdominal aortic): a collaborative report from the American Association for Vascular Surgery/Society for Vascular Surgery, Society for Cardiovascular Angiography and Interventions, Society for Vascular Medicine and Biology, Society of Interventional Radiology, and the ACC/AHA Task Force on Practice Guidelines (Writing Committee to Develop Guidelines for the Management of Patients With Peripheral Arterial Disease); endorsed by the American Association of Cardiovascular and Pulmonary Rehabilitation; National Heart, Lung, and Blood Institute; Society for Vascular Nursing; TransAtlantic Inter-Society Consensus; and Vascular Disease Foundation. *Circulation* 2006;113(11):e463–e654
- 9 Armstrong AP, Page RE. Intrauterine vascular deficiency of the upper limb. *J Hand Surg [Br]* 1997;22(05):607–611
- 10 Arshad A, McCarthy MJ. Management of limb ischaemia in the neonate and infant. *Eur J Vasc Endovasc Surg* 2009;38(01):61–65
- 11 Rutherford RB. Clinical staging of acute limb ischemia as the basis for choice of revascularization method: when and how to intervene. *Semin Vasc Surg* 2009;22(01):5–9
- 12 Henke PK. Contemporary management of acute limb ischemia: factors associated with amputation and in-hospital mortality. *Semin Vasc Surg* 2009;22(01):34–40
- 13 Eliason JL, Wakefield TW. Metabolic consequences of acute limb ischemia and their clinical implications. *Semin Vasc Surg* 2009;22(01):29–33