

Symptomatic Multiple Level Lateral Meningoceles with Intraspinal Meningocele: A Case Study and Its Surgical Management

Vernon Velho¹ Sachin Guthe¹ Pravin Survashe¹ Poonam Darade²

¹Department of Neurosurgery, Grant Government Medical College and Sir JJ Group of Hospitals, Mumbai, Maharashtra, India

²Department of Radiology, Grant Government Medical College and Sir JJ Group of Hospitals, Mumbai, Maharashtra, India

Address for correspondence Sachin Guthe, MCh, Department of Neurosurgery, Grant Government Medical College and Sir JJ Group of Hospitals, 4th floor, Main Building, Byculla, Mumbai, Maharashtra 400 008, India (e-mail: spguthe@gmail.com).

Indian J Neurosurg 2017;6:15–19.

Abstract

Lateral meningocele is rare disorder of unknown etiology that represents herniation of leptomeninges through enlarged neural foramina. Most patients are asymptomatic and do not need treatment. A symptomatic case with neurologic deficit requires well-planned surgical approach. We report a case of 9-year-old boy who presented with mid backache and progressive asymmetric paraparesis with urinary incontinence. The patient did not appear to have any neurologic disorder. Magnetic resonance imaging (MRI) of spine revealed bilateral multiple thoracic and lumbar paraspinal cerebrospinal fluid (CSF) intensity cystic lesions projecting from the neural foramen and extending laterally suggesting multiple bilateral meningoceles. He was surgically treated, meningocele repair was done, and thecopertoneal shunt was inserted. Postoperatively he improved symptomatically. Bilateral multiple lateral meningoceles are very rare entity and those who are surgically treated are few. We emphasize our innovative surgical approach to this case.

Keywords

- ▶ lateral meningocele
- ▶ multiple meningoceles
- ▶ intraspinal meningocele

Introduction

Lateral meningocele syndrome is a rare disorder characterized by the widespread presence of protrusions of the arachnoid and the dura matter extending laterally through inter- or intravertebral foramina into the paraspinal, retroperitoneal, or intrathoracic region. It is a hereditary disorder that primarily affects the connective tissues. This disorder manifests itself with formations of cysts at different levels of the central nervous system along with meningeal diverticula protruding through the intervertebral spaces and filled by cerebrospinal fluid (CSF). Other clinical findings associated with the lateral meningocele syndrome include specific facial anomalies, cryptorchidism, hypotonia and muscle atrophy, scoliosis, restricted joint movements, pectus deformities, and abdominal hernias. Lateral meningoceles may be unilateral

or bilateral (as in the present case) and may exist as solitary or multiple (as in the present case). The pathogenesis of lateral meningoceles is complex because symptom onset depends on the location of the cyst and the meningeal protrusions. So far, lateral meningoceles have been reported in fewer than 20 patients worldwide¹ and very few patients were managed surgically. Surgical repair of symptomatic lateral meningocele is difficult and needs to be decided on the basis clinical and radiologic correlation.

Clinical Report

This 9-year-old boy was brought by his parents with complaints of mid backache, progressive weakness of both lower limbs, and difficulty in passing urine over the period of 6 months. General examination revealed flattening of the

received
September 7, 2016
accepted
October 18, 2016
published online
January 29, 2017

DOI <http://dx.doi.org/10.1055/s-0037-1598093>.
ISSN 2277-954X.

© 2017 Neurological Surgeons' Society of India

License terms



angles of the mandible and cleft palate. There were no features of Marfan syndrome or neurofibromatosis. His vitals were stable. There was no breathing difficulty. Higher mental functions appeared normal. Neurologic examination revealed asymmetric paraparesis (left lower limb power grade 2/5 and right lower limb grade 3/5) with neurogenic bladder. Power in both upper limb was normal (grade 5/5).

Magnetic resonance imaging (MRI) of the dorsolumbar spine with T2-weighted (T2W) sagittal screening of the entire spine and brain was obtained. There were multiple bilateral dural outpouching seen in the thoracolumbar region at multiple levels, along bilateral paraspinous spaces that were extending from the T4–T5 to T12–L1 levels. These were seen larger in size on left side compared with right with largest measuring 4.8 × 5.4 × 4.9 cm at T11–T12 level.

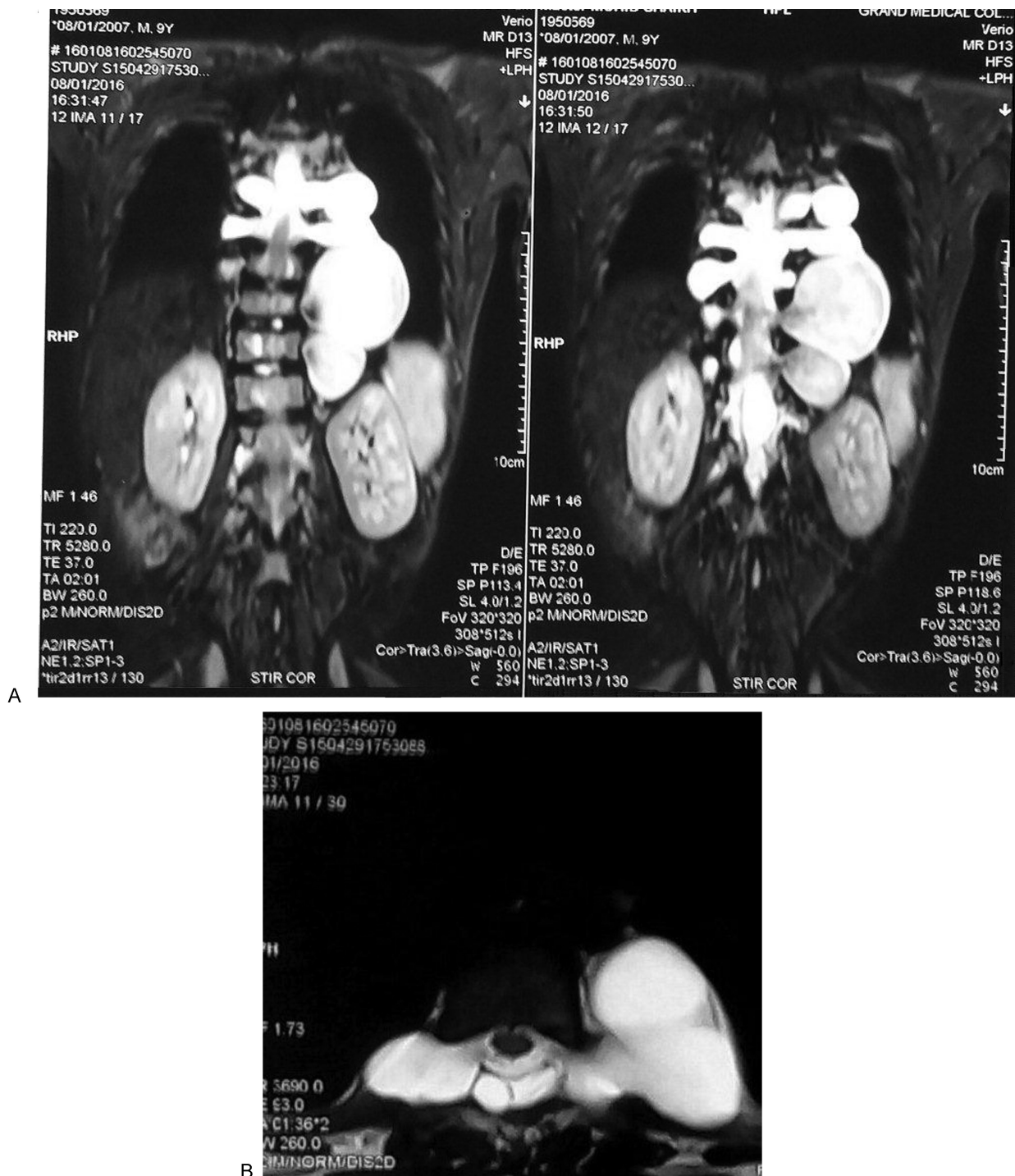

Fig. 1 (A–C) Preoperative MRI of dorsolumbar spine with T2W sequences showing multilevel bilateral meningoceles. Largest one being on left side.

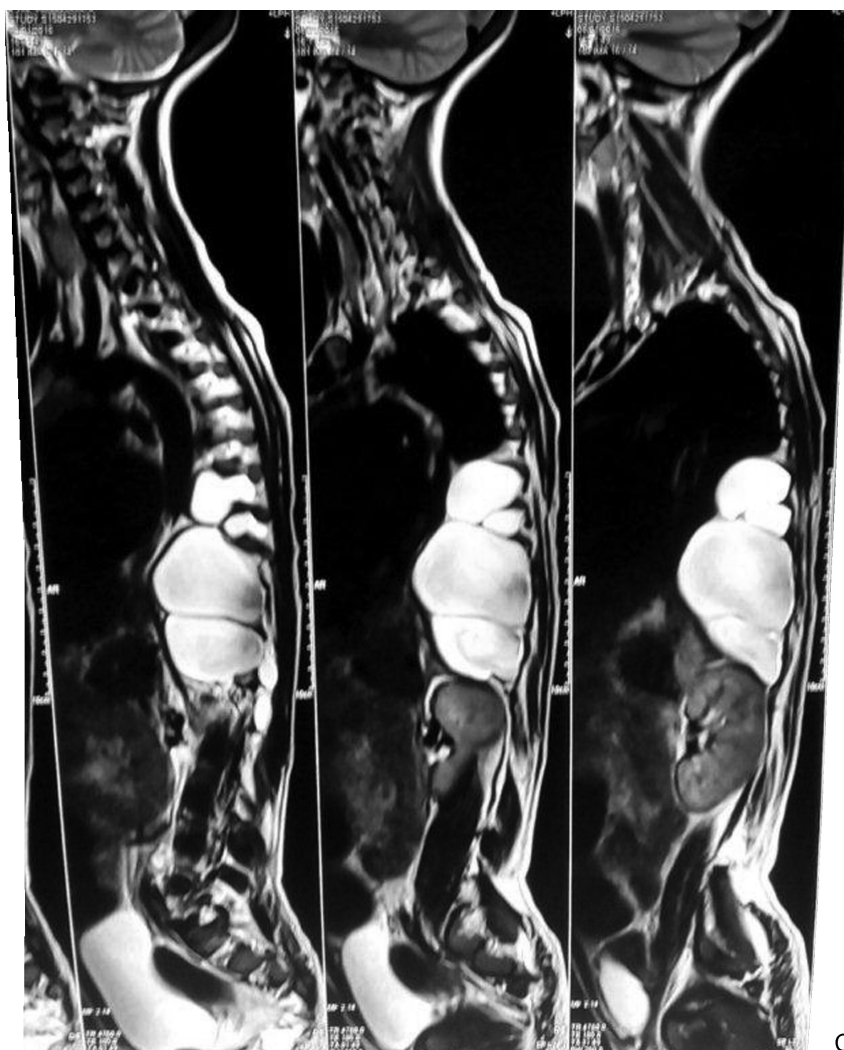


Fig. 1 (Continued)

Few of them were seen extending into the paraspinal muscles posteriorly, especially at T9–T10 and T11–T12 level. There was resultant bilateral neural foramen widening and posterior scalloping of vertebral bodies. In the thoracic region, these cysts were seen compressing bilateral posterolateral parietal pleura and adjacent lung parenchyma with resultant passive lung collapse. All these findings were suggestive of multiple bilateral lateral meningoceles (► **Fig. 1**).

There was another similar cystic lesion seen in the extramedullary intradural space from T8 to T12 level. It was multiseptate with possible communication with dural sac at places. This was significantly compressing and displacing spinal cord anteriorly. These findings were suggestive of intraspinal meningocele with canal stenosis (► **Fig. 2**). Screening MRI of the brain was unremarkable.

After thorough clinical examination and correlation with MRI findings, it was noted that patient had neurologic deficit due to canal compression at T8 to T12 level. After the patient underwent all routine preoperative investigations (complete blood count, renal function tests, etc.), he was planned for surgery.

Intraoperative Findings and Surgical Management

After administration of general anesthesia he was put in prone position. Midline back incision was taken exposing T6 to L1 spinous processes. Then T6 to L1 laminotomy was done to expose the dura. The dura was thickened and had multiple layers suggesting complex intraspinal meningocele. CSF was noted between those dural layers. On either side of the spinal cord, at some places CSF was seen entering into multiple dural outpouching through neural foramen forming lateral meningocele. We split opened all layers of the dura longitudinally until we could see the spinal cord; thus canal was decompressed. Now we had multilayered cut edges of the dura on both sides. On either side all these dural layers were sutured continuously into a single layer. This ensured closure of lateral outflow of CSF into dural layers and outpouchings, thus reducing size of lateral meningoceles. Before final closure of two dural edges, a thecoperitoneal shunt was inserted.

Postoperative recovery was good without any fresh neurologic deficit. Power in the lower limb started

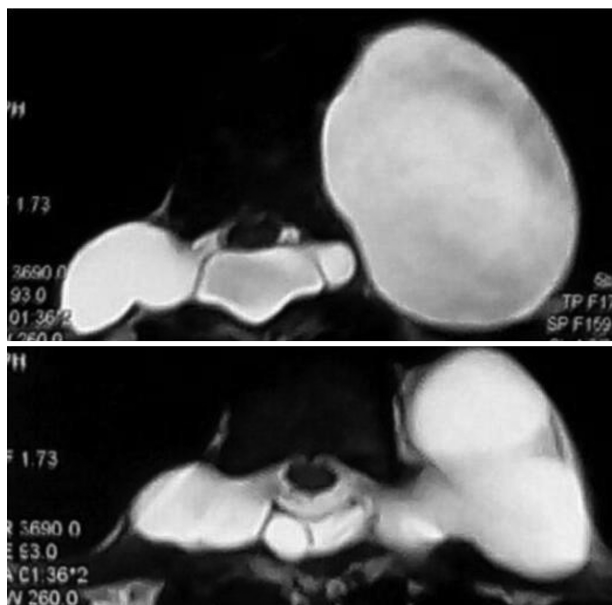


Fig. 2 Preoperative MRI of dorsal spine with T2W axial sequence showing intraspinal meningocele compressing dorsal cord.

improving gradually; the patient started walking with support. He had symptomatic relief from the back pain. After 1 month, a follow-up MRI of the spine revealed significant reduction in the size of lateral meningoceles (→**Fig. 3**) and satisfactory canal decompression.

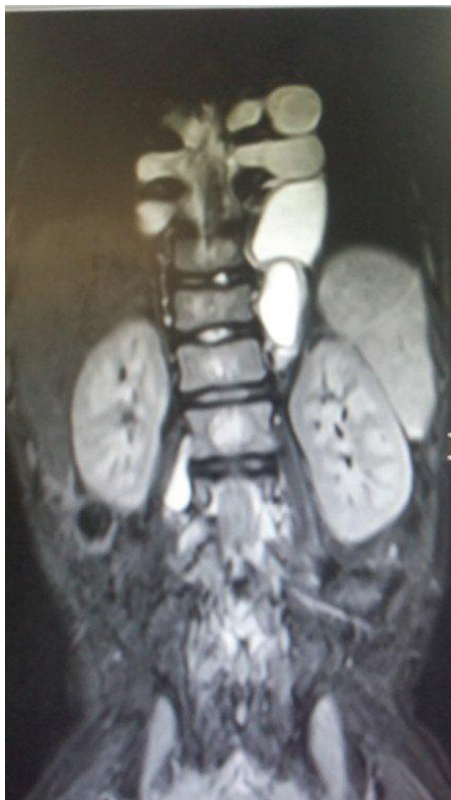

Fig. 3 Postoperative MRI of dorsolumbar spine with T2 coronal sequences done showing significant reduction in size of left-sided lateral meningocele.

Discussion

Lateral or anterior spinal meningoceles are relatively rare congenital anomalies where protrusion of the dura mater and arachnoid extends laterally through an enlarged intervertebral foramen into the paraspinous, intrathoracic, or retroperitoneal region. Lateral meningoceles may be unilateral or bilateral or may be solitary or multiple. Typically, lateral and anterior meningoceles are occult lesions that are not visible externally. An anterior defect can form in the vertebral column as a result of faulty embryogenesis. Such faulty development can also result in coexisting abnormalities in the skin, subcutaneous tissues, spine, and internal organs. Another important factor that can influence the development of anterior and lateral spinal meningoceles is the balance between both the hydrostatic pressure and the pulsations of the CSF, and the resistance of the arachnoid and dura mater to deformation by such pressure, especially at the intervertebral foramina. If there is a developmental bony defect, the dura and arachnoid may bulge out through it.²

Lateral meningocele syndrome or Lehman syndrome is characterized by multiple lateral meningoceles in the absence of neurofibromatosis or Marfan syndrome. It is suggested that lateral meningocele syndrome is an autosomal dominant disorder affecting primarily the connective tissue with many associated skeletal findings kyphoscoliotic deformities, joint hypermobility, pectus deformities, craniofacial abnormalities, and vertebral defects such as hemi vertebrae, scoliosis, absence of neural arches on the affected side, widening of the spinal canal, and intervertebral foramina.³

The clinical manifestations of meningocele closely relate with its size and its relationship with surrounding structures. The patient may be asymptomatic or can present with back pain or paraparesis.⁴ In contrast, in the setting of a small meningocele, no symptoms can be recorded, and the lesion may be incidentally diagnosed on a routine chest radiograph. Lateral meningoceles occur more commonly in females than males. Clinical signs of lateral meningoceles syndrome usually manifest in fourth or fifth decade of life, although younger patients have also been reported.⁵

Our patient presented with mid backache and paraparesis that was due to compression by the meningocele on dorsal spinal cord and exiting nerve roots. Because the child showed progressive neurological deterioration, we opted surgical management. Dorsal canal and lateral meningocele were decompressed. Thecoperitoneal shunt helped our patient in two ways: first, shunting of CSF released the pressure generated in the intraspinal compartment, thus reducing the size of lateral meningoceles, and second, it helped avoiding postoperative CSF leak ensuring good healing of closed dural margins. Because of adequate decompression of canal and intraspinal meningocele, our patient had remarkable symptomatic improvement.

Castori et al⁶ have reported the case of a 55-year-old woman with the lateral meningocele syndrome who underwent surgery to correct two large lateral meningoceles at the lumbosacral level, which were supposedly the cause of her

pain. However, surgery did not alleviate her symptoms and only exacerbated the symptoms by causing irreversible nerve damage with bladder and anorectal dysfunction linked to weakness in lower limbs, hence making the patient wheelchair bound. This emphasizes the significance of early diagnosis and surgical treatment of symptomatic patients at earlier age.

MRI of the spine with coronal T2W sequence is one of the best sequences to diagnose lateral meningocele. CT scan with 3D reconstruction further helps delineate and understand bony anomalies if present.

Conclusion

Surgical repair is the best option for symptomatic lateral meningocele. In cases of multiple lateral meningoceles, identifying the location of symptomatic lateral meningocele is most important to get good clinical outcome. The largest or the most symptomatic meningocele should be targeted and surgically repaired. Multiple (unilateral or bilateral), small, asymptomatic lateral meningoceles do not need any treatment. They need to be followed up regularly. Thecoperitoneal shunt is good adjuvant to surgical repair.

Source of Funding

None.

Conflict of Interest

None.

Consent

Written informed consent was obtained from the patient's parents for publication of this case study and accompanying images.

References

- 1 Mushtaq G, Hussain I, Khan JA, Kamal MA. Lateral meningocele with asymmetric canal stenosis: a case study. *Saudi J Biol Sci* 2015;22(01):102–105
- 2 Kumar BE, Hegde KV, Kumari GL, Agrawal A. Bilateral multiple level lateral meningocele. *J Clin Imaging Sci* 2013;3(01):1
- 3 Gripp KW, Scott CI Jr, Hughes HE, et al. Lateral meningocele syndrome: three new patients and review of the literature. *Am J Med Genet* 1997;70(03):229–239
- 4 Mizuno J, Nakagawa H, Yamada T, Watabe T. Intrathoracic giant meningocele developing hydrothorax: a case report. *J Spinal Disord Tech* 2002;15(06):529–532
- 5 Seddighi A, Seddighi AS. Lateral sacral meningocele presenting as a gluteal mass: a case report. *J Med Case Reports* 2010;4:81
- 6 Castori M, Morlino S, Ritelli M, et al. Late diagnosis of lateral meningocele syndrome in a 55-year-old woman with symptoms of joint instability and chronic musculoskeletal pain. *Am J Med Genet A* 2014;164A(02):528–534