Novel Operation of Snapping Biceps Femoris Tendon

Stephen Flores, MD[1] David Hartigan, MD[2] Karan A. Patel, MD[2] Justin Roberts, MD[3] Anikar Chhabra, MD[2]

[1] Department of Sports Medicine, The Orthopedic Clinic Association, Phoenix, Arizona
[2] Department of Orthopaedic Surgery, Mayo Clinic, Scottsdale, Arizona
[3] Department of Orthopaedic Surgery, Banner Good Samaritan Medical Center, Phoenix, Arizona

Address for correspondence Anikar Chhabra, MD, MS, Department of Orthopaedic Surgery, Mayo Clinic, 5777 E. Mayo Blvd, Scottsdale, AZ 85259-5499 (e-mail: chhabra.anikar@mayo.edu).

J Knee Surg Rep 2016;2:e11–e16.

Abstract

Snapping biceps femoris tendon (BFT) over the fibular head is an uncommon cause of lateral knee pain. This study reports a case of nontraumatic painful snapping of the BFT due to a prominent fibular head that was persistent intraoperatively after fibular head resection. We describe a novel surgical technique of release of the anterior arm of the biceps tendon followed by soft tissue tenodesis to the popliteofibular ligament, as opposed to the remaining fibular head, to prevent iatrogenic fracture.

Keywords
- knee
- lateral knee pain
- snapping biceps femoris tendon
- snapping knee

Snapping biceps femoris tendon (BFT) over the fibular head is an uncommon cause of lateral knee pain, with few case reports in the literature.[1–12] Reported causes include anomalous tendon insertion, tears at the tendon insertion site, abnormality of the fibular head, and tendon subluxation despite normal anatomy. When nonoperative management fails, various surgical treatment techniques have been used, including partial fibular head resection, partial release of an offending BFT, and anatomic reductions of anomalous tendon insertions and tears.

Surgical treatment of a snapping BFT requires a thorough understanding of the complex tendon anatomy at the knee. In 1955, Sneath[13] described the insertion as a confluence of three layers in a fan-like orientation. Marshall et al[14] later described the common biceps tendon as having superficial, middle, and deep layers. The middle layer was found to envelope the lateral collateral ligament (LCL) such as a sling, providing tautness and stability to the LCL during flexion. Terry and LaPrade[15] have promoted the anatomical study of the BFT. The long head of the biceps femoris originates from the ischial tuberosity and terminates in two tendinous insertions—a direct arm that inserts on the posterolateral edge of the fibular head, lateral to the styloid and an anterior arm that inserts along the lateral edge of the fibular head, lateral to the fibular LCL.[15] Fascial components include the reflected arm, lateral aponeurosis, and anterior aponeurosis. The short head of the biceps femoris originates immediately medial to the linea aspera of the distal femur and similarly has the two direct tendinous insertions of direct arm and anterior arm.

We report on a painful snapping BFT with hypertrophy of the anterior arm of the long head of the BFT that was treated with the novel surgical technique of partial fibular head resection and tenodesis of the anterior arm to the popliteofibular ligament (PFL).

Case Report

A 42-year-old man presented to the clinic with a 1-year history of symptomatic pain and snapping localized to the lateral aspect of his left knee. He denied any history of trauma or previous knee injury. The pain and snapping were most notable with such activities as bicycling, weightlifting, and even operating the manual transmission of his car.

On physical examination, the patient was noted to have full range of motion, no joint line tenderness, and a stable ligamentous examination. He had a visible, palpable, and

received
August 28, 2016
accepted after revision
December 13, 2016
published online
February 1, 2017

DOI http://dx.doi.org/10.1055/s-0036-1598013.
ISSN 2326-2729.

Fig. 1 (**A**) Preoperative posteroanterior and lateral radiograph of patient with symptomatic snapping biceps femoris tendon. (**B**) Postoperative anteroposterior and lateral radiograph of patient with symptomatic snapping biceps femoris tendon after minimal resection of femoral head.

audible subluxation of the BFT over the fibular head when extending from 120 to 100 degrees flexion. This subluxation was exacerbated by internal rotation of the tibia and relieved by manual compression of the posterolateral thigh. Tenderness occurred to palpation over the fibular head, as well as slightly proximal along the biceps femoris. The contralateral knee was asymptomatic and without any similar physical examination findings. Anteroposterior and lateral radiographs were notable for a slightly prominent fibular head (►**Fig. 1A**). Ultrasonography and magnetic resonance imaging were negative for a bony pathologic finding, bursitis, or soft tissue inflammation.

The patient had previously undergone 9 months of conservative therapy that included ice, activity modification, anti-inflammatory medications, physical therapy, and one corticosteroid injection, which failed to provide adequate relief. Furthermore, because he was having pain and snapping during high-impact activities, he elected to proceed with surgical intervention.

The patient was placed supine on the operating table with a bump under the operative hip. Examination under anesthesia revealed obvious snapping of the BFT as the knee was taken from 120 degrees flexion to extension. A diagnostic arthroscopy, performed to rule out an intra-articular pathologic cause, was negative. Next, a 7-cm curvilinear incision was made anterior to the fibula, extending proximally to the lateral femoral condyle (►**Fig. 2A**). Blunt dissection was carried down to the iliotibial band, and the fascia was incised immediately posterior to the iliotibial band (►**Fig. 2B**). The peroneal nerve was palpated at the level of the fibular neck and dissected at this level to identify it. This allowed for visualization of the peroneal nerve for safety where the work was being done at the level of the fibular head. Since this was adequate to identify and protect the nerve, we did not perform an extensive dissection and mobilization of the nerve. The fibular head appeared to be hypertrophic at both the lateral edge and the styloid process. The anterior arm of the long head of the biceps femoris insertion was thickened, and

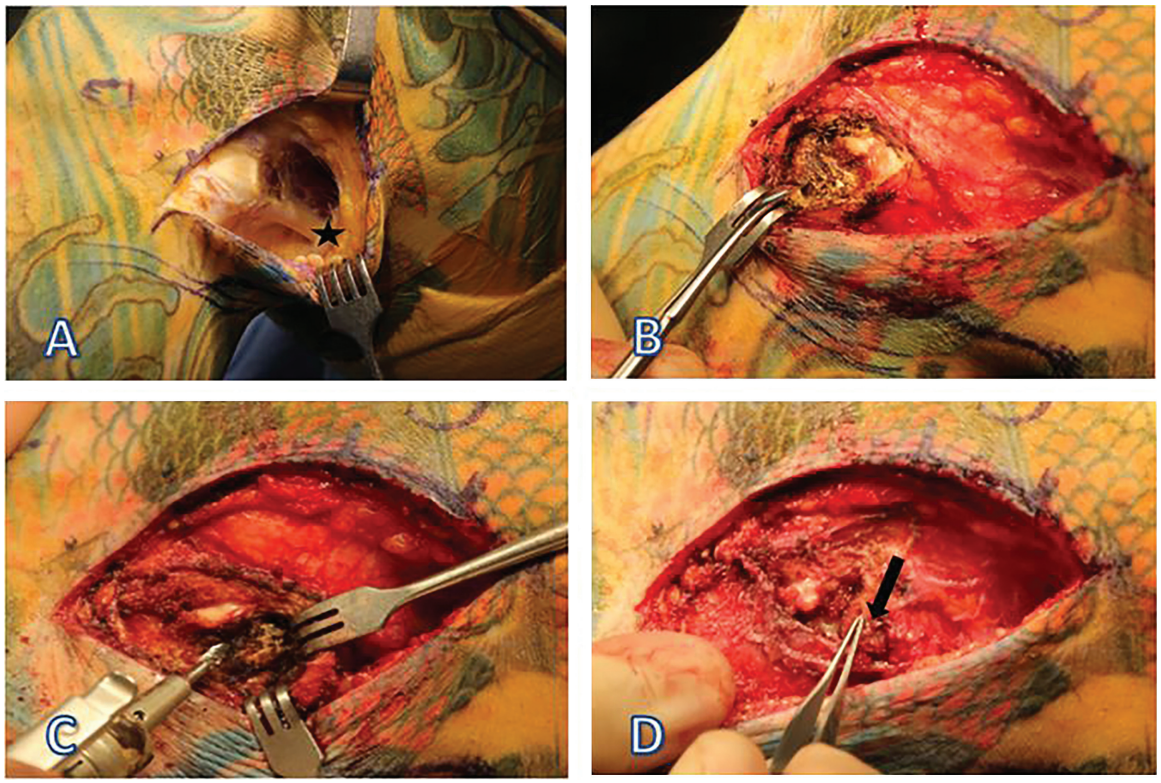

Fig. 2 Surgical treatment of snapping biceps femoris tendon. (**A**) Curvilinear incision with dissection through iliotibial band shows the biceps femoris tendon (star). (**B**) Capsular incision of fibula anterior, superior, and slightly posterior, with care not to dissect distal toward the nerve. (**C**) High-speed burr used to resect hypertrophic fibular head. (**D**) Remnant of anterior arm of long head biceps femoris tendon (arrow) is identified and a tenodesis made to the popliteofibular ligament.

the bicipital bursa was inflamed. No snapping was apparent with tourniquet insufflation; therefore, the tourniquet was released and the snapping became obvious again. The thickened anterior arm of the long head of the BFT was snapping over the hypertrophic fibular head.

The prominent areas of the fibular head were resected using a high-speed burr (►**Fig. 2C**). This was a minimal resected as to not disrupt the biceps and LCL attachments onto the fibular head (►**Fig. 1B**). A finger was kept on the identified peroneal nerve inferior to the burr to prevent it from injury. The anterior arm was partially released, and the inflamed bursa was identified and excised between the anterior arm and the LCL. At this time, the knee was again taken through a range of motion; we noted that the anterior arm continued to snap over the remaining fibular head. Given the previous resection of the hypertrophic fibular head and concern for possible iatrogenic fibular head fracture if additional drill holes or suture anchors were placed in the bone, we decided to perform a tenodesis of the anterior arm of the BFT long head to the PFL. Since the anterior arm of the BFT long head is anterior and superficial to the PFL, this was rotated 180 degrees posteriorly to lie on the PFL. This was then tenodesed using 0-suture (FiberWire; Arthrex, Inc) in a figure-of-eight manner (►**Figs. 2D, –3A, B**). Snapping was no longer evident through a full range of motion.

Postoperatively, the patient was allowed full range of motion in a hinged knee brace and weightbearing as tolerated. At his 1-week follow-up, the patient reported resolution of his symptoms. He progressed through an accelerated rehabilitation program, with return to full activities by 12 weeks. At the last follow-up via phone communication 24 months postoperatively, the patient was back to his desired level of competition five times a week, including running, biking, swimming, and lifting weights with no limitations. He denied any knee pain, swelling, or residual biceps snapping.

Discussion

To our knowledge, only 14 previous case reports of a symptomatic snapping tendon of the biceps femoris have been reported in the literature to date. ►**Table 1** summarizes all case reports found in our literature review and the present case. Thirteen male and 2 female patients have been reported (mean age, 27 years; range, 15–49 years). Among cases, 13 (87%) reported that the symptoms of a snapping biceps femoris began without significant trauma. In addition, eight case reports (53%) noted findings of asymptomatic snapping in the contralateral knee. ►**Table 2** describes common causes for a snapping BFT, as reported in the literature and the present case. Of these 15 cases, 6 (40%) were noted to have occurred because of an anomalous tendon insertion. Treatment options for a snapping BFT include partial fibular head resection, partial release of an offending biceps tendon, and anatomic reductions of anomalous tendon insertions and tears.

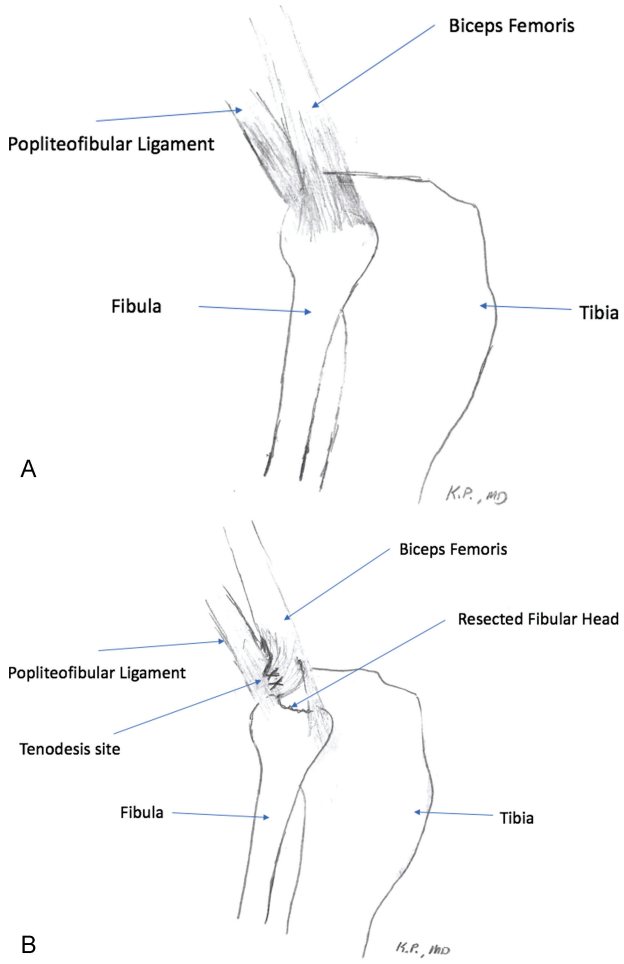

Fig. 3 (**A**) Anatomical drawing of the lateral knee with relationship of the popliteofibular ligament and biceps femoris. (**B**) Tenodesis technique demonstrated following partial resection of the fibular head.

The biceps femoris has been well studied and acts as both a static and a dynamic stabilizer to the lateral knee by functioning as knee flexor and external rotator. Marshall et al[14] noted the superficial expansion (anterior arm) of the superficial biceps tendon to specifically be a strong and important flexor lever and a major force responsible for external rotation. They further described the importance of the superficial expansion with regard to lateral stability, noting that while the LCL was taut at 10 to 30 degrees, the anterior arm was taut with knee flexion at greater than 30 degrees. The understanding that this anterior arm with tibial attachment is important for lateral stability highlights the importance of this structure when it is released in the case of a snapping BFT.

In the present case, a dilemma arose when residual snapping occurred despite resection of a prominent fibular head. If the snapping had subsided, no additional procedure would have been warranted. However, given the persistent snapping, we proceeded with release of the anterior arm. In theory, this release procedure could weaken the stabilizing effect of the biceps femoris on the lateral knee. We could have proceeded with bony tunnels or anchors to reroute the tendon back to the fibula, as described previously, but concern for possible iatrogenic fracture of the fibular head negated this option, due to the previous partial fibular head resection.

The PFL has been described as an important component of the posterolateral corner of the knee. Shahane et al[16] concluded that the PFL has both static and dynamic functions in providing important posterolateral stability by preventing posterior translation, varus angulation, and external rotation. Furthermore, the anatomic insertion posterior on the fibula helps maintain the flexor lever arm of the biceps femoris, which Brunet et al[17] highlighted as problematic for superficial transfer of the BFT in the clinical setting of anterolateral

Table 1 Reported cases of snapping biceps femoris tendon and described surgical management

Case report	Age, y/sex	Trauma	Contralateral snapping	Operative finding	Treatment
Kristensen et al (1989)[1]	20/M	No	Yes	Anomalous anterior insertion on proximal tibia	Partial fibular head resection
Lokiec et al (1992)[2]	23/M	No	Yes	Anomalous anterior insertion on fibula	Rerouted anterior one-half of tendon posteriorly with sutures
Hernandez et al (1996)[3]	16/M	No	Yes	Anomalous anterior insertion on proximal tibia	Rerouted tendon through tunnel in fibular head
Kissenberth and Wilckens (2000)[4]	20/M	No	Yes	Distal bifurcation of long head tendon anterior and direct arms	Rerouted anterior one-half of tendon posteriorly with suture anchors
Bach and Minihane (2001)[5]	24/M	No	Yes	Prominent fibular head with normal tendon insertion	Partial fibular head resection

Table 1 (*Continued*)

Case report	Age, y/sex	Trauma	Contralateral snapping	Operative finding	Treatment
Bagchi and Grelsamer (2003)[6]	22/M	No	Yes	Bilateral anomalous insertion on proximal tibia	Bilateral partial fibular head resection
Bansal et al (2005)[7]	19/M	Yes	No	Tear/attenuation of reflected arm of long head	Rerouted tendon through tunnel in fibular head
Fung et al (2008)[8]	17/M	No	Yes	Bilateral prominent fibular head (exostosis)	Bilateral partial fibular head resection (exostosis)
Crow et al (2009)[9]	49/M	No	No	Visualized subluxation; no anatomic abnormality	Partial release of superior portion of tendon
Bernhardson and LaPrade (2010)[10]	28/M	Yes	No	Tear of direct arm of long head and short head	Anatomic suture anchor repair of both long head and short head
	43/F	No	No		
	41/F	No	No		
Vavalle and Capozzi (2010)[11]	37/M	No	No	Visualized subluxation; no anatomic abnormality	Partial release of superior portion of tendon and partial fibular head resection
Date et al (2012)[12]	15/M	No	Yes	Anomalous component with anterior insertion on proximal tibia with intact anterior and direct arms	Resection of anomalous component and anterior arm with suture tenodesis to native direct arm
Present study	42/M	No	No	Tendonitis of anterior arm with prominent fibular head	Resection of anterior arm with suture tenodesis to popliteofibular ligament and partial fibular head resection

Abbreviations: F, female; M, male.

rotary instability. Therefore, tenodesis of the anterior arm posteriorly to the PFL appears a viable option when fibular head resection is substantial with persistent snapping and, at the same time, it would reinforce an important component of the posterolateral corner of the knee.

Various treatment options have been described for a painful snapping BFT, including partial fibular head resection, partial release of an offending biceps tendon, and anatomic reductions of anomalous tendon insertions and tears. We have described a novel technique of fibular head resection and partial resection of the biceps femoris insertion with tenodesis to the PFL. This surgical approach is viable when the surgeon gives anatomic consideration to the critical stabilizing structures of the posterolateral corner of the knee, in addition to avoiding the potential catastrophic complication of iatrogenic fibular head fracture.

Table 2 Etiologic factors of snapping biceps femoris tendon by case reports

Etiologic factor	Cases reported, No. (%)
Anomalous tendon insertion	6 (40)
Tendon tear at insertion	4 (27)
Fibular head prominence	3 (20)
No anatomic abnormality	2 (13)

References

1 Kristensen G, Nielsen K, Blyme PJ. Snapping knee from biceps femoris tendon. A case report. Acta Orthop Scand 1989;60(05): 621

2 Lokiec F, Velkes S, Schindler A, Pritsch M. The snapping biceps femoris syndrome. Clin Orthop Relat Res 1992;((283):205–206

3 Hernandez JA, Rius M, Noonan KJ. Snapping knee from anomalous biceps femoris tendon insertion: a case report. Iowa Orthop J 1996;16:161–163

4 Kissenberth MJ, Wilckens JH. The snapping biceps femoris tendon. Am J Knee Surg 2000;13(01):25–28

5 Bach BR Jr, Minihane K. Subluxating biceps femoris tendon: an unusual case of lateral knee pain in a soccer athlete. A case report. Am J Sports Med 2001;29(01):93–95
6 Bagchi K, Grelsamer RP. Partial fibular head resection for bilateral snapping biceps femoris tendon. Orthopedics 2003;26(11): 1147–1149
7 Bansal R, Taylor C, Pimpalnerkar AL. Snapping knee: an unusual biceps femoris tendon injury. Knee 2005;12(06):458–460
8 Fung DA, Frey S, Markbreiter L. Bilateral symptomatic snapping biceps femoris tendon due to fibular exostosis. J Knee Surg 2008; 21(01):55–57
9 Crow SA, Quach T, McAllister DR. Partial tendon release for treatment of a symptomatic snapping biceps femoris tendon: a case report. Sports Health 2009;1(05):435–437
10 Bernhardson AS, LaPrade RF. Snapping biceps femoris tendon treated with an anatomic repair. Knee Surg Sports Traumatol Arthrosc 2010;18(08):1110–1112
11 Vavalle G, Capozzi M. Symptomatic snapping knee from biceps femoris tendon subluxation: an unusual case of lateral pain in a marathon runner. J Orthop Traumatol 2010;11(04):263–266
12 Date H, Hayakawa K, Nakagawa K, Yamada H. Snapping knee due to the biceps femoris tendon treated with repositioning of the anomalous tibial insertion. Knee Surg Sports Traumatol Arthrosc 2012;20(08):1581–1583
13 Sneath RS. The insertion of the biceps femoris. J Anat 1955;89(04): 550–553
14 Marshall JL, Girgis FG, Zelko RR. The biceps femoris tendon and its functional significance. J Bone Joint Surg Am 1972;54(07): 1444–1450
15 Terry GC, LaPrade RF. The biceps femoris muscle complex at the knee. Its anatomy and injury patterns associated with acute anterolateral-anteromedial rotatory instability. Am J Sports Med 1996;24(01):2–8
16 Shahane SA, Ibbotson C, Strachan R, Bickerstaff DR. The popliteofibular ligament. An anatomical study of the posterolateral corner of the knee. J Bone Joint Surg Br 1999;81(04): 636–642
17 Brunet ME, Kester MA, Cook SD, Leinhardt TM, Haddad RJ Jr. Biomechanical evaluation of superficial transfer of the biceps femoris tendon. Am J Sports Med 1987;15(02):103–110