

Magnetic Resonance Imaging in a Neurofibromatosis Type 2 Patient with a Novel MRI-Compatible Auditory Brainstem Implant

Matthew Shew¹ Judson Bertsch² Paul Camarata³ Hinrich Staecker¹

¹Department of Otolaryngology Head and Neck Surgery, University of Kansas School Medical Center, Kansas City, Kansas, United States

²Department of Diagnostic Radiology, University of Kansas School Medical Center, Kansas City, Kansas, United States

³Department of Neurosurgery, University of Kansas School Medical Center, Kansas City, Kansas, United States

Address for correspondence Hinrich Staecker, MD, PhD, University of Kansas Medical Center, Department Otolaryngology Head and Neck Surgery, 3901 Rainbow Boulevard, Kansas City, KS 66160, United States (e-mail: hstaecker@kumc.edu).

J Neurol Surg Rep 2017;78:e12–e14.

Abstract

Auditory brainstem implantation has become a key technique for the rehabilitation of hearing in patients with neurofibromatosis type 2. The nature of this devastating genetic disease requires ongoing MRI for the patient's lifespan. Today, most auditory brainstem implants require removal of the magnet that connects the internal device to the external speech processor to undergo imaging as their disease progresses. Patients have the option of having a short procedure to have the magnet taken out and replaced each time, or alternately using a headband to secure the processor over the receiver coil of the internal device. Novel magnet technology has led to the development of a freely rotating magnet that can be used inside the magnetic field of an MRI scanner without losing magnet strength and without being displaced from the body of the device. We report one of the first patients implanted with a Med-El Synchrony ABI in the United States who subsequently underwent successful imaging with MRI 1.5 tesla to follow for other existing schwannomas.

Keywords

- ▶ neurofibromatosis type 2
- ▶ auditory brainstem implant
- ▶ magnetic resonance imaging

Introduction

Auditory brainstem implant (ABI) was first introduced in 1979 by William House and William Hitselberger, which enabled them to successfully demonstrate hearing by direct stimulation of the cochlear nucleus by two ball electrodes.¹ To date the only the Food and Drug Administration (FDA)-approved use of an ABI in the United States is for neurofibromatosis type 2 (NF2)—a genetic disease characterized by aberrant growth along Schwann cells throughout the central nervous system, particularly pathognomonic for bilateral acoustic schwannomas. Secondary to NF2 patient's propensity to have other cranial nerve schwannomas, close surveillance in the form of yearly magnetic resonance imaging (MRI) is necessary. However, the only ABI device currently FDA approved in the United States is Nucleus 24 ABI (Cochlear

Corporation, Englewood, Colorado, United States) sometimes necessitates a separate surgical procedure for removal of the internal magnet for every MRI or external compression device to try and minimize magnet displacement.² New ABI devices have been introduced to European markets that are MRI compatible, particularly Med-El Mi1200 Synchrony ABI (Med-El Medical Electronics, Innsbruck, Austria), which allows routine MRI surveillance. Here we present a case report on a young woman with NF2 who underwent Synchrony ABI placement with subsequent successful MRI surveillance of other cranial nerve schwannomas.

Case Report

The patient is a 27-year-old woman who was initially referred for poor balance; subsequent workup led to bilateral vestibular

received
August 5, 2016
accepted after revision
November 7, 2016

DOI <http://dx.doi.org/10.1055/s-0036-1597588>.
ISSN 2193-6358.

© 2017 Georg Thieme Verlag KG
Stuttgart · New York

License terms



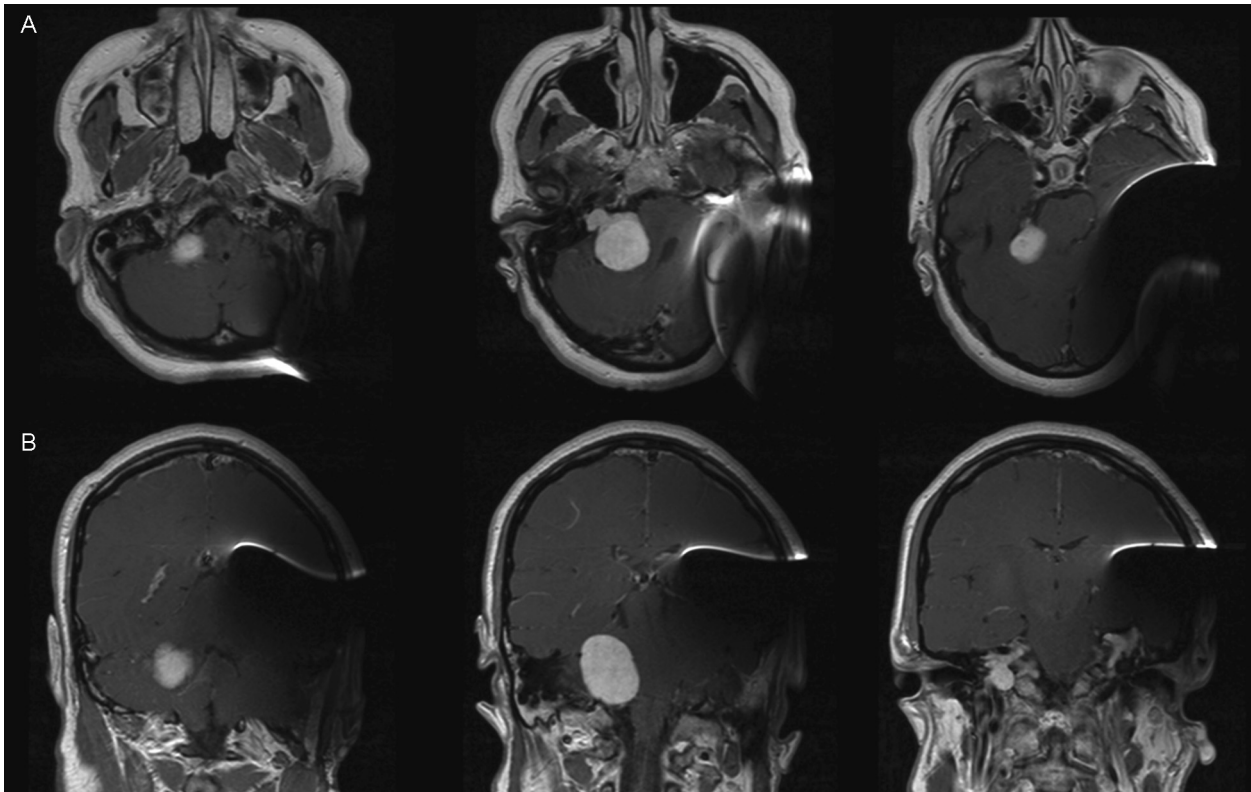


Fig. 1 MRI with a Med-El Synchrony auditory brainstem implant (ABI) demonstrates clear and quality images of the contralateral homogeneously enhancing cerebellopontine mass. The ABI creates moderate metallic artifact distortion that limits evaluation of the ipsilateral cerebral and cerebellar hemispheres. (A) Axial view sequence from inferior to superior (left to right). (B) Coronal view sequence from anterior to posterior (left to right).

schwannomas along with other peripheral nerve tumors along the spinal cord leading to the diagnosis of NF2. Our patient who underwent observation for some time, however, started developing hydrocephalus secondary to compression along the brainstem from increasing left vestibular schwannoma growth. She underwent left translabyrinthine resection with sacrifice of the vestibulocochlear nerve complex. Over time she developed increasing contralateral tumor growth, ultimately leading to profound hearing loss with 0% speech discrimination. At that point she elected to undergo left ABI placement with Med-El Mi1 1200 Synchrony ABI. While not FDA approved in the United States, exemption was sought because of its MRI compatibility up to 1.5 tesla (T), which was necessary for surveillance of her right vestibular schwannoma, right jugular foramen schwannoma, and myriad of spinal schwannomas.

She underwent placement of ABI and activation without difficulty or complications. Subsequent follow-up, she noted improvement in perception of environmental sounds and improvement in understanding others; however, she still struggled with clarity of speech. Twelve months post ABI placement, she underwent MRI scanning to monitor her other tumors using multiplanar and multisequence MRI before and after gadolinium contrast. While metallic artifact secondary to the ABI limited examination of the left cerebral and cerebellar hemispheres, MRI with the ABI successfully and clearly demonstrated large homogeneously enhancing cerebellopontine angle mass filling and expanding the inter-

nal auditory canal measuring 3.7×2.9 cm along with mass effect on the fourth ventricle and upper pons without evidence of obstruction (► Fig. 1). Furthermore, MRI with the ABI in place clearly demonstrated the right jugular foramen and upper cervical spinal schwannomas without distortion.

Discussion

To our knowledge, this is the first case report of an MRI-compatible ABI in an NF2 patient in the United States. Studies have shown that the most devastating impacts of NF2 are deafness and overcoming communication barriers that lead to not only strain on social and personal relationships but mood and self-confidence.^{3,4} These findings emphasize the importance of hearing rehabilitation in patients with NF2. However, hearing rehabilitation goals have to strike a balance with practitioner's ability to safely monitor disease progress. Currently the gold standard for disease surveillance is with MRI.

The only FDA approved ABI currently available in the United States is the Nucleus 24 ABI, which contains an internal magnet within the implant receiver. Traditionally the internal magnet has been a contraindication to MRI because of the torque introduced to the device by the coil of the magnetic resonance imager putting the device and patient at risk.^{5,6} This often necessitated separate surgical intervention with magnet removal and replacement, which puts the device at high risk for damage or infection.^{7,8}

Recently there has been a push for securement with an external compression device for cochlear implants (CIs) that contain an internal magnet, alleviating the need for separate surgical procedure. Gubbels and McMenemy (2006) examined 16 cadaver heads with Nucleus 24 CI, in which they demonstrated that without proper securement 14 of the 16 had moderate to severe displacement of the magnetic device while undergoing MRI.⁹ However, in this same study they found that if properly secured with a compression device, minimal displacement was seen⁹; this eventually led to studies that solidified Nucleus 24 CI as FDA approved for the use of MRI at 1.5 T when properly secured with a compression device.^{10,11} On the other hand, there is no FDA-approved ABI that is MRI compatible in the United States.

Unique to the Med-El Synchrony ABI, a compression device is not necessary, thus eliminating any inconvenience or hesitation for emergent MRI. Our patient and device has undergone seven MRIs of the head, C spine, and T spine without any issues or demagnetization to the device while still providing quality images (►Fig. 1). The Med-El is MRI compatible because it has a freely rotating and self-aligning diametric magnet, thus preventing torque pressure or demagnetization from the surrounding MRI field. While the ABI is not FDA approved for MRI use, there is some evidence that external securement for MRI up to 1.5 T is safe. Walton et al (2014) most recently examined 10 patients with NF2 who underwent Nucleus ABI placement in the United Kingdom, and they found no altered implant function of demagnetization while undergoing MRI at 1.5 T.¹² However, they did not investigate device displacement, thus questioning the cumulative effect on the device after multiple MRI procedures. Furthermore, while the Synchrony is approved in Europe for up to 1.5 T, the same device design with a freely rotating and self-aligning magnet for its CI model is the only approved CI for up to 3 T.¹³ Use of a 3 T scanner would result in a larger metal artifact, potentially decreasing the advantage of this device. Wearing the external device is easier when an internal magnet can be used to position the external device over the receiver coil. While the Synchrony device does not in itself reduce artifact, the mobile internal magnet allows for repeated MRI without magnet removal, improves patient comfort, and decreases the risk of displacement that offers a significant advantage to patient care.

Note

The authors have no funding, financial relationships, or conflicts of interest to disclose.

References

- 1 Edgerton BJ, House WF, Hitselberger W. Hearing by cochlear nucleus stimulation in humans. *Ann Otol Rhinol Laryngol Suppl* 1982;91(2 Pt 3):117–124
- 2 Heller JW, Brackmann DE, Tucci DL, Nyenhuis JA, Chou CK. Evaluation of MRI compatibility of the modified nucleus multi-channel auditory brainstem and cochlear implants. *Am J Otol* 1996;17(5):724–729
- 3 Neary WJ, Hillier VF, Flute T, Stephens D, Ramsden RT, Evans DG. Use of a closed set questionnaire to measure primary and secondary effects of neurofibromatosis type 2. *J Laryngol Otol* 2010;124(7):720–728
- 4 Patel CM, Ferner R, Grunfeld EA. A qualitative study of the impact of living with neurofibromatosis type 2. *Psychol Health Med* 2011;16(1):19–28
- 5 Portnoy WM, Mattucci K. Cochlear implants as a contraindication to magnetic resonance imaging. *Ann Otol Rhinol Laryngol* 1991;100(3):195–197
- 6 Teissl C, Kremser C, Hochmair ES, Hochmair-Desoyer JJ. Magnetic resonance imaging and cochlear implants: compatibility and safety aspects. *J Magn Reson Imaging* 1999;9(1):26–38
- 7 Azadarmaki R, Tubbs R, Chen DA, Shellock FG. MRI information for commonly used otologic implants: review and update. *Otolaryngol Head Neck Surg* 2014;150(4):512–519
- 8 Migirov L, Wolf M. Magnet removal and reinsertion in a cochlear implant recipient undergoing brain MRI. *ORL J Otorhinolaryngol Relat Spec* 2013;75(1):1–5
- 9 Gubbels SP, McMenemy SO. Safety study of the Cochlear Nucleus 24 device with internal magnet in the 1.5 tesla magnetic resonance imaging scanner. *Laryngoscope* 2006;116(6):865–871
- 10 Crane BT, Gottschalk B, Kraut M, Aygun N, Niparko JK. Magnetic resonance imaging at 1.5 T after cochlear implantation. *Otol Neurotol* 2010;31(8):1215–1220
- 11 Nucleus 24. Magnetic Resonance Imaging. [cited 2016 6/12/16]. <http://professionals.cochlearamericas.com/sites/default/files/resources/MRI.pdf>. Accessed November 29, 2016
- 12 Walton J, Donnelly NP, Tam YC, et al. MRI without magnet removal in neurofibromatosis type 2 patients with cochlear and auditory brainstem implants. *Otol Neurotol* 2014;35(5):821–825
- 13 Medical Procedures for MED-EL Implant Systems. [cited 2016 6/12/2016]. http://s3.medel.com.s3.amazonaws.com/documents/AW/AW33290_30_Manual%20Medical%20Procedures%20-%20EN%20English%20US_web.pdf. Accessed November 29, 2016