

Pyometra and Pregnancy with Herlyn-Werner-Wunderlich Syndrome

Piometria e gravidez com síndrome de Herlyn-Werner-Wunderlich

Maria Inês Reis¹ Ana Patrícia Vicente¹ Joana Cominho¹ Andrea Sousa Gomes¹ Luísa Martins¹
Filomena Nunes¹

¹Department of Obstetrics and Gynecology and Department of Maternal Fetal Medicine, Hospital Dr. José de Almeida, Lisbon, Portugal

Rev Bras Ginecol Obstet 2016;38:623–628.

Address for correspondence Maria Inês Reis, Medical Resident, Department of Obstetrics and Gynecology and Department of Maternal Fetal Medicine Hospital Dr. José de Almeida, Rua Dr. Henrique Martins Gomes, 1600-396 Lisbon, Portugal (e-mail: ines.reis.maria@gmail.com).

Abstract

Keywords

- ▶ Herlyn-Werner-Wunderlich syndrome
- ▶ pyometra
- ▶ pregnancy
- ▶ magnetic resonance imaging and ultrasonography

We describe a Herlyn-Werner-Wunderlich syndrome (HWWS) patient with previous history of infertility who got pregnant without treatment and presented a pyometra in the contralateral uterus throughout the gestational period, despite multiple antibiotic treatments. Due to the uterus' congenital anomaly and the possibility of ascending infection with subsequent abortion, this pregnancy was classified as high-risk. We believe that the partial horizontal septum in the vagina may have contributed to the closure of the gravid uterus cervix, thus ensuring that the pregnancy came to term, with an uneventful vaginal delivery.

Resumo

Palavras-Chave

- ▶ síndrome de Herlyn-Werner-Wunderlich
- ▶ piometra
- ▶ gravidez
- ▶ ultrasonografia e ressonância magnética

Os autores descrevem uma paciente com síndrome de Herlyn-Werner-Wunderlich (SHWW) e história prévia de infertilidade, que engravidou espontaneamente. Durante todo o período gestacional apresentou, apesar da instituição de antibioticoterapia, um piometra localizado ao útero não gravídico. Devido à anomalia congênita uterina e ao risco de infecção ascendente, com possível desfecho obstétrico desfavorável, esta gravidez foi classificada de alto risco. O septo vaginal horizontal e parcial poderá ter contribuído para ausência de disseminação da infecção, permitindo que a gravidez tenha chegado a termo, com um parto vaginal, sem intercorrências.

Introduction

Mullerian duct anomalies (MDAs) are congenital defects of the female genital system that arise from the abnormal embryological development of the Mullerian ducts.^{1,2} These abnormalities include a wide range of developmen-

tal anomalies, resulting from failure of development, defective fusion or defects in regression of the septum during fetal development. A review of the prevalence of different types of uterine malformations revealed that uterus didelphys was found to be the second least common of all MDAs.³

received
June 29, 2016
accepted
October 3, 2016
published online
December 21, 2016

DOI <http://dx.doi.org/10.1055/s-0036-1594304>.
ISSN 0100-7203.

Copyright © 2016 by Thieme-Revinter Publicações Ltda, Rio de Janeiro, Brazil

License terms



Herlyn-Werner-Wunderlich syndrome (HWWS), also known as obstructed hemivagina and ipsilateral renal anomaly (OH-VIRA) syndrome was first described in 1971–1976.^{4,5} It is a rare congenital anomaly of the female genital tract characterized by uterus didelphys, ipsilateral renal agenesis and blind hemivagina. Its prevalence is difficult to ascertain, but it is estimated to be 0.1–3.8%.¹ In the literature, the syndrome often appears as a single case report or as a small series.^{3,6–9} Patients with this disorder usually present, shortly after menarche, with intermittent dysmenorrhea, irregular vaginal hemorrhage, mucopurulent discharge, acute pelvic pain or palpable mass due to the associated hematocolpos or hematometra, which result from retained long standing menstrual flow in the obstructed hemivagina.

The rarity of this condition may contribute to diagnostic delay. Early diagnosis with appropriate surgical intervention with vaginoplasty and vaginal septostomy decreases the long-term morbidity of these women.^{10,11} The surgical outcome is excellent, and it is associated with a successful reproductive performance in the future.

In this case report we discuss a rare case of a HWWS patient who kept a chronic purulent discharge throughout all

pregnancy, but carried her pregnancy to term and delivered vaginally without complications.

Case Report

A 27-year-old nulliparous woman, with menarche at age 12 and normal menses. The patient did not report having dysmenorrhea; however, intermittent dyspareunia, chronic pelvic pain and abundant vaginal purulent discharge episodes were present in the past. Her medical history was significant for a congenitally absent right kidney, diagnosed at age 15, and infertility history for over 6 years. The infertility causes of the couple were investigated, and the magnetic resonance imaging (MRI) identified a uterus didelphys with partial longitudinal vaginal septum, moderated hematocolpos in the right hemi-uterus, ipsilateral renal agenesis and right ureteral ectasia with ectopic vesical insertion, suggestive of renal scar regression (►Fig. 1). The patient had not had any treatment at that point, as she ceased to attend infertility appointments.

She achieved a spontaneous pregnancy and was referred to our prenatal care department, in first trimester, due to the

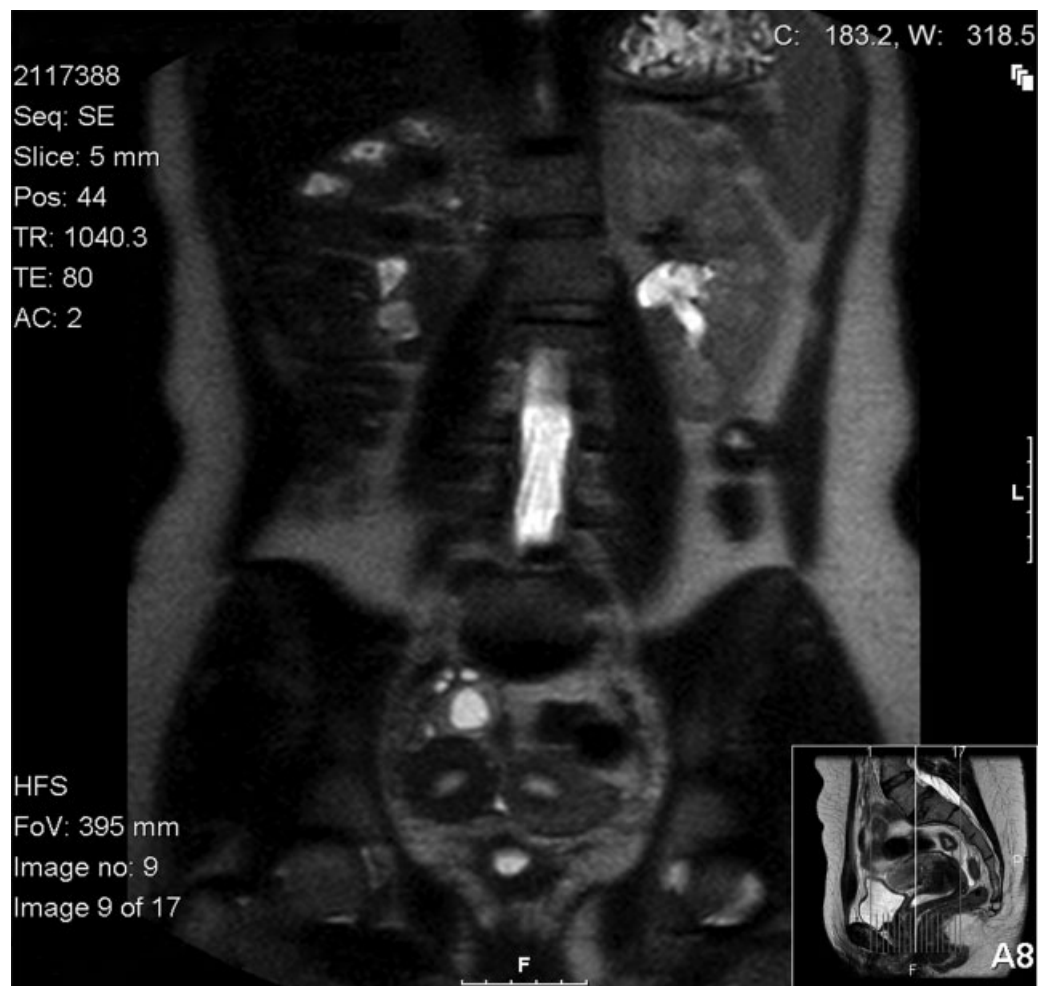


Fig. 1 Coronal abdomino-pelvic MRI – uterus didelphys, ipsilateral renal agenesis, and right ureteral ectasia with ectopic vesical insertion.

uterine anomaly and its associated risks, as well as complaints of pelvic pain and vaginal purulent discharge.

The general physical examination was unremarkable. Copious quantities of yellowish discharge from the left-side cervix were found on the speculum exam. A vaginal swab was collected, and cultures of *Streptococcus oralis* and *mitis* stains were isolated. The laboratory evaluations, including leukogram and c-reactive protein (CRP), were within normal limits. The patient was started on cefuroxime according to an antibiotic susceptibility test, and continued daily antibiotic prophylaxis with 1 g Amoxicillin throughout pregnancy.

The pelvic ultrasound scan revealed a single fetus on the left hemi-uterus, and the right hemi-uterus was filled with fluid with altered echogenicity. Two separate cervixes were documented, the left anterior and right posterior (► **Fig. 2** and **3**).

The patient attended a Maternal-Fetal Medicine consultation, and serial evaluations of inflammatory parameters and cervical length were performed throughout the pregnancy, and they remained within normal limits. The fetus showed appropriate growth monitored in a serial ultrasound every four weeks.

The patient experienced spontaneous labor at 39 weeks. The partial septum was not an impediment to the vaginal birth, and a healthy female newborn weighing 2,645 g was delivered. The postpartum period progressed uneventfully. She was discharged within 48 hours postpartum (► **Fig. 4**).

In the absence of any signs and symptoms, the routine assessment of the maternal health was undertaken six weeks after delivery, and the partial vaginal septum was not found.

Discussion

Herlyn-Werner-Wunderlich syndrome is extremely rare. To our knowledge, there are five cases of pregnancies associated to HWWS,¹²⁻¹⁵ seven cases of HWWS with pyocolpos,¹⁶⁻²² one case of pregnancy in HWWS with pyocolpos,²³ and two cases of pregnancy with pyocolpos in a uterus didelphys.^{24,25}

According to the European Society of Human Reproduction and Embryology (ESHRE) and the European Society for Gynecological Endoscopy (ESGE)²⁶ consensus on the Classification of Female Genital tract congenital anomalies, HWWS appears to be included in Class U3B uterine anomaly, class C2 cervix anomaly, and class V3 vaginal anomaly.

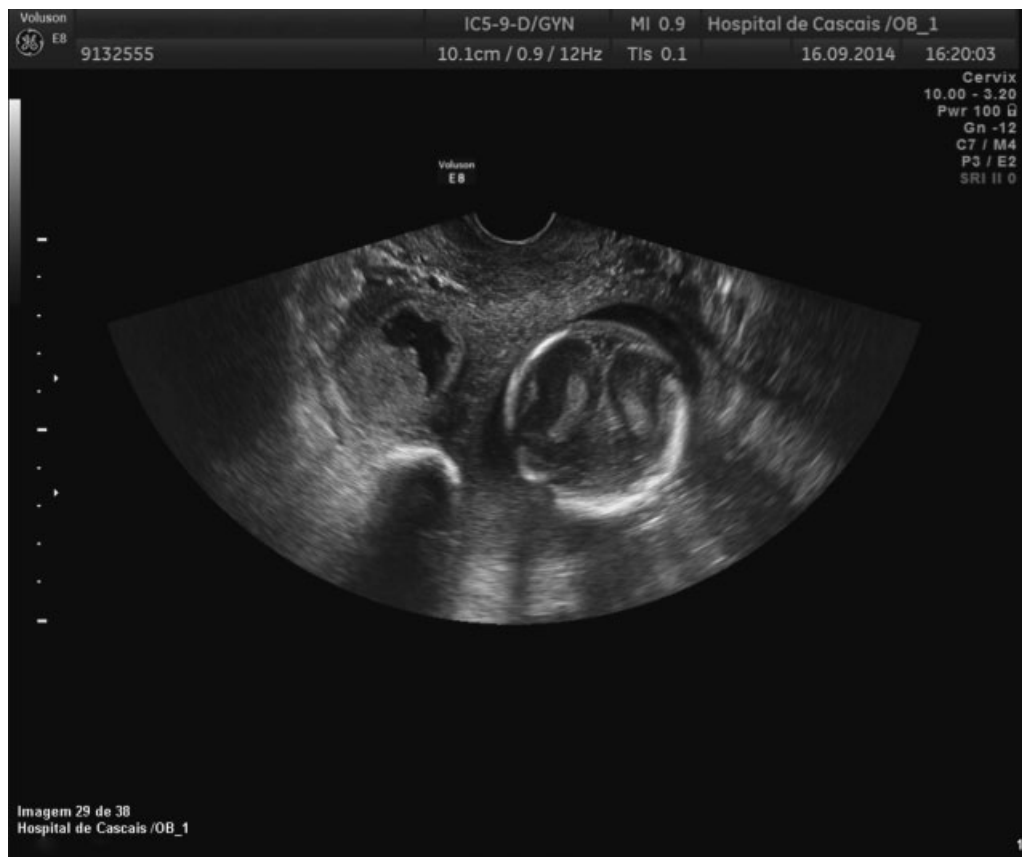

Fig. 2 Pelvic ultrasound scan – fetus on the left hemi-uterus and right hemi-uterus with altered echogenicity fluid (*).

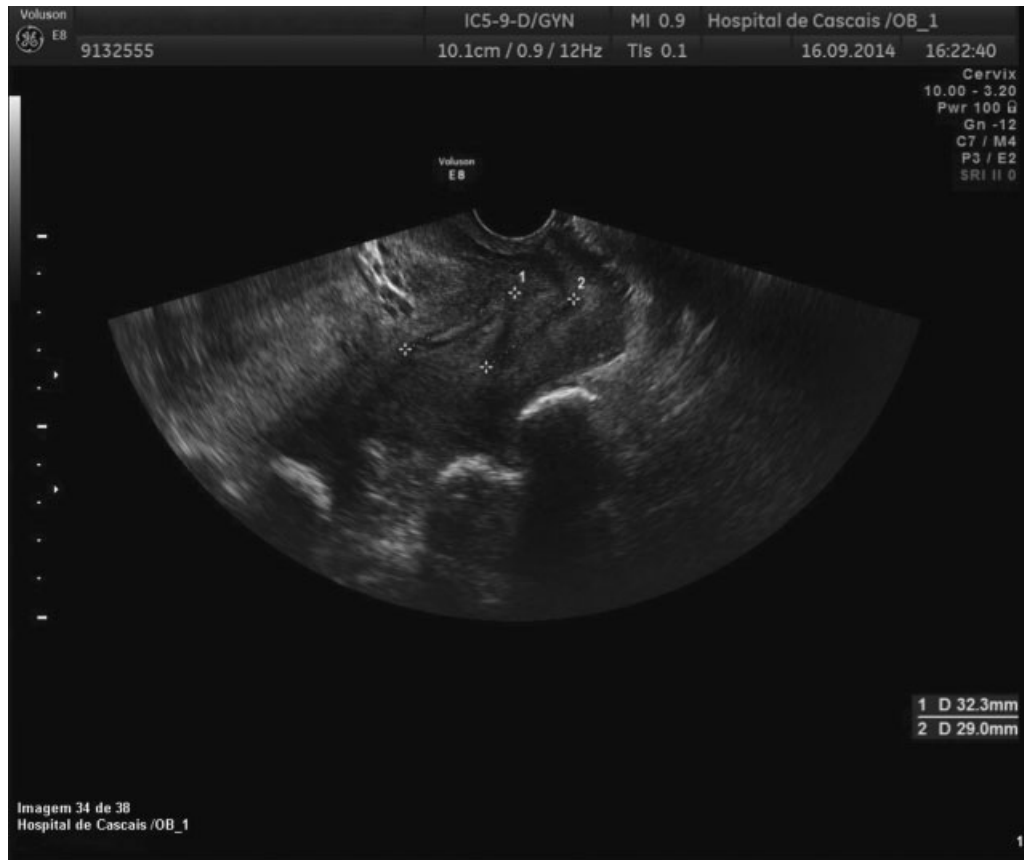

Fig. 3 Pelvic ultrasound – two separate cervixes, left anterior (32.3 mm) and right posterior (29 mm).

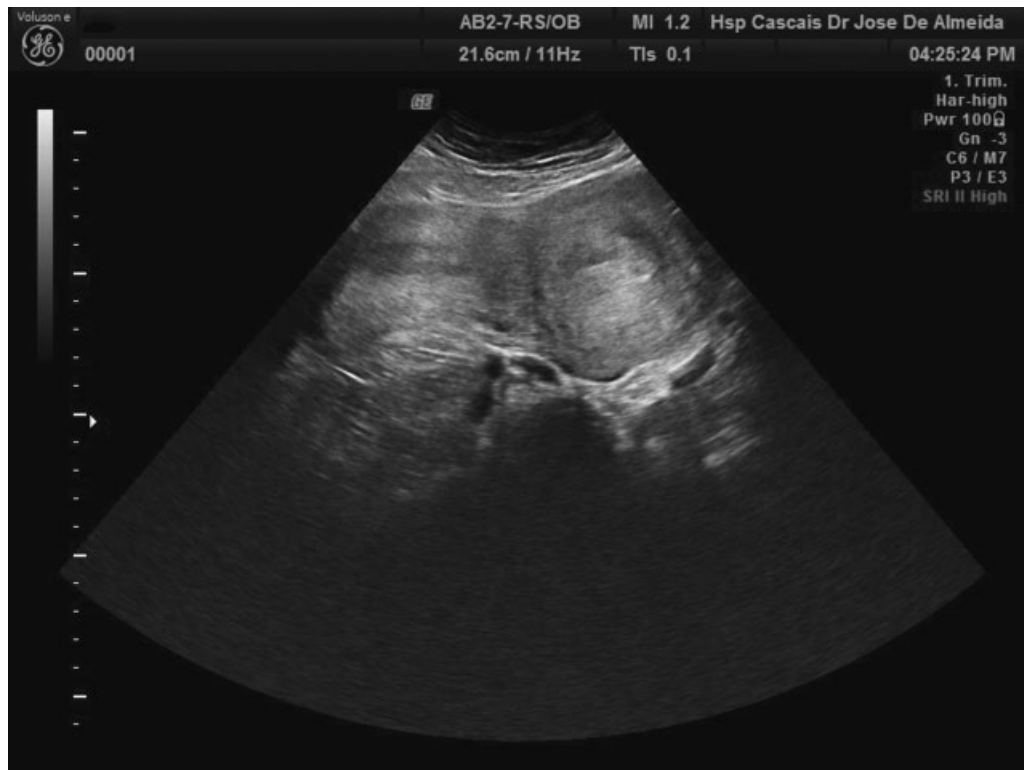

Fig. 4 Postpartum pelvic ultrasound.

Herlyn-Werner-Wunderlich syndrome is commonly diagnosed at the time of menarche. The vaginal septum is generally longitudinal, and can have a variable thickness. Delay in diagnosis is common especially due to: the communication between the two cavities, from the incomplete hemivaginal obstruction; septum elasticity; and the use of drugs, such as oral contraceptives and non-steroidal anti-inflammatory drugs, which might minimize symptoms and, therefore, further delay the recognition of the condition. A high index of suspicion is required to diagnose these cases at an early stage, avoiding complications, such as retrograde tubal reflux and consequent endometriosis and infertility.^{27,28}

When clinical signs and symptoms are present, the ultrasonography is usually the initial image exam performed, but it is highly dependent on the expertise of the operator. Magnetic resonance imaging is considered the gold standard for diagnosis and preoperative planning for the treatment of HWWS.^{29–31}

Treatment should be individualized depending on complaints, and the main goal is to relieve the obstruction by remodeling the vagina. Some vaginal septa can be easily displaced to the side, and others may be thick enough to cause symptoms, and therefore require surgical excision. Our patient was essentially asymptomatic, which explains the late diagnosis of this condition, during an infertility investigation. The presence of a partial vaginal septum can lead to late diagnosis due to the lack of exuberant symptoms, as menses can outflow throughout that communication.

Congenital developmental anomalies of the Müllerian ducts are a significant etiological factor of infertility, and are associated with an increment in obstetrical complication. A recent meta-analysis³² revealed that uterus didelphys was associated with increased rates of preterm delivery and higher incidence of fetal breech presentation in comparison with women with a normal uterus. Other studies^{30,33} revealed other obstetric complications, namely miscarriage, premature rupture of membranes, and intrauterine growth restriction among patients with uterus didelphys. Therefore, more frequent and rigorous obstetric monitoring is required to identify potential obstetric complications. In our case, we performed serial transvaginal ultrasounds, from the twentieth week forward, for preterm birth screening. Cervical incompetence is not usually associated with uterus didelphys, and therefore cerclage is not routinely used. In order to screen intrauterine growth restriction, an increased frequency of surveillance was performed, with serial ultrasound estimation of fetal weight, along with an umbilical artery Doppler study.

Drainage of pus with a urinary catheter or dilatation of the cervix was not considered due to the abundant outflow of discharge. The pyometra was treated with antibiotics, according to culture and sensitivity. However, every time the antibiotic was discontinued, yellowish vaginal discharge and intermittent pelvic pain complaints worsened, which justified the maintenance of the antibiotic throughout the pregnancy.

We presume that a partial vaginal septum might have been critical to the success of the pregnancy, preventing the ascending infection of the pregnant uterus.

A uterus didelphys is not an indication for cesarean delivery, and thus vaginal delivery should be considered first, if there is no obstruction of the birth canal.^{34–36}

The absence of similar cases in the literature proved to be a challenge in the management of this clinical case. Careful attention is necessary for early recognition and appropriate management of this condition for a successful outcome.

Consent

Written informed consent was obtained from the patient for the publication of this case report and accompanying images. A copy of the written consent is available for review by the Editor-in-Chief of this journal.

References

- Burgis J. Obstructive Müllerian anomalies: case report, diagnosis, and management. *Am J Obstet Gynecol* 2001;185(2):338–344
- Tridenti G, Armanetti M, Flisi M, Benassi L. Uterus didelphys with an obstructed hemivagina and ipsilateral renal agenesis in teenagers: report of three cases. *Am J Obstet Gynecol* 1988;159(4):882–883
- Gholoum S, Puligandla PS, Hui T, Su W, Quiros E, Laberge JM. Management and outcome of patients with combined vaginal septum, bifid uterus, and ipsilateral renal agenesis (Herlyn-Werner-Wunderlich syndrome). *J Pediatr Surg* 2006;41(5):987–992
- Herlyn U, Werner H. [Simultaneous occurrence of an open Gartner-duct cyst, a homolateral aplasia of the kidney and a double uterus as a typical syndrome of abnormalities]. *Geburtshilfe Frauenheilkd* 1971;31(4):340–347
- Wunderlich M. [Unusual form of genital malformation with aplasia of the right kidney]. *Zentralbl Gynakol* 1976;98(9):559–562
- Zurawin RK, Dietrich JE, Heard MJ, Edwards CL. Didelphic uterus and obstructed hemivagina with renal agenesis: case report and review of the literature. *J Pediatr Adolesc Gynecol* 2004;17(2):137–141
- Tong J, Zhu L, Chen N, Lang J. Endometriosis in association with Herlyn-Werner-Wunderlich syndrome. *Fertil Steril* 2014;102(3):790–794
- Candiani GB, Fedele L, Candiani M. Double uterus, blind hemivagina, and ipsilateral renal agenesis: 36 cases and long-term follow-up. *Obstet Gynecol* 1997;90(1):26–32
- Tong J, Zhu L, Lang J. Clinical characteristics of 70 patients with Herlyn-Werner-Wunderlich syndrome. *Int J Gynaecol Obstet* 2013;121(2):173–175
- Smith NA, Laufer MR. Obstructed hemivagina and ipsilateral renal anomaly (OHVIRA) syndrome: management and follow-up. *Fertil Steril* 2007;87(4):918–922
- Grimbizis GF, Camus M, Tarlatzis BC, Bontis JN, Devroey P. Clinical implications of uterine malformations and hysteroscopic treatment results. *Hum Reprod Update* 2001;7(2):161–174
- Cozzolino M, Corioni S, Magro Malosso ER, Sorbi F, Mecacci F. Two successful pregnancies in Herlyn-Werner-Wunderlich syndrome. *J Obstet Gynaecol* 2014;34(6):534–535
- Mirković L, Ljubić A, Janjić T, et al. [Term pregnancy after minimally invasive surgical treatment of Herlyn-Werner-Wunderlich syndrome]. *Srp Arh Celok Lek* 2013;141(7-8):524–527

- 14 Novachkov L, Sirakov M. [Pregnancy and labor in a woman with Herlyn-Werner-Wunderlich syndrome]. *Akush Ginekol (Sofia)* 1986;25(1):91-94
- 15 Cortés-Contreras DK, Juárez-Cruz PM, Vázquez-Flores J, Vázquez-Flores AD. [Obstructed hemivagina and ipsilateral renal anomaly: unusual cause of pyocolpos. Report a case and review of literature]. *Ginecol Obstet Mex* 2014;82(10):711-715
- 16 Wozniakowska E, Torres A, Milart P, et al. Delayed diagnosis of Herlyn-Werner-Wunderlich syndrome due to microperforation and pyocolpos in obstructed vaginal canal. *J Pediatr Adolesc Gynecol* 2014;27(4):e79-e81
- 17 Alumbremos-Andújar MT, Aguilar-Galán EV, Pérez-Parra C, Céspedes-Casas C, Ramírez-Gómez M, González-López A. [Pelvic inflammatory disease due to Herlyn-Werner-Wunderlich syndrome]. *Cir Cir* 2014;82(4):448-452
- 18 Cox D, Ching BH. Herlyn-Werner-Wunderlich syndrome: a rare presentation with pyocolpos. *J Radiol Case Rep* 2012;6(3):9-15
- 19 Sharma D, Janu MK, Gaikwad R, Usha MG. Herlyn-Werner-Wunderlich syndrome complicated with pyocolpos: an unusual cause of postabortal sepsis. *J Gynecol Endosc Surg* 2011;2(2):105-108
- 20 Arıkan İl, Harma M, Harma Mİ, Bayar U, Barut A. Herlyn-Werner-Wunderlich syndrome (uterus didelphys, blind hemivagina and ipsilateral renal agenesis) - a case report. *J Turk Ger Gynecol Assoc* 2010;11(2):107-109
- 21 Tug N, Sargin MA, Çelik A, Alp T, Yenidede I. Treatment of virgin OHVIRA syndrome with haematometrocolpos by complete incision of vaginal septum without hymenotomy. *J Clin Diagn Res* 2015;9(11):QD15-QD16
- 22 Rana R, Pasrija S, Puri M. Herlyn-Werner-Wunderlich syndrome with pregnancy: a rare presentation. *Congenit Anom (Kyoto)* 2008;48(3):142-143
- 23 Park TC, Lee HJ. Pregnancy coexisting with uterus didelphys with a blind hemivagina complicated by pyocolpos due to *Pedococcus* infection: a case report and review of the published reports. *J Obstet Gynaecol Res* 2013;39(7):1276-1279
- 24 Karpathios SE, Phylactou M, Drakakis PE. Uterus didelphys and pregnancy: an unusual case in an 18-year-old patient. *Gynecol Obstet Invest* 1992;33(1):51-53
- 25 Trifonov I, Uzunova J. [Successful full-term pregnancy in the Herlyn-Werner-Wunderlich syndrome: a case report and review of literature]. *Akush Ginekol (Sofia)* 2014;53 (Suppl 2):42-45
- 26 Grimbizis GF, Gordts S, Di Spiezio Sardo A, et al. The ESHRE-ESGE consensus on the classification of female genital tract congenital anomalies. *Gynecol Surg* 2013;10(3):199-212
- 27 Orazi C, Lucchetti MC, Schingo PM, Marchetti P, Ferro F. Herlyn-Werner-Wunderlich syndrome: uterus didelphys, blind hemivagina and ipsilateral renal agenesis. Sonographic and MR findings in 11 cases. *Pediatr Radiol* 2007;37(7):657-665
- 28 Kabiri D, Arzy Y, Hants Y. Herlyn-Werner-Wunderlich syndrome: uterus didelphys and obstructed hemivagina with unilateral renal agenesis. *Isr Med Assoc J* 2013;15(1):66
- 29 Epelman M, Dinan D, Gee MS, Servaes S, Lee EY, Darge K. Müllerian duct and related anomalies in children and adolescents. *Magn Reson Imaging Clin N Am* 2013;21(4):773-789
- 30 Del Vescovo R, Battisti S, Di Paola V, et al. Herlyn-Werner-Wunderlich syndrome: MRI findings, radiological guide (two cases and literature review), and differential diagnosis. *BMC Med Imaging* 2012;12:4
- 31 Güdücü N, Gönenç G, Işçi H, Yiğiter AB, Dündar I. Herlyn-Werner-Wunderlich syndrome-timely diagnosis is important to preserve fertility. *J Pediatr Adolesc Gynecol* 2012;25(5):e111-e112
- 32 Chan YY, Jayaprakasan K, Tan A, Thornton JG, Coomarasamy A, Raine-Fenning NJ. Reproductive outcomes in women with congenital uterine anomalies: a systematic review. *Ultrasound Obstet Gynecol* 2011;38(4):371-382
- 33 Heinonen PK. Uterus didelphys: a report of 26 cases. *Eur J Obstet Gynecol Reprod Biol* 1984;17(5):345-350
- 34 Magudapathi C. Uterus didelphys with longitudinal vaginal septum: normal delivery. *J Clin Case Rep* 2012;2:194
- 35 Suthar S, Choudhary R, Dadhich S. Rupture uterus in pregnancy with didelphys uterus: a rare case report. *J South Asian Fed Obstet Gynecol* 2011;3(3):149-150
- 36 Altwerger G, Pritchard AM, Black JD, Sfakianaki AK. Uterine didelphys and vaginal birth after cesarean delivery. *Obstet Gynecol* 2015;125(1):157-159