

# Traumatic Oculomotor Nerve Avulsion after Mild Head Injury

## *Avulsão traumática do nervo oculomotor após traumatismo craniano leve*

Leonardo Welling<sup>1</sup> Mariana Welling<sup>2</sup> Eduardo Antunes<sup>1</sup> Ariana Jumes<sup>1</sup> Roberto Umeda<sup>3</sup>  
Eberval Gadelha Figueiredo<sup>4</sup>

<sup>1</sup>Department of Neurosurgery, Universidade Estadual de Ponta Grossa, Ponta Grossa – PR, Brazil

<sup>2</sup>Department of Neurology, Universidade Estadual de Ponta Grossa, Ponta Grossa – PR, Brazil

<sup>3</sup>Clinica da Imagem, Ponta Grossa, Brazil

<sup>4</sup>Department of Neurosurgery, Universidade de São Paulo (USP), São Paulo, Brazil

Address for correspondence Leonardo Welling, Universidade Estadual de Ponta Grossa, Ponta Grossa, R. Cel. Bitencourt, 689 - Centro, Cep. 84010-290 PR, Brazil (e-mail: leonardowelling@yahoo.com.br).

Arq Bras Neurocir 2016;35:310–311.

### Abstract

The authors describe a 37-year-old female who suffered a mild head injury after a car accident. She was found with an initial Glasgow coma scale score of 15. On further inspection, complete right ophthalmoplegia was observed. Initial computerized tomography (CT) scan of the head was normal, but magnetic resonance imaging showed right oculomotor nerve avulsion. The patient was discharged from the hospital without any improvement in complete ophthalmoplegia. To our knowledge, this is the first radiographically documented case of oculomotor nerve root avulsion with associated irreversible oculomotor nerve palsy after mild head injury. Considering the poor prognosis for recovery of the nerve function, an appropriate counseling should be provided to the patient and family. Neurosurgical techniques for attempting nerve reconstruction have yet to be investigated but could be a new area for clinical and surgical research.

### Keywords

- ▶ oculomotor nerve
- ▶ head injury
- ▶ avulsion

### Resumo

Os autores descrevem o caso de uma mulher de 37 anos, vítima de acidente automobilístico, com traumatismo craniano leve. No exame inicial, a pontuação da paciente estava em 15, segundo a escala de coma de Glasgow. Na inspeção adicional, observou-se oftalmoplegia completa à direita. A tomografia de crânio da admissão estava normal, porém a ressonância magnética de crânio evidenciou avulsão do nervo oculomotor direito. A paciente recebeu alta sem nenhuma melhora no quadro de oftalmoplegia. Até onde sabemos, esse é o primeiro caso documentado radiograficamente de avulsão da raiz do nervo oculomotor associada a paralisia irreversível do mesmo após traumatismo craniano leve. Considerando o prognóstico de recuperação ruim, aconselhamento apropriado deve ser feito a paciente e familiares. Técnicas para reconstrução desse nervo ainda não foram investigadas, mas podem vir a ser uma nova área de pesquisa clínica e cirúrgica.

### Palavras-chave

- ▶ nervo oculomotor
- ▶ traumatismo craniano
- ▶ avulsão

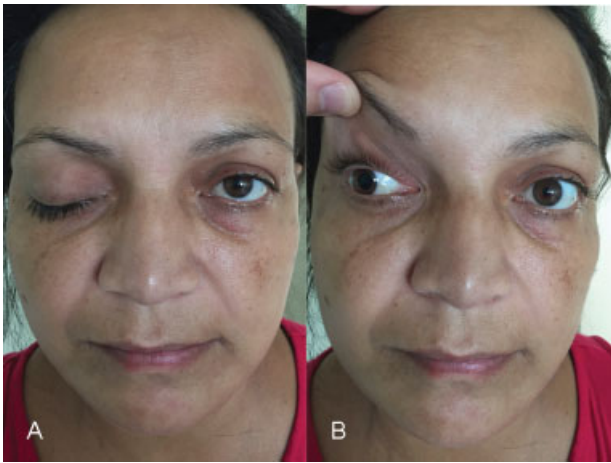received  
September 5, 2016  
accepted  
October 4, 2016  
published online  
November 16, 2016

DOI <http://dx.doi.org/10.1055/s-0036-1593853>.  
ISSN 0103-5355.

Copyright © 2016 by Thieme-Revinter Publicações Ltda, Rio de Janeiro, Brazil

License terms





**Fig. 1** (A) Right eyelid showing complete ptosis. (B) Right eye is deviated outward and downward, the pupil is dilated and non-reactive to light.

## Introduction

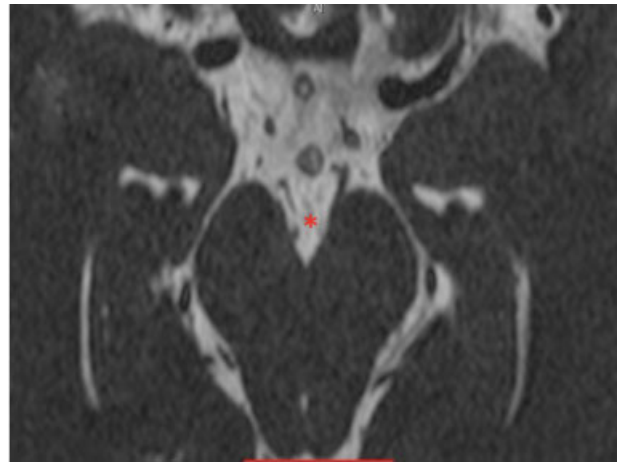
The incidence of primary traumatic oculomotor palsy in craniocerebral trauma is very rare (around 1%), and even rarer in the setting of mild head trauma.<sup>1-3</sup> It is more commonly observed following severe trauma, and it is associated with loss of consciousness and permanent neurologic deficit.<sup>4,5</sup>

## Case Report

A 37-year-old female, who suffered a mild head injury after a car accident, was found with initial Glasgow coma scale score of 15. On further inspection, she had no abrasions of the forehead, no scalp hematoma and no ptosis, but exhibited a fixed, dilated right pupil (► **Fig. 1a, 1b**). An initial computerized tomography (CT) scan of the head was normal. Magnetic resonance imaging performed after 2 days showed right oculomotor nerve avulsion (► **Fig. 2**). Magnetic resonance imaging angiogram was normal. The patient was discharged from our hospital 3 days after the injury, without any improvement in complete ophthalmoplegia.

## Discussion

To our knowledge, this is the first radiographically documented case of oculomotor nerve root avulsion with associ-



**Fig. 2** High-resolution CISS MR image of the mesencephalon showing the right oculomotor nerve is interruption– avulsion of right third nerve (asterisk).

ated irreversible oculomotor nerve palsy after mild head injury. After this radiographic diagnosis, a poor prognosis for nerve function is expected. In this context, appropriate counseling should be provided to the patient and family, allowing them to understand the structural damage, and the unlikely nature of spontaneous improvement of clinical symptoms. Neurosurgical techniques for attempting nerve reconstruction have yet to be investigated but could be a new area for clinical and surgical research.<sup>6</sup>

## References

- Solomons NB, Solomon DJ, de Villiers JC. Direct traumatic third nerve palsy. *S Afr Med J* 1980;58(3):109–111
- Memon MY, Paine KW. Direct injury of the oculomotor nerve in craniocerebral trauma. *J Neurosurg* 1971;35(4):461–464
- Balcer LJ, Galetta SL, Bagley LJ, Pakola SJ. Localization of traumatic oculomotor nerve palsy to the midbrain exit site by magnetic resonance imaging. *Am J Ophthalmol* 1996;122(3):437–439
- Richards BW, Jones FR Jr, Younge BR. Causes and prognosis in 4,278 cases of paralysis of the oculomotor, trochlear, and abducens cranial nerves. *Am J Ophthalmol* 1992;113(5):489–496
- Mariak Z, Mariak Z, Stankiewicz A. Cranial nerve II-VII injuries in fatal closed head trauma. *Eur J Ophthalmol* 1997;7(1):68–72
- Ditta LC, Choudhri AF, Blitz AM, Fleming JC, Kerr NC, O'Donnell T. Traumatic avulsion of the oculomotor nerve documented by high-resolution magnetic resonance imaging. *J AAPOS* 2015;19(4):385–387