

Postoperative Dural Arteriovenous Fistula after Clipping of Ruptured Saccular Aneurysm of Pericallosal Artery

Fístula arteriovenosa dural em pós-operatório de clipagem de aneurisma sacular roto de artéria pericallosa

Zeferino Demartini Jr¹ Matheus Rodrigo Laurenti² Tatiana von Hertwig de Oliveira¹
Gelson Luis Koppe¹ Marcio Luiz Tostes dos Santos² Alexandre N. Francisco¹

¹Department of Neurosurgery, Hospital Universitário Cajuru, Pontifícia Universidade Católica do Paraná – PUCPR, Curitiba, PR, Brazil

²Department of Neurosurgery, Hospital de Base, São José do Rio Preto, SP, Brazil

Address for correspondence Zeferino Demartini Jr., MD, Departamento de Neurocirurgia, Hospital Universitário Cajuru – PUCPR, Avenida São Jose 300–Cristo Rei, Curitiba, PR, Brazil 80.050-350 (e-mail: demartiniz@gmail.com).

Arq Bras Neurocir 2016;35:248–252.

Abstract

Keywords

- ▶ cerebrovascular disorders
- ▶ intracranial arteriovenous malformations
- ▶ arteriovenous fistula
- ▶ intracranial aneurysm
- ▶ postoperative care
- ▶ intracranial hemorrhages

Dural arteriovenous fistulas (DAVFs) are pathologic dural shunts characterized by meningeal arterial supply, absence of nidus and drainage to dural venous sinuses or cortical veins. They are usually acquired lesions associated with specific disease and inflammatory processes, including craniotomy. We report a case of postoperative DAVF in a 59 year-old male presenting with a ruptured distal right anterior cerebral artery aneurysm. After an uneventful microsurgery for clipping, meningitis occurred on the ninth day, and was successfully treated. The one-year control angiogram showed a left occipital DAVF. The relevant literature on the occurrence of DAVFs is also presented.

received
February 5, 2016
accepted
August 1, 2016
published online
September 1, 2016

DOI <http://dx.doi.org/10.1055/s-0036-1592105>.
ISSN 0103-5355.

Copyright © 2016 by Thieme Publicações Ltda, Rio de Janeiro, Brazil

License terms



Resumo

Palavras-chave

- ▶ malformações arteriovenosas intracranianas
- ▶ fístula arteriovenosa
- ▶ transtornos cerebrovasculares
- ▶ aneurisma roto
- ▶ cuidados pós-operatórios
- ▶ hemorragias intracranianas

Fístulas arteriovenosas durais (FAVDs) são comunicações patológicas caracterizadas por suprimento arterial meníngeo, ausência de nidus e drenagem para seios venosos durais ou veias corticais. As fístulas são geralmente adquiridas, secundárias a processos inflamatórios e doenças específicas, podendo ocorrer após craniotomia. Relatamos um caso de FAVD ocorrido em um homem de 59 anos de idade com aneurisma intracraniano roto em artéria cerebral anterior direita distal, submetido a microcirurgia e clipagem, e evoluindo com meningite pós-operatória. O paciente apresentou boa evolução, mas na angiografia de controle um ano após a cirurgia foi identificada FAVD em seio transverso-sigmoide esquerdo. Uma revisão da literatura focada na etiologia também é apresentada.

Introduction

Dural arteriovenous fistulas (DAVFs) are pathologic dural shunts characterized by meningeal arterial supply that drains directly to dural venous sinuses or cortical veins.¹ Dural arteriovenous fistulas represent 10–15% of all arteriovenous malformations,² being distinguished from pial or parenchymal arteriovenous malformations by the absence of nidus.¹ Although DAVFs may be idiopathic,^{1,3} they are predominantly acquired lesions, usually associated with specific disease processes, such as venous sinus thrombosis.^{3,4} Furthermore, the development of DAVFs following intracranial surgery has been reported.^{5–12} We report a case of appearance of a DAVF, absent in the initial examination, after craniotomy for clipping a ruptured distal right anterior cerebral artery aneurysm.

Case Report

A 59-year-old man was admitted to the emergency room with a history of sudden-onset headache followed by seizure. Upon examination he was somnolent, confused, responding to commands, score of 13 on the Glasgow coma scale, with no focal neurological deficit, but presenting with meningism, Hunt-Hess 2, and World Federation of Neurological Surgeons (WFNS) grading scale 2. A head computed tomography (CT) scan showed subarachnoid hemorrhage, Fisher scale of 3 (▶ Fig. 1). The patient was submitted to digital subtraction angiography (DSA), revealing an aneurysm of the right pericallosal artery (▶ Fig. 2A). A frontal craniotomy was performed with microsurgical clipping of the aneurysm, with no trans-procedural rupture or postoperative deficits. The patient woke up from the procedure without any deficit, and the control CT scan excluded infarcts or additional hemorrhage. On the ninth day, he was febrile, and his level of consciousness decreased. Bacterial meningitis was diagnosed by lumbar puncture, and treated with antibiotics for seven days, with satisfactory response. The patient was discharged after seventeen days in the hospital with a

Glasgow outcome score of 5. A control DSA performed one year later confirmed the exclusion of the aneurysm from the circulation (▶ Fig. 2B), but revealed the presence of a DAVF, absent in the initial examination, with feeding from branches of the left external carotid artery and normal antegrade flow to the transverse-sigmoid sinus, classified as Borden I/Cognard I (▶ Fig. 3). The patient remained asymptomatic, with no residual deficits, under outpatient follow-up.

Discussion

In a study of 69 patients with DAVFs, Tsai et al found venous sinus thrombosis in two fifths of them.³ Dural arteriovenous

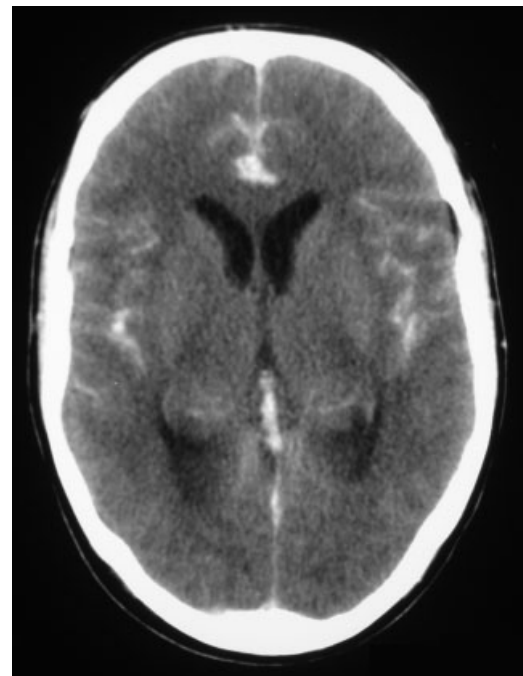


Fig. 1 A cranial CT shows a diffuse subarachnoid hemorrhage, with a small clot in the interhemispheric fissure.

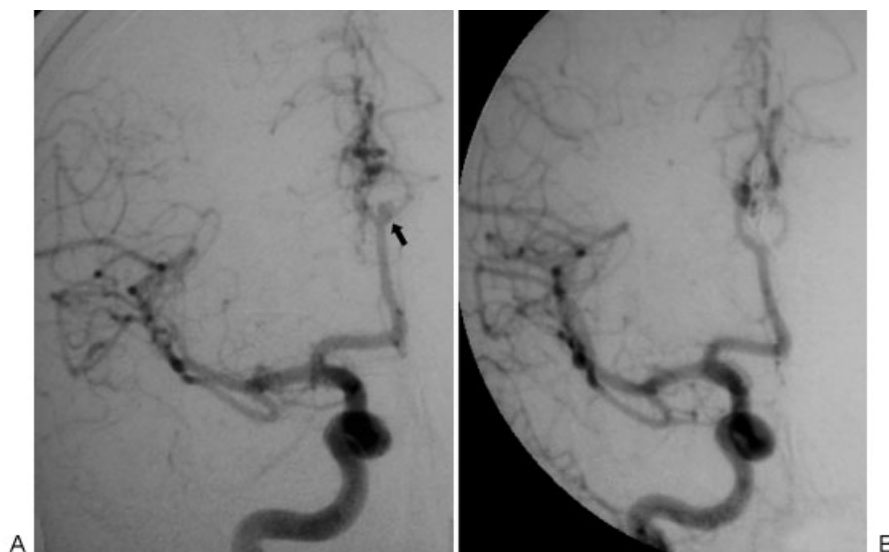


Fig. 2 A cerebral angiogram in anteroposterior view shows a right pericallosal artery aneurysm (arrow) (A) with satisfactory clipping (B).

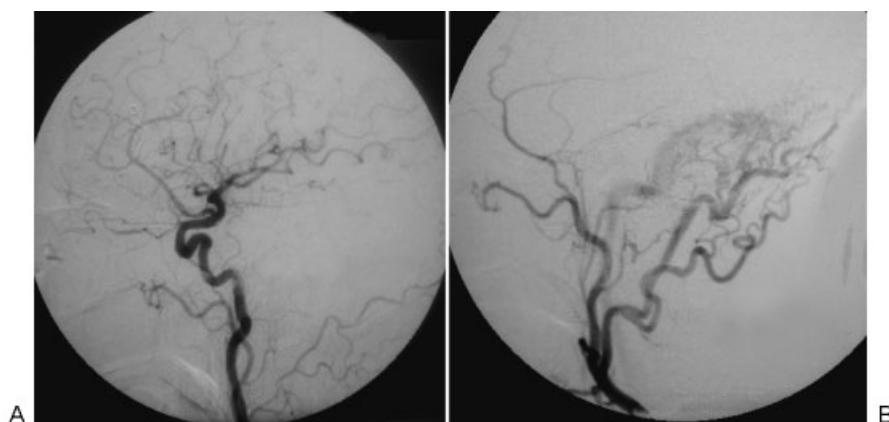


Fig. 3 A cerebral angiogram in lateral view shows a normal left external carotid artery (A), with a one-year postoperative angiogram revealing a dural arteriovenous fistula to the left transverse sinus, with feeding from the external carotid artery (B).

fistulas were also associated with thrombophilic abnormalities,¹²⁻¹⁷ and when correlated to sinus thrombosis, the etiopathogenesis includes two main theories: 1) venous hypertension causes the opening and enlargement of pre-existing embryonic arteriovenous communications in the normal dura mater, resulting in pathologic shunts; and 2) outflow obstruction elevates venous pressure and decreases cerebral perfusion, leading to ischemia and induced angiogenesis.¹ Even in patients without venous sinus occlusion, there are increased D-dimer levels that decrease after resolution of the fistula, indicating the presence of a thrombophilic state.¹⁸ In some cases, DAVFs may occur secondary to other abnormalities as well, such as after the endovascular treatment of carotid-cavernous fistulas,^{19,20} neoplastic venous sinus thrombosis,²¹ or increased venous pressure associated with meningioma growth.²² Inflammatory diseases affecting the dura, such as idiopathic hypertrophic pachymeningitis, viral and bacterial meningitis, were described to cause DAVFs to the straight, cavernous and superior sagittal sinuses respectively.²³⁻²⁵ Blunt²⁶⁻³¹ or penetrating³² traumatic brain injury

may also be causative factors. There are reports of fistulas appearing after craniotomy for surgical resection of arteriovenous malformations,¹⁰ brain stem cavernoma,⁸ and pilocytic astrocytoma.¹² Horie et al³³ reported the association of a DAVF with intracranial aneurysm in a 66 year-old male who presented with a ruptured middle cerebral aneurysm. Rarely, it occurs following intracranial procedures, like endoscopic third ventriculostomy⁹ or evacuation of subdural chronic hematoma.⁵ Since any stimuli may be the initial key to the inflammatory response causing angiogenesis,²³ it is not clear in this case if the trigger for the development of the DAVF was the craniotomy, the meningitis or even an asymptomatic transient sinus thrombosis with spontaneous recanalization. As DAVFs following meningitis are not frequently reported in the literature, this may suggest that in this case the craniotomy could be the leading event to the development of the fistula.

Most DAVFs present in the fifth and sixth decades of life, and are located in the transverse, sigmoid and cavernous sinuses.¹ As symptoms are related to lesion location and

Table 1 Cognard classification of dural arteriovenous fistulas

Type	Venous Drainage	Flow Pattern in Sinus	Cortical Venous Drainage	Behavior
I	Dural sinus	Antegrade	No	Benign
IIa	Dural sinus	Retrograde	No	Benign
IIb	Dural sinus	Antegrade	Yes	Aggressive
IIa + b	Dural sinus	Retrograde	Yes	Aggressive
III	Cortical vein		Yes	Aggressive
IV	Cortical vein		Yes + venous ectasia	Aggressive
V	Cortical vein with spinal perimedullary drainage		Yes	Aggressive

venous drainage pattern, pulsatile tinnitus is common, resulting from increased blood flow through the sigmoid sinus.^{1,34} High-grade DAVFs may present with seizures, cranial nerves abnormalities and intracranial hemorrhage,¹ while cavernous sinus fistulas can cause proptosis, chemosis, ophthalmoplegia and orbital pain.^{1,35}

Imaging plays an important role in diagnosing DAVFs, but it can be delayed or missed due to varying nonspecific clinical and imaging features. Non-enhanced CT only rules out intracranial hemorrhage or edema from chronic venous congestion, while CT angiography provides high-resolution detail of vascular anatomy and bone relationships.¹ Magnetic resonance (MR) may show signs of venous hypertension, dilated cortical veins, thickened dural leaflet and thrombosed or stenosed dural venous sinuses. Although MR angiography can be better than CT angiography to detect DAVFs, DSA remains the gold standard method for detection.¹ Moreover, DSA allows for the classification of DAVFs, helping therapeutic decision through the demonstration of cortical venous reflux, vein engorgement and retrograde flow.¹

The two most used DAVF classification systems were published by Borden et al³⁶ and Cognard et al³⁴ (→ **Table 1**). Both scales are based on drainage pattern and presence of cortical venous reflux, determining the risks and severity of symptoms;^{34,36} however, the Cognard classification has a greater ability to predict the patient's prognosis.¹

Low-grade asymptomatic Borden type I, as well as Cognard I and IIa do not need to be treated, due to low risk of intracranial hemorrhage.^{34,36} In contrast, DAVFs presenting with cortical venous drainage (Borden II-III, Cognard IIb-V) have a worse natural history, with increased risk of bleeding associated with an annual mortality rate of 10.4%.³⁴⁻³⁶ Therefore, high-grade DAVFs require prompt intervention aiming to complete obliteration, due to the high risk of death or severe neurological dysfunction.²⁴ Currently, due to the efficacy of endovascular therapy, this modality has become a first-line treatment of DAVFs, with surgery usually being indicated when endovascular approaches are not feasible or have failed.¹

Postoperative DSA in patients with aneurysms is safe and can be routinely performed.³⁷ Although the long-term efficacy of aneurysm clipping is considerably high, the risk of de novo aneurysm formation supports the rationale for late angiographic follow-up review, particularly in

patients with multiple aneurysms.³⁸ The diagnosis of DAVFs following intracranial procedures is of great importance, since these lesions may behave aggressively.³⁹ Therefore, once these lesions have a dynamic nature, as in this case, close monitoring is recommended to detect threatening lesions.¹

Disclosure

The authors report no conflicts of interest concerning the materials or methods used in this study or the findings specified in this paper.

Sources of Support

They were not used.

References

- Gandhi D, Chen J, Pearl M, Huang J, Gemmete JJ, Kathuria S. Intracranial dural arteriovenous fistulas: classification, imaging findings, and treatment. *AJNR Am J Neuroradiol* 2012;33(6): 1007-1013
- Newton TH, Cronqvist S. Involvement of dural arteries in intracranial arteriovenous malformations. *Radiology* 1969;93(5): 1071-1078
- Tsai LK, Jeng JS, Liu HM, Wang HJ, Yip PK. Intracranial dural arteriovenous fistulas with or without cerebral sinus thrombosis: analysis of 69 patients. *J Neurol Neurosurg Psychiatry* 2004 75(11):1639-1641
- Nishio A, Ohata K, Tsuchida K, et al. Dural arteriovenous fistula involving the superior sagittal sinus following sinus thrombosis—case report. *Neurol Med Chir (Tokyo)* 2002;42(5):217-220
- Pappas CT, Zabramski JM, Shetter AG. Iatrogenic 3 arteriovenous fistula presenting as a recurrent subdural hematoma. Case report. *J Neurosurg* 1992;76(1):134-136
- Murakami K, Matsumoto K, Numagami Y, Tomita T, Nishijima M. [A case of secondary anterior fossa dural arteriovenous fistula following posterior fossa craniotomy]. *No Shinkei Geka. Neurological Surg* 2005;33(11):1101-1105
- Nabors MW, Azzam CJ, Albanna FJ, Gulya AJ, Davis DO, Kobrine AI. Delayed postoperative dural arteriovenous malformations. Report of two cases. *J Neurosurg* 1987;66(5):768-772
- Dudeck O, van Velthoven V, Schumacher M, Klisch J. Development of a complex dural arteriovenous fistula next to a cerebellar developmental venous anomaly after resection of a brainstem

- cavernoma. Case report and review of the literature. *J Neurosurg* 2004;100(2):335–339
- 9 Field M, Branstetter BF IV, Levy E, Yonas H, Jungreis CA. Dural arteriovenous fistula after ventriculostomy. Case illustration. *J Neurosurg* 2002;97(1):227
 - 10 Ahn JY, Kim OJ, Joo YJ, Joo JY. Dural arteriovenous malformation occurring after craniotomy for pial arteriovenous malformation. *J Clin Neurosci* 2003;10(1):134–136
 - 11 Watanabe A, Takahara Y, Ibuchi Y, Mizukami K. Two cases of dural arteriovenous malformation occurring after intracranial surgery. *Neuroradiology* 1984;26(5):375–380
 - 12 Yassari R, Jahromi B, Macdonald R. Dural arteriovenous fistula after craniotomy for pilocytic astrocytoma in a patient with protein S deficiency. *Surg Neurol* 2002;58(1):59–64, discussion 64
 - 13 Wenderoth JD, Phatouros CC. Incidental discovery of a dural arteriovenous fistula in a patient with activated protein C resistance. *AJNR Am J Neuroradiol* 2003;24(7):1369–1371
 - 14 Witt O, Pereira PL, Tillmann W. Severe cerebral venous sinus thrombosis and dural arteriovenous fistula in an infant with protein S deficiency. *Childs Nerv Syst* 1999;15(2-3):128–130
 - 15 Gerlach R, Yahya H, Rohde S, et al. Increased incidence of thrombophilic abnormalities in patients with cranial dural arteriovenous fistulae. *Neurol Res* 2003;25(7):745–748
 - 16 Kraus JA, Stüper BK, Nahser HC, Klockgether T, Berlit P. Significantly increased prevalence of factor V Leiden in patients with dural arteriovenous fistulas. *J Neurol* 2000;247(7):521–523
 - 17 Singh V, Meyers PM, Halbach VH, et al. Dural arteriovenous fistula associated with prothrombin gene mutation. *J Neuroimaging* 2001;11(3):319–321
 - 18 Izumi T, Miyachi S, Hattori K, Iizuka H, Nakane Y, Yoshida J. Thrombophilic abnormalities among patients with cranial dural arteriovenous fistulas. *Neurosurgery* 2007;61(2):262–268, discussion 268–269
 - 19 Gupta R, Horowitz M, Tayal A, Jovin T. De novo development of a remote arteriovenous fistula following transarterial embolization of a carotid cavernous fistula: case report and review of the literature. *AJNR Am J Neuroradiol* 2005;26(10):2587–2590
 - 20 Terada T, Miyatake N, Naka D, et al. Indirect carotid cavernous fistula appeared after balloon embolization of direct CCF. *Acta Neurochir (Wien)* 2002;144(5):489–492
 - 21 Vilela P, Willinsky R, terBrugge K. Dural arteriovenous fistula associated with neoplastic dural sinus thrombosis: two cases. *Neuroradiology* 2001;43(10):816–820
 - 22 Inoue T, Nishimura S, Hayashi N, Numagami Y, Tomita T, Nishijima M. Cavernous sinus dural arteriovenous fistula associated with the development of sphenoidal ridge meningioma—case report. *Neurol Med Chir (Tokyo)* 2007;47(7):317–321
 - 23 Tsutsumi S, Yasumoto Y, Ito M, Oishi H, Arai H, Yoritaka A. Atypical dural arteriovenous fistula associated with meningitis. *Neurol Med Chir (Tokyo)* 2008;48(2):68–71
 - 24 Hai J, Zhang L, Wan JF, Su SH, Wang F, Zhang GY. A dural arteriovenous fistula in cavernous sinus developed from viral meningitis. *Acta Neurol Belg* 2011;111(2):146–148
 - 25 Hamada J, Yoshinaga Y, Korogi Y, Ushio Y. Idiopathic hypertrophic cranial pachymeningitis associated with a dural arteriovenous fistula involving the straight sinus: case report. *Neurosurgery* 2000;47(5):1230–1233
 - 26 Dennery JM, Ignacio BS. Post-traumatic arteriovenous fistula between the external carotid arteries and the superior longitudinal sinus: report of a case. *Can J Surg* 1967;10(3):333–336
 - 27 Friedman JA, Meyer FB, Nichols DA, et al. Fatal progression of posttraumatic dural arteriovenous fistulas refractory to multimodal therapy. Case report. *J Neurosurg* 2001;94(5):831–835
 - 28 Ishiguro S, Kimura A, Munemoto S, Kitabayashi M, Shoin K, Futami K. [Traumatic arteriovenous fistula with feeders of the scalp, dura mater and pia mater: case report]. *No Shinkei Geka. Neurological Surg* 1987;15(6):677–681
 - 29 Kinjo T, Mukawa J, Miyagi K, Kinjo N, Terada Y. [A case of successfully removed posttraumatic high flow dural arteriovenous fistula in the posterior fossa]. *No Shinkei Geka. Neurological Surg* 1991;19(6):577–581
 - 30 Tsutsumi M, Kazekawa K, Tanaka A, et al. Traumatic middle meningeal artery pseudoaneurysm and subsequent fistula formation with the cavernous sinus: case report. *Surg Neurol* 2002;58(5):325–328
 - 31 Zink WE, Meyers PM, Connolly ES, Lavine SD. Combined surgical and endovascular management of a complex posttraumatic dural arteriovenous fistula of the tentorium and straight sinus. *J Neuroimaging* 2004;14(3):273–276
 - 32 Zhu G, Chen Z, Feng H. Dural arteriovenous fistulae after forehead knife-cut injury. *Chin J Traumatol* 2004;7(4):253–256
 - 33 Horie M, Yamashita K, Yoshida T, et al. [A case of ruptured aneurysm of the middle cerebral artery associated with dural arteriovenous fistula in the anterior cranial fossa]. *No Shinkei Geka. Neurological Surg* 2003;31(10):1099–1103
 - 34 Cognard C, Gobin YP, Pierot L, et al. Cerebral dural arteriovenous fistulas: clinical and angiographic correlation with a revised classification of venous drainage. *Radiology* 1995;194(3):671–680
 - 35 van Dijk JM, terBrugge KG, Willinsky RA, Wallace MC. Clinical course of cranial dural arteriovenous fistulas with long-term persistent cortical venous reflux. *Stroke* 2002;33(5):1233–1236
 - 36 Borden JA, Wu JK, Shucart WA. A proposed classification for spinal and cranial dural arteriovenous fistulous malformations and implications for treatment. *J Neurosurg* 1995;82(2):166–179
 - 37 Le Roux PD, Elliott JP, Eskridge JM, Cohen W, Winn HR. Risks and benefits of diagnostic angiography after aneurysm surgery: a retrospective analysis of 597 studies. *Neurosurgery* 1998;42(6):1248–1254, discussion 1254–1255
 - 38 David CA, Vishteh AG, Spetzler RF, Lemole M, Lawton MT, Partovi S. Late angiographic follow-up review of surgically treated aneurysms. *J Neurosurg* 1999;91(3):396–401
 - 39 Kuwayama N, Kubo M, Tsumura K, Yamamoto H, Endo S. Hemodynamic status and treatment of aggressive dural arteriovenous fistulas. *Acta Neurochir Suppl (Wien)* 2005;94:123–126