

Safety and Efficacy of Endoluminal Vasodilators on the Prevention of Vasospasm in Deep Inferior Epigastric Perforator Flap Breast Reconstruction: A Prospective Controlled Study

Barbara Hersant, MD^{1,2} Romain Bosc, MD^{1,2} Mounia SidAhmed-Mezi, PhD, MD¹
Mathieu Kerneis, MD³ Jean-Paul Meningaud, MD, PhD¹

¹Department of Plastic and Reconstructive Surgery, Henri Mondor Hospital, Créteil, France

²Henri Mondor Breast Center, Créteil, France

³Department of Cardiology, INSERM UMRS1166, Pitié-Salpêtrière Hospital, Université Paris 6, Paris, France

Address for correspondence Barbara Hersant, MD, Department of Plastic and Reconstructive Surgery, Henri Mondor Hospital, 51 avenue du Maréchal de Lattre de Tassigny, Créteil 94010, France (e-mail: Barbara.hersant@gmail.com).

J Reconstr Microsurg Open 2016;1:96–99.

Abstract

Background The spasm of the internal mammary artery (IMA) and inferior epigastric pedicle (IEP) is critical in deep inferior epigastric perforator (DIEP) flap breast reconstruction. The aim of this study was to assess the safety and the efficacy of endoluminal vasodilators on the prevention of vasospasm in DIEP flap breast reconstruction.

Methods Fifty-eight patients were included in a controlled study. Of the 58 patients, 29 patients were prospectively included and received a combination of 1 mg of isosorbide dinitrate and 0.25 mg of nicardipine injected into the IMA and IEP (intervention group) and 29 patients were retrospectively included and received no antispasmodic agents (control group). The efficacy outcome was the flap viability. The safety outcome was the mean central blood pressure.

Results The rate of flap necrosis was lower in the intervention group than in the control group (0 vs. 10.34%; $p = 0.2$). The mean blood pressure was not significantly different between the two groups after injection ($p = 0.403$).

Conclusion Injecting nicardipine and isosorbide dinitrate into the IMA and IEP could be used as a new strategy to prevent vasospasm in DIEP flap breast reconstruction.

Keywords

- ▶ vasodilators
- ▶ DIEP flap
- ▶ breast reconstruction

The anastomosis of the inferior epigastric pedicle (IEP) with the internal mammary vessels is commonly performed in deep inferior epigastric perforator (DIEP) flap breast reconstruction.¹ However, the dissection of internal mammary vessels may cause a spasm of the artery.^{2,3} The vasospasm of the internal mammary artery (IMA) or IEP decreases the blood flow, exposing patients to vascular thrombosis and procedure failure. This risk is increased in patients treated with radiotherapy,^{4,5} patients with atherosclerosis, and in the elderly. In daily practice, thoracic and cardiac surgeons

commonly use an intra-arterial combination of vasodilators injected into the IMA before performing anastomosis.^{6–8} In plastic surgery, vasodilators are commonly used in topical application for free flap surgery,^{9,10} while the endoluminal injection is rarely used.⁹

We have previously reported that combining isosorbide dinitrate and nicardipine could be helpful in practice to treat IMA vasospasm during DIEP flap breast reconstruction.¹¹ Indeed, nicardipine IV, which is a dihydropyridine derivative, is a calcium blocker indicated for the short-term treatment of

received
March 15, 2016
accepted after revision
June 22, 2016
published online
August 8, 2016

DOI <http://dx.doi.org/10.1055/s-0036-1587337>.
ISSN 2377-0813.

Copyright © 2016 by Thieme Medical Publishers, Inc., 333 Seventh Avenue, New York, NY 10001, USA.
Tel: +1(212) 584-4662.

License terms



hypertension. Its use results in artery vasodilation and prevents vasospasm in cardiology or neurology. Isosorbide dinitrate is a nitric oxide donor, resulting in vein and artery vasodilation used to reduce blood pressure and vascular spasms.

The aim of this study was to assess the safety and the efficacy of a combination of endoluminal vasodilators, isosorbide dinitrate and nicardipine, on the prevention of IMA and IEP vasospasm during anastomosis.

Patients and Methods

Patients

Twenty-nine consecutive patients undergoing DIEP flap breast reconstruction were prospectively included in a clinical registry between January 2013 and November 2013. They formed the intervention group. Inclusion criteria were age >18 years and need for unilateral or bilateral mastectomy for breast cancer. The decision of performing a DIEP flap breast reconstruction was made by a "breast team" including reconstructive and breast cancer surgeons. Exclusion criteria were having any contraindication to calcium blockers (heart failure, bradycardia). All patients received an injection of 1 mg (or 1 mL) of isosorbide dinitrate and 0.25 mg (or 0.25 mL) of nicardipine in 5 mL of 9% sodium chloride directly into the IMA and IEP before performing anastomosis. The procedure used was similar to that performed by thoracic and cardiac surgeons.

The intervention group was compared with a historical control group that was included retrospectively. Twenty-nine consecutive patients who underwent DIEP flap breast reconstruction performed by the same surgeon between January 2012 and December 2012 and received no antispasmodic agents were included in the control group.

All patients provided their informed consent and the conduct of the study was approved by the ethics committee of our institution.

Intervention

The same surgeon performed all the DIEP flap breast reconstructions. No change was made to our standard surgical procedure. Briefly, after excision of the mastectomy scar, the fourth chondrocostal segment was sectioned and resected and the fourth chondrocostal rib was removed. The thoracic vessels were visualized and carefully dissected. Then, the transfer of free flap was performed. The IMA was sectioned and the artery blood flow was evaluated before performing anastomosis.

In the intervention group, a pediatric catheter was used to carefully inject the combination of vasodilators directly into the IMA and IEP without damaging the vessel intima. Then, the anastomosis was performed. The central blood pressure was measured using a radial artery catheterization before and after (5 minute) injecting vasodilators. When needed, the anesthetist administered intravenous normal saline to avoid vascular collapse.

Patients were monitored for 24 hours in our surgical intensive care unit after the procedure. The flap viability

was monitored clinically and by Doppler during the procedure and then daily for 1 week. A clinical follow-up visit took place 1 month postsurgery.

Outcomes

Clinical characteristics and outcomes were reported for all patients and compared between both groups.

The primary endpoint was the efficacy, which was defined by the rate of flap failure. The flap failure was the necrosis of the flap in the month after the surgery that led the surgical team to perform another reconstruction. The follow-up time was 1 month.

The secondary endpoint was the safety, which was defined by the change in mean blood pressure before and after the injection of vasodilators and by the change in systolic blood pressure (SBP) and diastolic blood pressure (DBP) before injection and 5 minutes after injection.

Statistical Analysis

Continuous variables following a normal distribution are presented as means \pm standard deviation and were compared using Student's *t*-test. Categorical variables are presented as counts and percentages and were compared using Fisher's exact test. Results are reported as means \pm standard error of the mean for the detailed analyses. All *p*-values were two-sided and a value of *p* < 0.05 was considered significant. The normal distribution of the continuous variables was assessed using the Kolmogorov-Smirnov test. All analyses were performed using PRISM (version 5, Graph Pad, La Jolla, CA). All the authors had full access to all of the data and take full responsibility for the integrity of the data and the accuracy of the data analysis.

Results

Patient Characteristics

Patient characteristics are described in ►Table 1. No significant difference in clinical characteristics was found between the intervention group and the control group (►Table 1).

Efficacy Outcomes

In the control group, two total and one partial flap necroses were observed (rate: $10.34\% \pm 5.7\%$). In the intervention group, no total or partial flap necrosis was noted. The rate of flap necrosis was, therefore, lower in the intervention group but without reaching significance (*p* = 0.2).

Safety Outcomes

The mean blood pressure was calculated for the intervention group using the following formula: $(SBP + 2 \times DBP)/3$. It was similar before and after injection of vasodilators: 79.89 ± 2.24 mm Hg versus 79.02 ± 2.30 mm Hg; *p* = 0.403 (Fig. 1).

The mean SBP was 110.3 ± 15.00 mm Hg before injection and 107.1 ± 15.67 mm Hg after injection (*p* = 0.0369), while the mean DBP was 64.66 ± 12.10 mm Hg before injection and 65.00 ± 12.68 after injection (*p* = 0.712). The change in SBP was -3.28 ± 7.59 mm Hg and the change in DBP was

Table 1 Patient characteristics

Clinical characteristics	Treated group	Control group	P-Value
Number of patients (N)	29	29	
Age (y)	52.14 ± 1.77	48.24 ± 7.16	0.6
BMI (kg/m ²)	27.37 ± 0.7	28.33 ± 2.22	0.7
Radiotherapy before surgery (%)	62.07 ± 9.17	68.96 ± 42.8	0.8
Smoking (%)	27.59 ± 8.45	13.79 ± 23.78	0.5
Diabetes (%)	6.89 ± 4.79	6.89 ± 4.79	1
HTA (%)	13.79 ± 6.52	3.45 ± 6.65	0.2
Hypercholesterolemia (%)	6.89 ± 4.79	10.34 ± 18.59	0.8

Abbreviations: BMI, body mass index; HTA, arterial hypertension.

0.345 ± 4.99 mm Hg. Only two patients (6.9%) had a SBP less than 90 mm Hg.

Discussion

In this study, we found that the use of endoluminal vasodilators had no impact on the mean blood pressure and subsequently no negative impact on free flap breast reconstruction. Our findings showed that the endoluminal injection of isosorbide dinitrate and nicardipine could be used to improve anastomosis performance without adverse events.

To our knowledge, the dissection of vessels leads to the spasm of the IMA in 5 to 10% of cases.^{9,12} This complication is increased by radiotherapy for the treatment of breast cancer. In our practice, it appears easier to remove the fourth

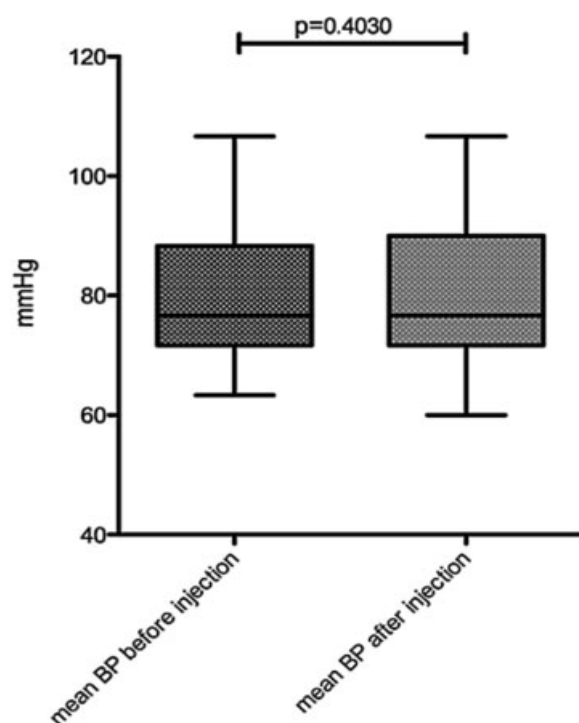
chondrocostal rib than the third one despite the risk of sectioning smaller IMA vessels. We believe that removing the fourth chondrocostal rib reduces both morbidity and postoperative thoracic pain. Cardiologists use intra-arterial vasodilators to prevent the risk of radial artery spasm during coronary angiography. The visceral arteries tend to spasm less easily than the peripheral arteries. There is no consensus on which drugs should be used in this context. Furthermore, thoracic and cardiac surgeons also use intra-arterial vasodilators before performing IMA anastomosis.^{2,10} For example, amlodipine leads to IMA relaxation during coronary revascularization surgery.²

In free flap surgery, plastic surgeons usually administer topical vasodilators into the vessel but rarely endoluminal agents. In microsurgery, papaverine or lidocaine is often injected in the adventitia of the vessel.¹² The experience of United Kingdom based plastic surgeons with the use of vasodilators in microsurgery has been studied using a questionnaire by Yu et al.⁹ He has found that 94% of surgeons used vasodilators during microsurgery and half used them empirically. Furthermore, 99% of plastic surgeons used topical vasodilators and only 19% used endoluminal agents. Finally, papaverine, calcium channel blockers, and local anesthetics were the three most commonly prescribed vasodilators.

However, several studies have shown that the blood flow increases in the IMA after 15 minutes when no vasodilators are used.¹³ The use of topical vasodilators is more common than the intravenous injection because of the risk of central blood pressure drop.^{9,14}

This study has some limitations including biases inherent to the use of a registry. First, patients were not randomized. Second, due to the small number of events and the small size of our sample, our clinical conclusions on the improvement associated with the systematic use of vasodilators are limited. Third, the control group was used to compare our present results to our previous practice.

This study should be considered as an exploratory study, and the efficacy results should be interpreted with caution. However, this was the first report of a real-life cohort undergoing DIEP flap breast reconstruction using such a strategy and it confirmed its safety and feasibility. Moreover, in many plastic surgery departments, the actual failure rate of

**Fig. 1** Central blood pressure before and after injection.

DIEP flap breast reconstruction is less than 1% and is most often related to venous compromised DIEP flap.¹⁵ In our department, we routinely perform a double venous anastomosis on the antegrade and retrograde internal mammary veins. In this series, we observed no venous congestion of the flap.

Conclusion

This first report of the systematic injection of nicardipine and isosorbide dinitrate into the IMA and IEP to prevent vasospasm supports the reproducibility and safety of this strategy in DIEP flap breast reconstruction. However, a dedicated randomized control trial should be conducted to confirm these promising results.

Acknowledgments

The authors would like to thank the Henri Mondor Breast Center and the Cardiology Institute of La Pitié Salpêtrière Hospital for their help in the conduct of this study.

References

- Dupin CL, Allen RJ, Glass CA, Bunch R. The internal mammary artery and vein as a recipient site for free-flap breast reconstruction: a report of 110 consecutive cases. *Plast Reconstr Surg* 1996; 98(4):685–689, discussion 690–692
- Bai XY, Liu XC, Jing WB, Yang Q, Tang XD, He GW. Effect of amlodipine in human internal mammary artery and clinical implications. *Ann Thorac Surg* 2010;90(6):1952–1957
- Kiss L, Benko R, Kovács E, et al. Human internal thoracic artery grafts exhibit severe morphological and functional damage and spasmic vasomotion due to oxidative stress. *Med Sci Monit* 2011; 17(7):CR411–CR416
- Blondeel PN. One hundred free DIEP flap breast reconstructions: a personal experience. *Br J Plast Surg* 1999;52(2):104–111
- Leclère FM, Mordon S, Ramboaniaina S, Schoofs M. Breast reconstruction with a free DIEP flap complicated by spontaneous rupture of internal mammary artery [in French]. *Ann Chir Plast Esthet* 2010;55(6):593–596
- Cooper GJ, Wilkinson GAL, Angelini GD. Overcoming perioperative spasm of the internal mammary artery: which is the best vasodilator? *J Thorac Cardiovasc Surg* 1992;104(2):465–468
- Dharma S, Shah S, Radadiya R, Vyas C, Pancholy S, Patel T. Nitroglycerin plus diltiazem versus nitroglycerin alone for spasm prophylaxis with transradial approach. *J Invasive Cardiol* 2012; 24(3):122–125
- Kristić I, Lukenda J. Radial artery spasm during transradial coronary procedures. *J Invasive Cardiol* 2011;23(12):527–531
- Yu JT, Patel AJ, Malata CM. The use of topical vasodilators in microvascular surgery. *J Plast Reconstr Aesthet Surg* 2011;64(2): 226–228
- Saçak B, Sirinoğlu H. A new and useful method to prevent spasm of microvascular anastomosis in the postoperative period. *Microsurgery* 2012;32(6):505
- Hersant B, Bosc R, Lange F, Chader H, Bouhassira J, Meningaud JP. New association of nicardipine and isosorbide dinitrate to treat internal mammary artery vasospasm in DIEP breast reconstruction. *J Plast Reconstr Aesthet Surg* 2013;66(12):1807–1808
- Formica F, Ferro O, Brustia M, et al. Effects of papaverine and glycerylnitrate-verapamil solution as topical and intraluminal vasodilators for internal thoracic artery. *Ann Thorac Surg* 2006; 81(1):120–124
- Sivalingam S, Levine A, Dunning J. What is the optimal vasodilator for preventing spasm in the left internal mammary artery during coronary arterial bypass grafting? *Interact Cardiovasc Thorac Surg* 2005;4(4):365–371
- Komorowska-Timek E, Chen SG, Zhang F, Dogan T, Lineaweaver WC, Buncke HJ. Prolonged perivascular use of verapamil or lidocaine decreases skin flap necrosis. *Ann Plast Surg* 1999;43(3): 283–288
- Gill PS, Hunt JP, Guerra AB, et al. A 10-year retrospective review of 758 DIEP flaps for breast reconstruction. *Plast Reconstr Surg* 2004; 113(4):1153–1160