

Delayed Presentation of Atlanto-Occipital Dislocation with Fracture of Adjoining Bone with Diagnostic Challenge: Report of Two Cases

Deepak K. Jha¹ Monali Chaturvedi² Mukul Jain³ Arvind Arya³ Suman Kushwaha⁴

¹Department of Neurosurgery, Institute of Human Behavior and Allied Sciences, New Delhi, India

²Department of Neuroradiology, Institute of Human Behavior and Allied Sciences, New Delhi, India

³Department of Neuroanesthesia, Institute of Human Behavior and Allied Sciences, New Delhi, India

⁴Department of Neurology, Institute of Human Behavior and Allied Sciences, New Delhi, India

Address for correspondence Deepak K. Jha, MCh, Department of Neurosurgery, Institute of Human Behavior and Allied Sciences, New Delhi 110095, India (e-mail: jhadeepak2@rediffmail.com).

Indian J Neurotrauma 2016;13:124–127.

Abstract

Keywords

- ▶ atlanto-occipital dislocation
- ▶ cervicomedullary junction
- ▶ transcondylar
- ▶ far-lateral approach
- ▶ traumatic dislocations

Atlanto-occipital dislocation with fracture (AODF) of adjoining bone is rarely reported and poses diagnostic challenge due to complex anatomy and inability of plain radiograph to diagnose it. Authors present two cases of AODF with fracture of adjoining bone with delayed presentations, including one patient with occipitalized C1. Clinical and radiological findings, causes of diagnostic delays, and surgical management are described along with a review of relevant literature.

Introduction

Atlanto-occipital dislocation with fracture (AODF) of adjoining bone is rare, and surgery of this location is challenging due to its complex and occasionally variable anatomy due to various malformations.^{1–9} There are possibilities of array of traumatic dislocations of atlanto-occipital joint (AOJ) leading to deviation of location and course of the vertebral arteries. Delay in diagnosis is common, which makes the treatment more challenging because of malunions, remodeling of the dislocated or fractured segments, and change in the course of vertebral arteries.^{1,2,10–13} In addition to sensorimotor weaknesses and cranial nerve palsies, cervicomedullary junction (CMJ) compression caused by AODF frequently affects respiration, which makes surgery more risky. Here we present two cases of delayed presentations of AODF with respiratory involvements and discuss challenges of their management and relevant literature.

Case Report

Patient 1: A 25-year-old male presented with symptoms of gradually increasing weakness of all four limbs (initially right upper and lower limbs), decrease in muscle mass of all four limbs, burning of lower trunk and both lower limbs, and numbness of inner side of the right upper limb for 2 years before admission. For the last 1 year, the patient was unable to walk and had vertigo on neck movements and breathlessness on minimal exertion. Patient had history of trauma over back of the head by a leather cricket ball approximately 10 to 12 years back following which he had become unconscious for 5 to 10 minutes, and after regaining consciousness, he had developed weakness of all four limbs, which gradually improved over a period of 2 to 3 months; however, he had occasional pain and restricted neck movements after the trauma.

received

June 24, 2016

accepted

July 15, 2016

published online

August 10, 2016

© 2016 Neurotrauma Society of India

DOI <http://dx.doi.org/>

10.1055/s-0036-1586738.

ISSN 0973-0508.

Clinical examination revealed patient's single breath count as 18 per minute. There was wasting of all groups of muscles of all four limbs. Wasting of hand muscles were more pronounced and were more in the right hand. Patient was unable to walk and had restricted neck movements. Cranial nerves were normal. There was 20% decrease in all sensations below C2. Power was grade 3 in all four limbs with spastic quadriplegia. He had bilateral ankle and right knee clonus with bilateral extensor planters. He had hesitancy and was constipated.

He was investigated at another center by plain X-ray, computed tomography (CT) scan, magnetic resonance (MR) imaging, and MR angiography of craniovertebral junction (CVJ), which showed occipitalized C1 along with malunited fracture of right half of anterior arch of C1 with dislocated right AOJ lateral mass and tonsillar herniation up to upper level of C2 lamina causing compression of CMJ (►Fig. 1A–F). Patient was subjected to right transcondylar/far-lateral approach and compressing parts of right C1 lateral mass and anterior arch were removed along with the posterior arch of occipitalized C1 (►Fig. 1G, H). Postoperatively, Philadelphia cervical collar was applied for 3 months and patient improved neurologically over a period of 6 months.

Patient 2: A 20-year-old male patient presented with neck pain, restricted neck movement, weakness and difficulty in raising both upper limbs for the past 5 years, and weakness of

both lower limbs, with difficulty in walking for last 1 year. Patient had a history of fall 5 years ago while carrying load over his head during which the load had fallen over him causing severe pain in the neck, transient vertigo followed by restricted neck movement, and inability to raise his upper limbs. Clinical examination revealed restricted neck movement and torticollis to the left side. Single breath count was 26 per minute. He had left ninth cranial nerve palsy and 25% decrease in all sensations below C4. Patient was able to walk with support and had spastic quadriplegia. Power in right and left upper limbs were grades 3 and 5, respectively, and grade 4 in both the lower limbs. There was no involvement of bladder and bowel functions and he had easy fatigability. MR imaging, CT scan, and CT angiography of CVJ done at another center revealed malunited left occipital condyle (OC) fracture with inward tilt toward foramen magnum and medial and upward dislocation of left lateral mass of atlas causing CVJ compression (►Fig. 2A–D). Patient was subjected to left transcondylar/far-lateral approach, and CMJ was decompressed by the removal of compressing part of OC (posterior part). Remaining OC-C1 lateral mass distraction was done by titanium cage filled up with autologous bone graft (►Fig. 1E, F). Postoperatively, Philadelphia cervical collar was applied for 3 months and patient improved neurologically completely over a period of 6 months. Both

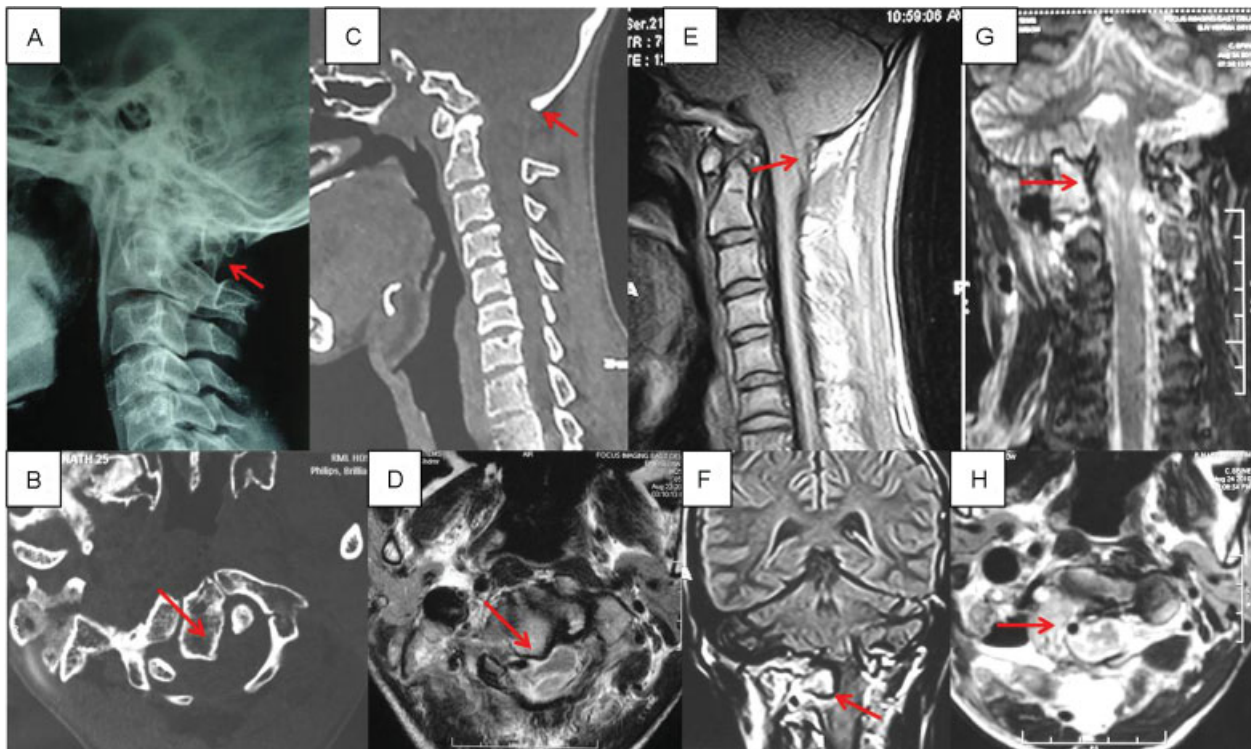


Fig. 1 Preoperative. (A) Plain radiograph of the cervical spine in lateral view shows a small bony fragment projecting between occipitalized posterior arch of C1 and C2 vertebra (arrow). (B) Axial computed tomography (CT) image of CVJ shows fracture of anterior arch of C1 vertebra along right lateral aspect with posteromedial dislocation and rotational abnormality of fractured fragment (arrow). (C) Sagittal reconstructed CT image of CVJ on bone window setting shows occipitalization of posterior arch of C1 (arrow). (D) Axial T2-weighted magnetic resonance (MR) image of CVJ at C1 level shows the fractured bony fragment (arrow) compressing the thecal sac along the right anterolateral aspect causing rotational compression and left lateral deviation of cervicomedullary junction (CMJ). (E) Midline sagittal T1-weighted MR image of CVJ shows tonsillar herniation (arrow) below foramen magnum with compression of CMJ. (F) Coronal T1-weighted MR image at the level of C1 lateral mass reveals medial displacement of right C1 lateral mass (arrow) compressing the CMJ. (G) Postoperative coronal and (H) axial T2-weighted MR images of CVJ showing surgical removal of right lateral mass of C1 (arrow) with decompressed CMJ.

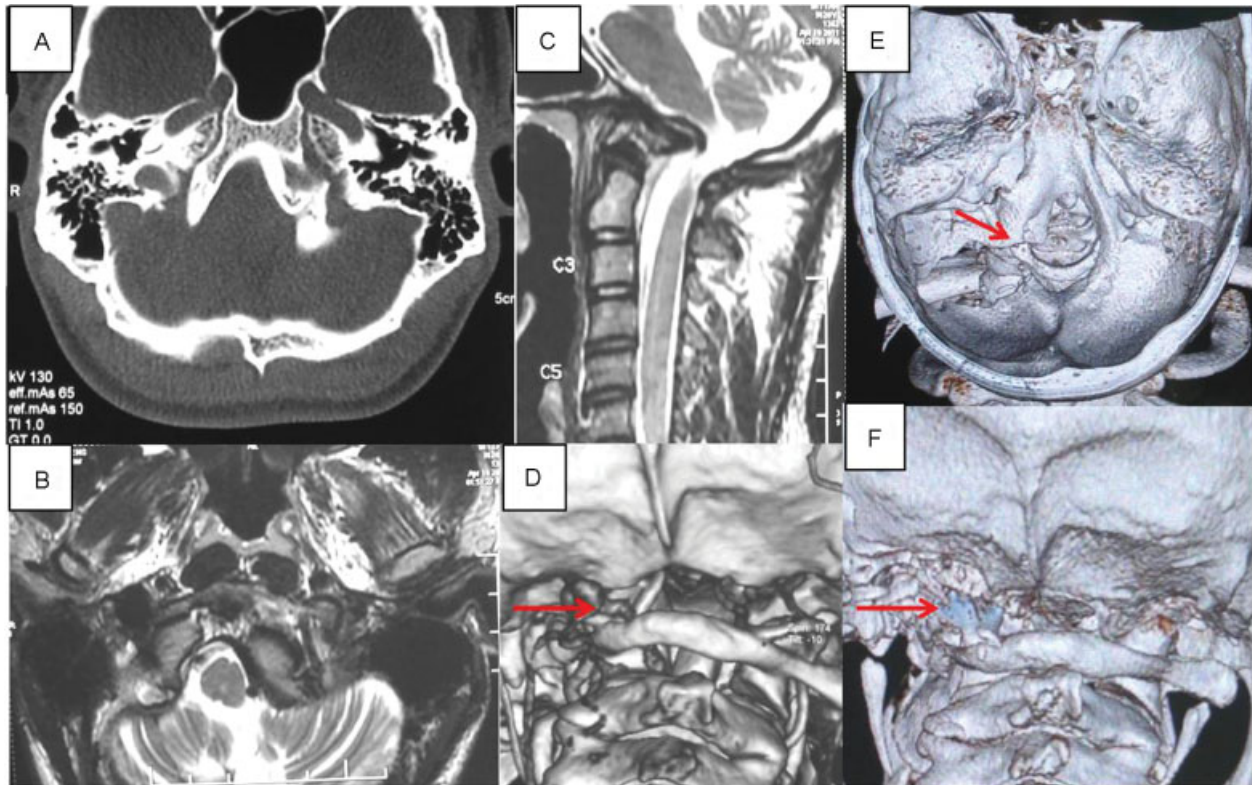


Fig. 2 Preoperative: (A) Axial section computed tomography (CT) image with bone window setting at the level of occipital condyles (OCs) showing malunited fracture of left OC seen as a bony exuberance projecting posteromedially with resultant asymmetry. (B) T2-weighted axial magnetic resonance (MR) image at the level of skull base reveals posteromedially dislocated left lateral mass of C1 causing rotational compression of cervicomedullary junction (CMJ) and effacement of adjacent cerebrospinal fluid space. (C) Left parasagittal T2-weighted MR image shows prominent anterior bony projection causing compression of CMJ. (D) Volume-rendered CT image of CVJ viewed from posterior aspect reveals translational and rotatory dislocation of atlanto-occipital joint (AOJ) with reduced AOJ space (arrow) on the left side. Postoperative: (E) volume-rendered CT image of foramen magnum and CVJ (posterosuperior view) shows partially excised left OC (arrow) with adjoining left paramedian suboccipital craniectomy. (F) Volume-rendered CT image of foramen magnum and CVJ (posterior view) shows titanium cage (arrow) used for distraction of left AOJ space.

patients remained under regular follow-up till 3 years after their surgeries and improved to near normal neurologically.

Discussion

AODFs are rare and pose a challenge for diagnosis.^{1,2,8,10} These injuries are being reported recently with greater frequency due to increasing availability and use of CT scan and MR imaging for evaluations of head and spinal trauma.¹⁻³ Delayed presentations in these injuries have been mentioned but are rarely reported.^{1,2,10-13} Delay in diagnoses of these cases, which occurred in both of our cases, appears to be due to lack of understanding of the three-dimensional anatomy, range of motion among the various joints, and variations in the anatomy of CVJ due to occasional anomalies.^{1-3,11-13} Vertebral arteries, lower cranial nerves, and CMJ further incite apprehension for contemplating surgical treatments of CVJ in many surgeons. Various classifications focus on the stability of the CVJ but are insufficient for deciding treatment strategy.^{4,5} Most of the cases reported in the literature have been managed by neck stabilization methods conservatively or by occipitocervical fusion surgeries.^{1,9,14,15} Both of our cases presented years (5 and 12 years) after initial trauma and, despite undergoing advanced imaging studies such as high-resolution CT, MR

imaging, and angiography of CVJ, were undiagnosed mainly due to paucity of radiologists and surgeons who specialize in CVJ radiology and surgeries, respectively. We could find only one report of three patients with AOD presented after varying periods ranging from weeks to years after trauma, the longest interval being 18 years.¹⁶

Classifications by Tuli et al⁴ and Anderson and Montesano⁵ focus on the stability of CVJ, which may be helpful in some cases, but we feel that AOJ injuries are so rare that it is difficult to standardize any classification-based treatment protocol for such patients.⁶ Their rarity calls for individualization of treatments in such patients and detailed evaluation of radiology of OCs, C1, C2, and neurovascular structures of CMJ by the radiologist and the surgeon himself who is experienced in surgeries of CVJ. Volume-rendered CT images reveal morphologies of the region, which help the surgeon most while carrying out surgery, if needed. Compressions over CMJ, in both the cases reported, had undergone various diagnostic studies before the patient reported to our hospital and helped us to select transcondylar/far-lateral approach for surgical decompressions. Intraoperative assessment of CVJ stability further helped not to fix the CVJ as preoperative dynamic X-ray of CVJ were not done in both the cases due to compromised respirations. There is only one report of

condylar fracture with occipitalized C1 in a 79-year-old patient with neck pain only, whereas our patient with occipitalized C1 (patient 1) had significant neurologic symptoms.⁷ One report from India reveals 1% incidence of these fractures as opposed to higher incidences in the literature.⁸ This may be due to limited centers and personnel capable of diagnosing these lesions and economic backgrounds of the patients who are affected due to poor access and healthcare infrastructure in low-income countries like India.¹⁷

We conclude that AODF may present late with diagnostic challenge. Management of these cases needs thorough knowledge of the anatomy of CVJ. Treatments of these patients should be individualized and should focus on restoring stability and alignment of CVJ and decompression of neurovascular structures at CMJ.

Note

Presented at the Annual Neurotrauma Conference at the All India Institute of Medical Science, New Delhi, India, August 2015.

Disclosures

None.

Conflict of Interest

None.

Funding

None.

Acknowledgment

Deepak K. Jha, MCh, contributed to the study concept, design, and manuscript preparation. Monali Chatruvedi, MD, contributed to radiological evaluation and manuscript editing. Mukul Jain, MD, contributed to literature research, photographs, and manuscript editing. Arvind Arya, MD, contributed to literature research and concept. Suman Kushwaha, DM, contributed to clinical evaluation and manuscript editing. The manuscript has been seen and approved by all the authors for submission in the journal for publication.

References

- 1 Utheim NC, Josefsen R, Nakstad PH, Solgaard T, Roise O. Occipital condyle fracture and lower cranial nerve palsy after blunt head trauma - a literature review and case report. *J Trauma Manag Outcomes* 2015;9:2
- 2 Waseem M, Upadhyay R, Al-Husayni H, Agyare S. Occipital condyle fracture in a patient with neck pain. *Int J Emerg Med* 2014;7(1):5
- 3 Link TM, Schuierer G, Hufendiek A, Horch C, Peters PE. Substantial head trauma: value of routine CT examination of the cervicocranium. *Radiology* 1995;196(3):741-745
- 4 Tuli S, Tator CH, Fehlings MG, Mackay M. Occipital condyle fractures. *Neurosurgery* 1997;41(2):368-376, discussion 376-377
- 5 Anderson PA, Montesano PX. Morphology and treatment of occipital condyle fractures. *Spine* 1988;13(7):731-736
- 6 Tomaszewski R, Wiktor Ł. Occipital condyle fractures in adolescents. *Ortop Traumatol Rehabil* 2015;17(3):219-227
- 7 Burke SM, Huhta TA, Mackel CE, Riesenburger RI. Occipital condyle fracture in a patient with occipitalisation of the atlas. *BMJ Case Rep* 2015;2015:2015
- 8 Panigrahi MK, Mohan BV, Purohit AK. Management of post traumatic cranio vertebral joint instability. *Ind J Neurotrauma* 2005;2(2):117-125
- 9 Dinç C, Türkoğlu ME, Tuncer C, Aykanat O, Özçelik D, Ozkan G. Occipital condyle fractures: a case report [in Turkish]. *Ulus Travma Acil Cerrahi Derg* 2014;20(3):224-226
- 10 Krüger A, Oberkircher L, Frangen T, Ruchholtz S, Kühne C, Junge A. Fractures of the occipital condyle clinical spectrum and course in eight patients. *J Craniovertebr Junction Spine* 2013;4(2):49-55
- 11 Bolender N, Cromwell LD, Wendling L. Fracture of the occipital condyle. *AJR Am J Roentgenol* 1978;131(4):729-731
- 12 Deeb ZL, Rothfus WE, Goldberg AL, Daffner RH. Occult occipital condyle fractures presenting as tumors. *J Comput Tomogr* 1988;12(4):261-263
- 13 Orbay T, Aykol S, Seçkin Z, Ergün R. Late hypoglossal nerve palsy following fracture of the occipital condyle. *Surg Neurol* 1989;31(5):402-404
- 14 Karam YR, Traynelis VC. Occipital condyle fractures. *Neurosurgery* 2010;66(3, Suppl):56-59
- 15 Blacksins MF, Lee HJ. Frequency and significance of fractures of the upper cervical spine detected by CT in patients with severe neck trauma. *AJR Am J Roentgenol* 1995;165(5):1201-1204
- 16 Ahmed ARM, Bhat DI, Devi I, Chandramauli BA. Management dilemmas in delayed presentation of traumatic atlanto-occipital dislocations. *Ind J Neurotrauma* 2005;2(1):41-45
- 17 Ganapathy K. Neurosurgery in India: an overview. *World Neurosurg* 2013;79(5-6):621-628