

Attempted Suicide with Needle Penetration through Cranial Defect: A Rare Case Report

Sajad Hussain Arif¹ Uday Singh Raswan¹ Masood Laharwal¹ Altaf Umar Ramzan¹

¹Department of Neurosurgery, Sher-i-Kashmir Institute of Medical Sciences, Srinagar, Jammu and Kashmir, India

Indian J Neurotrauma 2016;13:104–106.

Address for correspondence Uday Singh Raswan, MCh, Department of Neurosurgery, Sher-i-Kashmir Institute of Medical Sciences, Room Number G8, New Married Hostel, Srinagar, Jammu and Kashmir 190011, India (e-mail: usrx95@gmail.com).

Abstract

Intracranial foreign bodies are usually secondary to penetrating injuries through the orbit, ear, or cranial bones. Nails, knives, screwdrivers, sewing needles, bullets, and shrapnel have been described related to penetrating brain injury (PBI). The majority of deaths from trauma reflect unintentional accidents, but a significant minority follow suicide and even a smaller proportion (less than 10%) reflect homicide. Self-inflicted injuries among psychiatric patients are not uncommon. We report a rare case of a 35-year-old woman who tried to commit suicide by inserting a needle in her brain through cranial defect. Needle was removed and patient recovered uneventfully. Awareness of the psychological condition and suicide precautionary measures should be kept in mind in all cases of self-inflicted PBI patients.

Keywords

- ▶ penetrating brain injury
- ▶ needle
- ▶ suicide
- ▶ cranial defect

Introduction

Intracranial foreign bodies are usually secondary to penetrating injuries through the orbit, ear, or cranial bones. Nails, knives, screwdrivers, sewing needles, bullets, and shrapnel have been described related to penetrating brain injury (PBI). The majority of deaths from trauma reflect unintentional accidents, but a significant minority follow suicide and even a smaller proportion (less than 10%) reflect homicide.¹ Self-inflicted injuries among psychiatric patients are not uncommon. We report a rare case of a 35-year-old woman who tried to commit suicide by inserting a needle in her brain through cranial defect.

Case Report

History

A 35-year-old woman presented to our hospital outpatient department with complains of discharging sinus (serous fluid) over the left frontal scalp region since 15 days. It was learned that she had been previously operated 15 years back for posttraumatic depressed fracture with underlying extradural hemorrhage, depressed segments of left frontal

bone were removed. A skull lateral and anteroposterior X-ray (▶Fig. 1a, b) and a computed tomography (CT) scan (▶Fig. 2) of the head demonstrated a hyperdense foreign body penetrating through the defect in left frontal bone, which appeared to be a needle. After discussing the radiological findings with the patient, she admitted to have forcefully driven the needle into her cranium 2 years back through the defect with an intention to commit suicide. Following the attempt, she had no history of seizure or loss of consciousness. Also, she was on irregular psychiatric follow-up for management of depression for more than 7 years.

Examination

A neurological examination was entirely normal. During the physical examination, a small penetrating wound was identified on the left frontal area with deficient underlying bone.

Operation

A left frontal incision around bony defect was placed and skin flap was raised. The dura mater was found to be lacerated. Dura was opened meticulously for widened exposure. The foreign body, a needle 5 cm in length (▶Fig. 3), was found embedded

received

May 1, 2016

accepted

June 21, 2016

published online

July 26, 2016

© 2016 Neurotrauma Society of India

DOI <http://dx.doi.org/>

10.1055/s-0036-1586217.

ISSN 0973-0508.

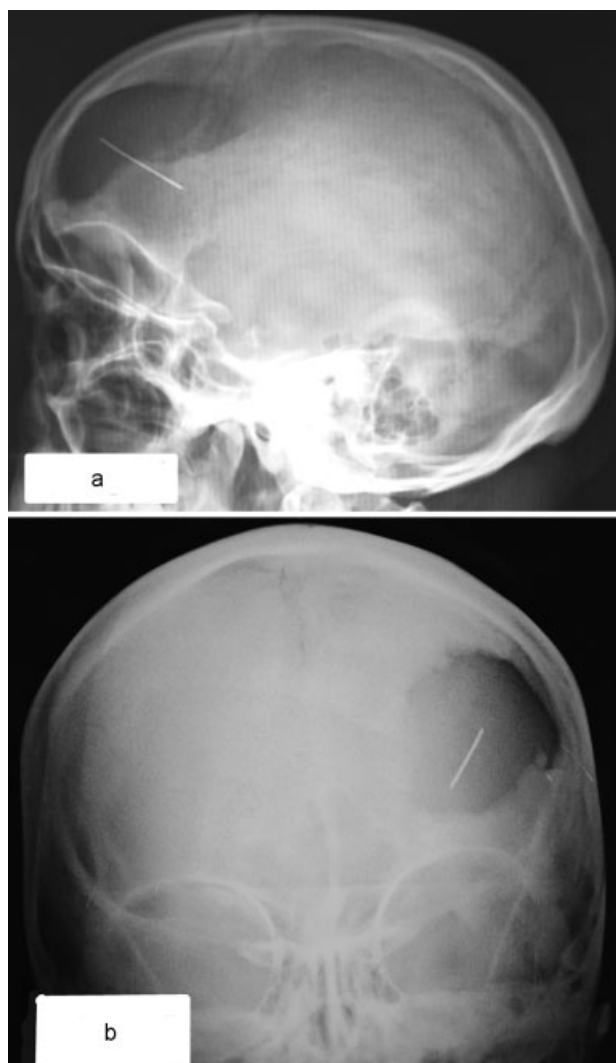


Fig. 1 X-ray of a skull: (a) lateral view and (b) anteroposterior view. Left frontal bone defect with a needle seen in it.

in the brain matter with surrounding fibrotic adhesions. Needle was removed (→**Fig. 4**) in line of its original axis to avoid bleeding. Wound site was decontaminated thoroughly and hemostasis maintained under direct vision. Watertight dural closure was achieved. Also, cranioplasty for previous defect was done using polymethylmethacrylate. The skin flap was repositioned aseptically over a subgaleal drain. Vitals were maintained within normal limit during the entire intraoperative period. After the surgery, the patient was successfully extubated with stable vitals and shifted to intensive care unit. Rest of the postoperative phase was uneventful.

Postoperative Course

Postoperative neurological examination revealed no neurological deficit. Treatment with antibiotic and antidepressants drugs was continued similarly to the preoperative phase. The patient was assessed by a psychiatrist confirming the self-inflicted injury diagnosis; however, the mental status of the patient was found normal.

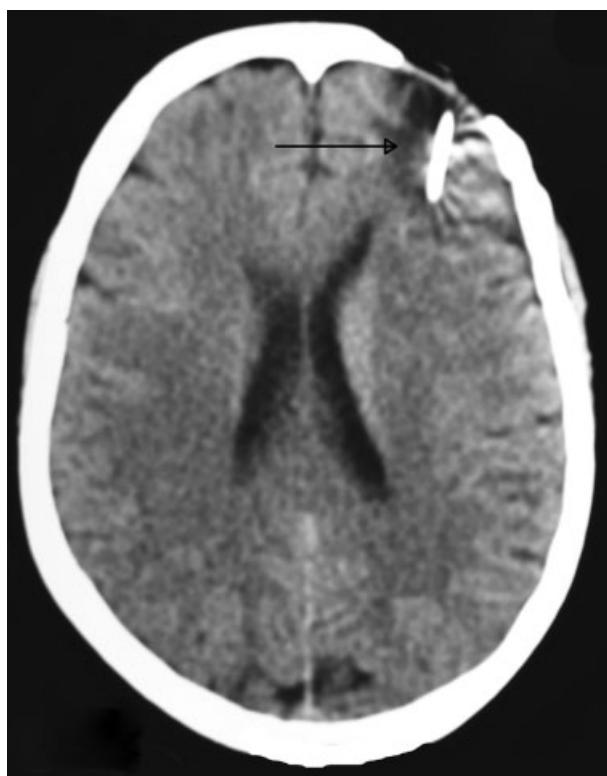

Fig. 2 Noncontrast computed tomography brain shows foreign body (needle [arrow]) in the left frontal cortex.

After 1 week, the patient was discharged along with psychiatric and psychological counseling. Relatives were advised to keep her away from all such objects which can potentially be used as a weapon for self-harm. Neither clinical nor radiological evidence of infection and/or any other complication was documented during 1 year of follow-up.

Discussion

PBIs have higher mortality and morbidity than blunt trauma even in civilian set up. Worldwide most penetrating injuries are caused by missile injuries, notably gun shot, and shrapnel wounds. Most penetrating nonmissile injuries are caused by cutting instruments, but the list of other objects includes stones, sharpened wooden sticks, screwdrivers, nails, spikes, iron rods, arrows, pencils, ice picks, chopsticks, umbrella ends, sewing needles, and garden forks.²⁻⁴

The complications of such injuries include intraparenchymal lesions such as cerebral contusions, cerebrospinal fluid (CSF) fistulas, intracerebral hematoma, subdural and epidural hematomas, subarachnoid hemorrhage, pneumocephalus, skull fracture, cerebral edema. The infectious complications include brain abscess, encephalitis, meningitis, and scalp sepsis. The vascular complications, such as pseudoaneurysms, posttraumatic arteriovenous malformation, though rare can occur following penetrating trauma.^{5,6}

Optimum management of PBI requires adequate comprehension of mechanism and pathophysiology of injury. On the basis of current evidence, we recommend CT

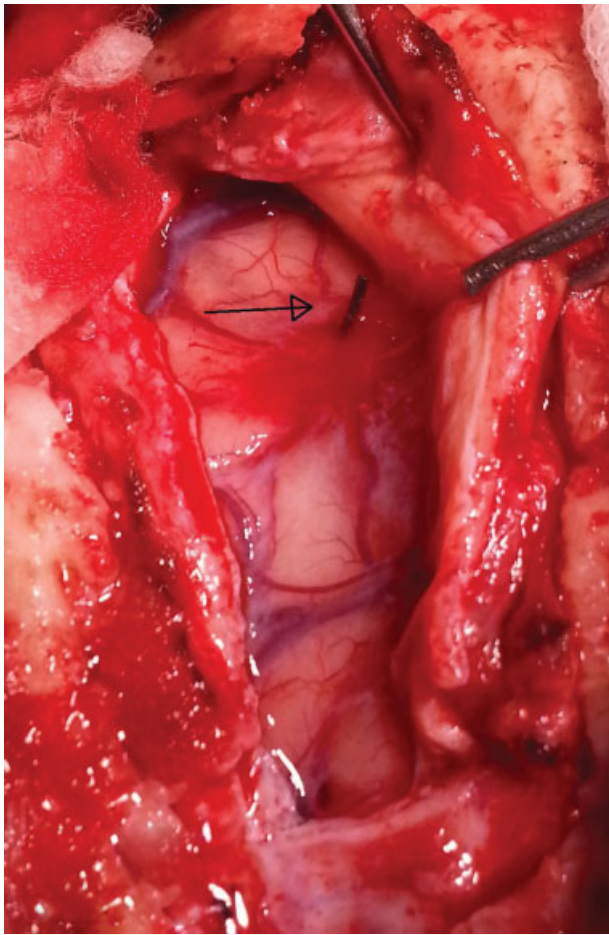


Fig. 3 Arrow shows needle going through the cerebral cortex.

scanning as the neuroradiologic modality of choice for PBI patients. The cerebral angiography is recommended in patients with PBI, where there is a high suspicion of vascular injury, if a vascular complex is crossed. It is still debatable whether craniectomy or craniotomy is the best approach in PBI patients. The goals of surgery are hemostasis, debridement to reduce intracranial pressure (ICP) and infections after closure, evacuation of a clot causing mass effect or midline shift, and repair of dura and scalp hemostasis.⁷ The CSF leaks are common in PBI patients and surgical correction is recommended for those which do not close spontaneously or are refractory to CSF diversion through a ventricular or lumbar drain. The risk of posttraumatic

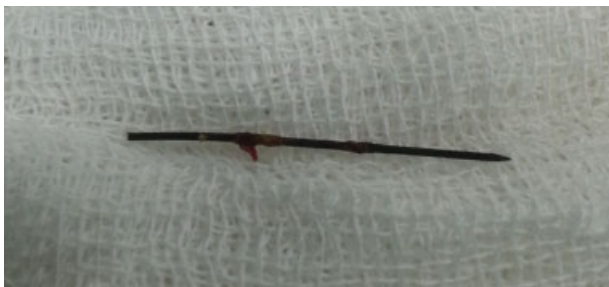

Fig. 4 Needle after removal.

epilepsy after PBI is high, and therefore, the use of prophylactic anticonvulsants is recommended. The advanced age, suicide attempts, associated coagulopathy, Glasgow coma scale score of 3 with bilaterally fixed and dilated pupils, and high initial ICP have been correlated with worse outcomes in PBI patients.^{1,8}

In this study, we report a case of cranial penetrating injury caused by a needle. The clinical–radiological findings in our patient strongly suggested that the needle was intentionally inserted into the brain by the patient herself. The patient was fortunate that the needle did not injure any vessel, and that no other complications occurred. Although the mental status of our patient was normal, history of depression may have been the contributing factor for the suicide attempt, irregular psychiatric follow-up contributing to the same. A family history of suicidal behavior, history of psychiatric hospitalization, and symptoms of anxiety or depression are the risk factors for suicidal ideation. The presented case is interesting from the standpoint of the method used, a needle, which has not been reported previously.

Awareness of the psychological condition and suicide precautionary measures should be kept in mind in all cases of self-inflicted PBI patients. Along with infection control, PBI patients need prompt surgical intervention to remove the foreign bodies, hematomas, and nonviable brain tissue, to repair the broken dura, to reconstruct the skull base and vascular structures, if indicated. Psychiatric care along with psychological counseling of the patient and the relatives is mandatory to prevent recurrence of such an event in future.

Conflict of Interest

No potential conflict of interest relevant to this case report was reported.

References

- 1 Cemil B, Tun K, Yiğenoğlu O, Kaptanoğlu E. Attempted suicide with screw penetration into the cranium. *Ulus Travma Acil Cerrahi Derg* 2009;15(6):624–627
- 2 Bhaganagare A, Nandkarni T, Goel A. Penetrating craniocerebral injury with nails. *Indian J Neurotrauma* 2007;4(1):63–64
- 3 Kelly DF, Nikas DL, Becker DP. Diagnosis and treatment of moderate and severe head injuries in adults. In: Winn HR. *Youmans Neurological Surgery*. Philadelphia: Elsevier Saunders; 1996:1618–1718
- 4 Seex K, Koppel D, Fitzpatrick M, Pyott A. Trans-orbital penetrating head injury with a door key. *J Craniomaxillofac Surg* 1997;25(6):353–355
- 5 Kieck CF, de Villiers JC. Vascular lesions due to transcranial stab wounds. *J Neurosurg* 1984;60(1):42–46
- 6 Satyarthee GD, Borkar SA, Tripathi AK, Sharma BS. Transorbital penetrating cerebral injury with a ceramic stone: report of an interesting case. *Neurol India* 2009;57(3):331–333
- 7 Rashid BA, Afzal WM, Kirmani AR, et al. Disaster management of civilian gunshot head wounds in north Indian state. *Indian J Neurotrauma* 2009;6(1):27–42
- 8 Kazim SF, Shamim MS, Tahir MZ, Enam SA, Waheed S. Management of penetrating brain injury. *J Emerg Trauma Shock* 2011;4(3):395–402