

Head Injury due to Camel Bite: An Uncommon and an Unusual Mode of Presentation

Hanuman Prasad Prajapati¹ Sita Ram Ranwa¹ Somnath Sharma¹ Achal Sharma¹

¹Department of Neurosurgery, S.M.S. Medical College & Hospital, Jaipur, Rajasthan, India

Address for correspondence Hanuman Prasad Prajapati, MS, Department of General Surgery, S.M.S. Medical College & Hospital, 136, Gurunanakpura, Raja Park, Jaipur, Rajasthan 302004, India (e-mail: pushpa84.dhp@gmail.com).

Indian J Neurotrauma 2016;13:101–103.

Abstract

Keywords

- ▶ camel bite
- ▶ head injury
- ▶ depressed skull fracture

Animal bite injuries are common worldwide, but head injuries caused by animal bite is uncommon, and specially, head injuries caused by camel bite is further uncommon. Seriousness of head injuries depends on the size and shape of the teeth of animal. Camel bites causing depressed skull fracture with injury to the dura are extremely rare. Here, we present a case report of camel bite injury causing depressed fracture and dural tear.

Introduction

Injuries due to animal bite have become common as the use of domestic animals has increased. Bite injury from animal now constitute between 1 and 3% of emergency center visits worldwide.^{1,2} In animals, most animal bite injuries in humans are caused by dogs.^{1–3} Head injuries due to camel bite are uncommon and unusual, and such cases have mostly been reported in the Middle East countries. In India, such cases have been reported, although rarely, in the desert area of Rajasthan state. Most injuries occur during camel rutting season. Mostly, the camel caregivers are prone to head injuries from camel bite, and camel jockeys report fewer cases of such injuries. The centropacial region was the most commonly affected region, constituting approximately 75% of cases.^{3–6}

Case Report

Our patient 32-year-old man, a camel caregiver, presented to our emergence department of trauma center one day after camel bite with stitched wound on the right occipital region. The patient's Glasgow coma scale score (GCS) was 15/15 on admission. Wound present in the right occipital region was 5-cm long and cerebrospinal fluid leak (CSF) discharge was found from the wound (▶**Fig. 1**). Emergency surgery was performed for right occipital wound. Bone pieces were

removed from cisterna magna and dural repair done by using pericranial patch and wound was closed in layers (▶**Fig. 2**).

In postoperative period, wound got infected. Skin wound reopened, daily dressing done, and wound healed by secondary intention. During the hospital stay, his GCS was 15/15 (▶**Fig. 3**).

Discussion

Head injury due to camel bite is uncommon and unusual.⁷ Only few cases have been reported in the literature and most of them are from the Middle East countries. Suess et al⁸ reported severe cases of camel bite injuries over the head of a 3-year-old child. There was a depressed skull bone fracture with brain parenchymal injury. Abu-Zidan et al⁹ did a prospective study over a period of 6 years, from October 2001 to October 2007, and studied 33 patients. Out of these, 97% cases were from Middle East countries. They concluded that most injury occur during camel rutting season. Most patients were camel caregivers and only few were camel jockeys. Most camel bite injury occurred in the upper limb, and the head and face include only 15% of the cases. They found that serious injuries from camel bite can be prevented by proper training by an experienced person. When being picked up by a camel, an experienced person will close the camel's nose or poke his finger in its eye. Few cases were also reported in literature showing camel bite injury in the neck causing brain infarction.¹⁰

received
March 18, 2016
accepted
April 19, 2016
published online
August 10, 2016

© 2016 Neurotrauma Society of India

DOI <http://dx.doi.org/10.1055/s-0036-1585093>.
ISSN 0973-0508.

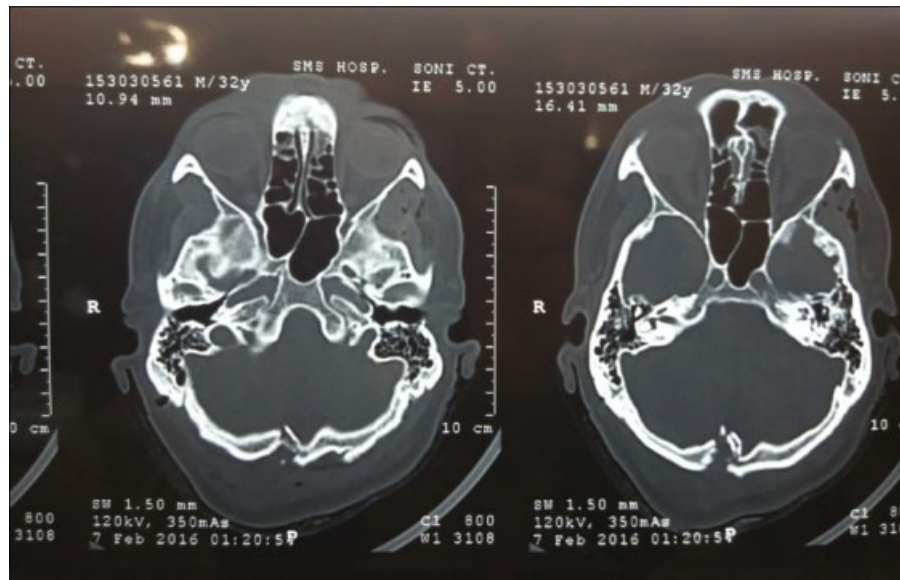


Fig. 1 Preoperative film (right occipital bone depressed fracture).

Camel bite wound vary considerably. These may range from small puncture wounds to extensive lacerations.¹¹ The canine teeth of a camel may reach up to 4 cm in length,¹² acting like a knife that may inflict life-threatening injuries. This explains that though camel tooth injuries may be small on the surface, deep structures can be seriously injured. Furthermore, a camel's long neck allows it to reach around and bite from different angles and positions.

In this case, the camel bite injury was too extensive as it causes depressed skull fracture along with dural tear in right

occipital region with bone pieces driven in the cisterna magna. The injury occurred in the camel caregiver and in rutting season. The patient told that he had closed the camel's nose to get rid of the camel.

Conclusion

Head injury due to camel bite being uncommon and unusual may cause extensive injury to the victim requiring urgent medical attention.

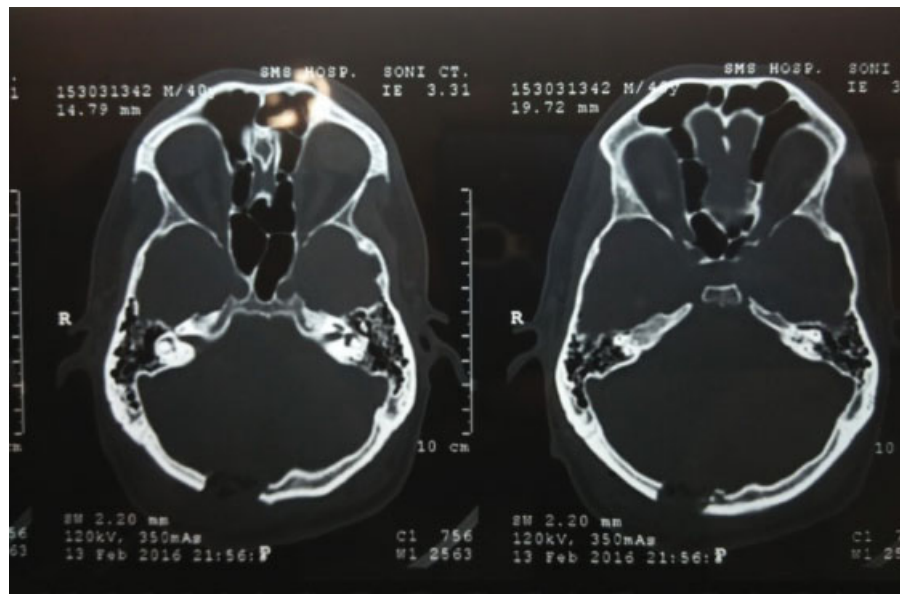


Fig. 2 Postoperative film.

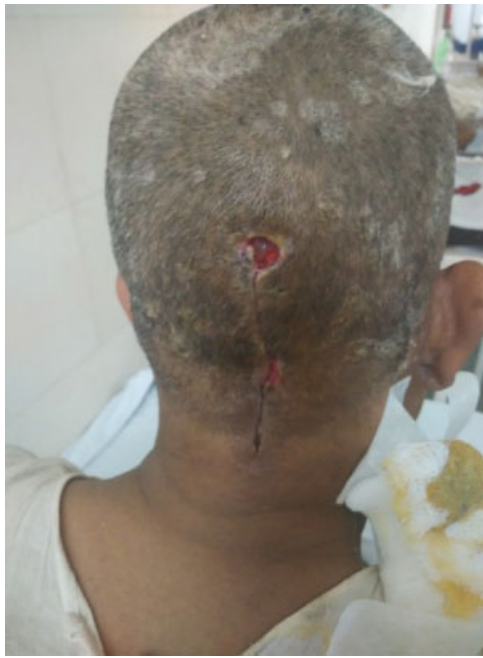

Fig. 3 Infected occipital wound.

Conflict of Interest

Drs. Hanuman Prasad Prajapati, Sita Ram Ranwa, Somnath Sharma, and Achal Sharma have no personal, financial, or institutional interest in any of the drugs, materials, or devices described in this article, and no financial support was received for this article. No financial support was received and no personal assistance was taken for this case report.

Reference

- 1 Pfortmueller CA, Efeoglou A, Furrer H, Exadaktylos AK. Dog bite injuries: primary and secondary emergency department presentations—a retrospective cohort study. *ScientificWorldJournal* 2013;2013:393176
- 2 Benson LS, Edwards SL, Schiff AP, Williams CS, Visotsky JL. Dog and cat bites to the hand: treatment and cost assessment. *J Hand Surg Am* 2006;31(3):468–473
- 3 Sacks JJ, Kresnow M, Houston B. Dog bites: how big a problem? *Inj Prev* 1996;2(1):52–54
- 4 Kesting MR, Hölzle F, Pox C, Thurmüller P, Wolff KD. Animal bite injuries to the head: 132 cases. *Br J Oral Maxillofac Surg* 2006; 44(3):235–239
- 5 Lackmann GM, Draf W, Isselstein G, Töllner U. Surgical treatment of facial dog bite injuries in children. *J Craniomaxillofac Surg* 1992;20(2):81–86
- 6 Monroy A, Behar P, Nagy M, Poje C, Pizzuto M, Brodsky L. Head and neck dog bites in children. *Otolaryngol Head Neck Surg* 2009;140(3):354–357
- 7 Balan JR, Johan JR, Sharma RK. An uncommon presentation of camel bite injury to the head with frontal calvarial bone loss. *Anaplastology* 2014;3:137
- 8 Suess O, Magerkurth O, Da Silva C, Brock M, Pietilä TA. Camel bite: an unusual type of head injury in an infant. *J Pediatr Surg* 2004; 39(10):e11–e13
- 9 Abu-Zidan FM, Eid HO, Hefny AF, Bashir MO, Branicki F. Camel bite injuries in United Arab Emirates: a 6 year prospective study. *Injury* 2012;43(9):1617–1620
- 10 Abu-Zidan FM, Ramdan K, Czechowski J. A camel bite breaking the neck and causing brain infarction. *J Trauma* 2007;63(6): 1423
- 11 Abu-Zidan FM, Hefny AF, Eid HO, Bashir MO, Branicki FJ. Camel-related injuries: prospective study of 212 patients. *World J Surg* 2012;36(10):2384–2389
- 12 Food and Agriculture Organization of the United Nations: A Manual for the Primary Animal Health Care Worker. Camels, llamas and alpacas, Chapter 7. [http://www.fao.org/docrep/0690/E0690c00.htm#chapter_7:camels, llamas and alpacas](http://www.fao.org/docrep/0690/E0690c00.htm#chapter_7:camels,_llamas_and_alpacas). Accessed August 20, 2011