

Versatility of the Free Anterolateral Thigh Flap in the Reconstruction of Large Defects of the Weight-Bearing Foot: A Single-Center Experience with 20 Consecutive Cases

Marco Pappalardo, MD¹ Seng-Feng Jeng, MD, FACS¹ Parviz L. Sadigh, MB ChB¹ Hsiang-Shun Shih, MD¹

¹Department of Plastic Surgery, E-Da Hospital, I-Shou University, Kaohsiung City, Taiwan

J Reconstr Microsurg 2016;32:562–570.

Address for correspondence Hsiang-Shun Shih, MD, Department of Plastic Surgery, E-Da Hospital, No. 1, Yi-Da Road, Jiao-Su Village, Yan-Chao District, Kaohsiung City 824, Taiwan (e-mail: shih0825@ms37.hinet.net).

Abstract

Background Reconstruction of the weight-bearing surface of the foot represents a challenging task. With very little scope to borrow glabrous tissue from adjacent areas means that achieving a “like for like” reconstruction is rarely possible. In this setting, alternative approaches need to be considered. In this article we present our experience with various differing designs of the anterolateral thigh flap (ALT) in the reconstruction of 20 large defects of the weight-bearing sole.

Methods Twenty patients with complex soft tissue defects of the weight-bearing sole underwent reconstruction over a 5-year period. Five cases were complicated by osteomyelitis resulting in significant calcaneal defects. The follow-up period ranged from 8 to 48 months and outcomes were assessed by two-point discrimination and protective sensation, observation of gait, and the ability of the patient to return to wearing normal footwear.

Results All flaps survived with the exception of two partial skin necrosis. Sensory nerve coaptation was performed in 12/20 cases. One patient underwent second-stage total calcaneal reconstruction with a fibula osteocutaneous flap. Five large defects were reconstructed with the split skin paddle technique to allow for direct donor-site closure. No evidence of postoperative ulceration was noted in any of the patients over the follow-up period and all were satisfied regarding the functional and aesthetic results achieved.

Conclusion Complex defects of the weight-bearing sole can be successfully reconstructed using the free ALT flap resulting in very favorable functional outcomes. Even when calcaneal osteomyelitis has set in, excellent outcomes can be achieved.

Keywords

- ▶ weight-bearing sole reconstruction
- ▶ calcaneal reconstruction
- ▶ anterolateral thigh perforator flap

Successful reconstruction of the weight-bearing surface of the foot represents a reconstructive challenge to the plastic surgeon, owing to the unique anatomical and functional characteristics of this region. The plantar glabrous skin, the subcutaneous tissue, rich with thick septae, and the calcaneus all play key roles in standing and normal gait. Restoration of weight-bearing function, therefore, requires careful and considered reconstruction of these anatomic components.¹ In

1986, Hidalgo and Shaw classified foot injuries into three types based on the degree of soft tissue and bony involvement.² Type I corresponds to small soft tissue defects, type II represents large soft tissue defects without bony involvement, and type III represents large soft tissue defects with bony involvement. Although many type I defects can be managed with local flaps from the plantar region^{3–5} or indeed regional flaps^{6,7}; for the larger and more complex types II and

received
January 8, 2016
accepted after revision
April 3, 2016
published online
June 21, 2016

Copyright © 2016 by Thieme Medical Publishers, Inc., 333 Seventh Avenue, New York, NY 10001, USA.
Tel: +1(212) 584-4662.

DOI <http://dx.doi.org/10.1055/s-0036-1584204>.
ISSN 0743-684X.

III defects, free tissue transfer invariably represents the best reconstructive option.⁸ Currently most authors advocate two main reconstructive strategies for large soft tissue defects of the sole, namely skin-grafted free muscle flaps or free fasciocutaneous flaps.⁸⁻¹⁴ Indeed, perforator flaps also represent an attractive reconstructive option.¹⁵

Since its description by Song et al in 1984,¹⁶ the antero-lateral thigh flap (ALT) has become a popular choice with many reconstructive surgeons due to its long pedicle length, sizable vessels for microanastomosis, and good donor-site profile. Regarding reconstruction of complex plantar defects, perhaps the main advantage of the ALT is the variation in its design that can be achieved secondary to its versatile yet variable vascular anatomy. Indeed, the ALT has recently become our fasciocutaneous perforator flap of choice when tackling these challenging cases. In addition, a large cutaneous surface area can be harvested from a single donor site, it can be harvested as a sensate flap and its thickness can be reliably thinned at the same sitting. With complex defects of the foot (type III) with associated calcaneal osteomyelitis, it can also be harvested with a cuff of vastus lateralis to obliterate dead space. Moreover, the donor-site morbidity can be minimized by harvesting a split skin paddle based on two or more sizable perforators, thus allowing for direct closure of the donor site at the same time as achieving a bespoke three-dimensional reconstruction.

Methods

Between January 2008 and September 2013, 20 patients (14 males, 6 females) were treated for large defects of the weight-bearing foot with free ALT flaps. Age ranged from 17 to 75 years old with a mean of 48.5 years. The defects were secondary to trauma in 15 cases, malignant melanoma in 2 cases, diabetic ulceration in 2 cases, and limb ischemia in 1 case. Four traumatic defects were initially treated by skin grafting in the first instance that resulted in recurrent ulceration and contractures. The size of the defects ranged from 80 to 300 cm² with a mean size of 180 cm².

According to the Hidalgo and Shaw classification,² we defined 15 defects as type II and 5 defects as type III. Six patients had associated fractures whereas five presented calcaneal osteomyelitis with one of these progressing to total calcaneal loss. Defects were analyzed based on site, size, condition of the underlying bone, presence of infection, and patient comorbidities. These are presented in ► **Table 1**.

We raised the ALT flaps using the manner described in previous reports.^{17,18} When a sensate flap was required, care was taken to include branches of the lateral femoral cutaneous nerve (LFCN) found in the lateral aspect of the proximal portion of the skin paddle. Antibiotic beads (Zimmer Bone Cement [Heraeus Medical, Manufactured by Heraeus Kulzer GmbH, Wehrheim, Germany] with vancomycin 2 g + gentamicin 320 mg) were deployed for patients with calcaneal osteomyelitis after bony debridement had been performed. To ensure direct donor-site closure, the width of the skin paddle was confined to no more than 16% of the thigh circumference.¹⁹ For defects wider than this, we recommend splitting the skin paddle, based on at least two sizable perforators, as this not only ensures direct

donor-site closure but also a three-dimensional inset at the recipient site. Indeed, by adopting this policy, one can achieve a bespoke subunit-like reconstruction when dealing with large defects involving the heel and sole, while minimizing the impact on the donor site and avoiding the need for a skin graft. This modification would be planned preoperatively by mapping at least two perforators of the lateral circumflex femoral system with handheld Doppler. The flap would then be raised as a single skin paddle before being split into two separate flaps nourished by the same source vessel. These skin paddles could then be arranged to provide a three-dimensional reconstruction. The skin paddle appointed to the non-weight-bearing zone will be primarily thinned to improve contour and the paddle appointed to the weight-bearing area will overlap a deepithelialized portion of the thinned skin flap to provide additional cushioning to the heel.

Patients with no associated fracture were permitted to partially weight-bear with crutches after 3 to 4 weeks. Those with associated calcaneal osteomyelitis were permitted gradual weight bearing on the flap at 6 to 18 weeks postoperatively, depending on the severity of the calcaneal defect. During the follow-up period, functional and sensory evaluations of outcomes were assessed by way of recording two-point discrimination, protective sensation, ulcer formation, and the rate of return to normal footwear.

Results

Patients were followed up postoperatively for a mean of 24 months (range: 8–48 months). All of the flaps survived with the exception of two cases in which partial skin flap necrosis secondary to infection was encountered. One required debridement and skin grafting, whereas the other was successfully managed conservatively. Both patients were diabetic and healed without secondary complications. Two flaps required reexploration secondary to venous congestion and both were successfully salvaged. The size of the flaps ranged from 10 to 32 cm in length to 6 to 9 cm in width, with a mean surface area of 180 cm². Sensory nerve coaptation of the LFCN to an available sensory nerve at the recipient site was performed in 12 cases. Four patients with small calcaneal defects were treated with antibiotic beads to fill the dead space and control the infection, and one patient with total destruction of the calcaneus secondary to osteomyelitis underwent second-stage calcaneal reconstruction with a double-barrelled free fibula osteocutaneous flap. All donor sites were closed directly with no episodes of postoperative dehiscence. In five cases involving large soft tissue defects, this was achieved by way of splitting the skin paddle as described earlier. In those patients with no bony involvement, the average time of returning to work with unaided mobility was 7.5 weeks. Four of the five cases with associated calcaneal osteomyelitis achieved this at 9 to 10 weeks, whereas one patient who underwent total calcaneal reconstruction obtained full unaided weight-bearing status at 32 weeks postoperatively. During the follow-up period, the neurotized flaps demonstrated a static two-point discrimination between 12 and 15 mm at 5 months postprocedure.

Table 1 Summary of cases

Patient	Age (y)	Sex	Comorbidity	Etiology	Location	Defect size (cm)	Type ^a	Additional procedures	F/U (mo)	Complications	PWB/FWB (wk)	Sensation 2pd (mm)	Protective sensation	Delayed ulceration	Normal shoes
1	60	M	DM	Melanoma	Plantar forefoot	8 × 10	II	No	40	No	4/6	N/A	Yes	No	Yes
2	65	M	HTN	Trauma	Heel and midfoot	22 × 9	II	Sensory nerve coaptation	42	No	4/8	15	Yes	No	Yes
3	24	F	No	Trauma	Midplantar and heel	15 × 8	II	Sensory nerve coaptation	24	No	N/A	12	Yes	No	Yes
4	21	M	No	Unstable scar, previous trauma	Heel	10 × 10	II	Sensory nerve coaptation	48	No	3/6	12	Yes	No	Yes
5	64	M	No	Melanoma	Plantar forefoot	10 × 10	II	No	15	No	4/6	N/A	Yes	No	Yes
6	17	F	No	Trauma	Complete sole and heel	18 × 16	II	Sensory nerve coaptation + split skin paddle design	15	Reexploration	4/8	15	Yes	No	Yes
7	50	F	TB	Trauma	Midplantar and heel	20 × 8	II	Sensory nerve coaptation	26	No	4/6	12	Yes	No	Yes
8	56	F	DM HTN	Diabetic Ulcer and calcaneal osteomyelitis	Heel, calcaneus and midfoot	19 × 9	III	Antibiotic beads	20	Partial flap necrosis	7/10	N/A	Yes	No	Yes
9	52	M	DM	Previous trauma and calcaneal osteomyelitis	Heel, calcaneus and ankle	22 × 8	III	Sensory nerve coaptation + antibiotic beads	19	No	6/9	12	Yes	No	Yes
10	32	F	No	Unstable ulcer, previous trauma	Heel and ankle	18 × 14	II	Sensory nerve coaptation + split skin paddle design	8	No	4/8	12	Yes	No	Yes
11	67	M	CAD, DM	Heart failure and limb ischemia	Forefoot and midplantar	8 × 18	II	No	8	No	4/8	N/A	Yes	No	Orthotic shoes
12	32	M	Poliomyelitis	Previous trauma and calcaneal osteomyelitis	Heel and calcaneus	9 × 14	III	Sensory nerve coaptation + Antibiotic beads	10	No	6/9	15	Yes	No	Yes
13	54	M	DM HTN	Diabetic ulcer	Forefoot	9 × 15	II	No	14	No	4/6	N/A	Yes	No	Orthotic shoes
14	54	F	HTN	Trauma	Heel and midplantar	14 × 16	II	Sensory nerve coaptation + split skin paddle design	24	No	4/9	12	Yes	No	Yes
15	44	M	HTN	Trauma and calcaneal osteomyelitis	Heel, calcaneus and midplantar	25 × 9	III	Sensory nerve coaptation + antibiotic beads	19	No	8/10	15	Yes	No	Yes
16	60	M	HTN	Trauma	Complete sole	20 × 9	II	No	19	Reexploration	4/8	N/A	Yes	No	Yes

Table 1 (Continued)

Patient	Age (y)	Sex	Comorbidity	Etiology	Location	Defect size (cm)	Type ^a	Additional procedures	F/U (mo)	Complications	PWB/FWB (wk)	Sensation 2pd (mm)	Protective sensation	Delayed ulceration	Normal shoes
17	46	M	DM HTN	Unstable ulcer, previous trauma	Complete sole and heel	20 × 14	II	Sensory nerve coaptation + split skin paddle design	16	Partial flap necrosis	4/9	15	Yes	No	Yes
18	75	M	DM HTN	Trauma	Forefoot and midfoot	25 × 9	II	No	48	No	4/8	N/A	Yes	No	Yes
19	48	M	HTN	Trauma	Midplantar, heel, and ankle	25 × 12	II	Sensory nerve coaptation + split skin paddle design	40	No	4/10	12	Yes	No	Yes
20	50	M	No	Trauma and calcaneal osteomyelitis	Heel and calcaneus	14 × 8	III	Antibiotic beads, second-stage free fibula flap	23	No	18/32	N/A	Yes	No	Yes

Abbreviations: 2pd, two-point discrimination test; CAD, coronary artery disease; DM, diabetes mellitus; F/U, follow-up; F, female; FWB, full weight bearing; HTN, hypertension; M, male; N/A, not applicable; PWB, partial weight bearing; TB, tuberculosis.
^aHidalgo and Shaw classification.

On the other hand, two-point discrimination in non-neurotized flaps was never detectable. Protective sensation returned in all patients and was observed as early as 4 months in nine patients from the neurotized flap group. Eighteen patients were able to wear normal shoes, whereas two patients required adjunctive orthotic footwear. Over the entire follow-up period, no episodes of postoperative ulceration over the reconstructed weight-bearing zones were encountered and all the patients were satisfied regarding the functional and aesthetic results achieved (► Figs. 1–3).

Video 1

A 50-year-old man underwent two-stage total calcaneal reconstruction with free ALT flap and free fibula osteocutaneous flap. The video demonstrates the patient walking with normal gait. Online content including video sequences viewable at: https://www.thieme-connect.com/products/ejournals/html/doi/10-1055-s-0036-1584204-JRM-15-0304-v1_1.mp4.

Discussion

The primary goals in the reconstruction of the weight-bearing zones of the foot are to restore function and allow the patient to return to wearing normal footwear while keeping donor-site morbidity to a minimum.^{15,20,21} However, this is a challenging task, as the unique weight-bearing property of the foot is almost impossible to replace. The reconstructive principle of replacing “like with like” is achievable only for small- to medium-sized soft-tissue defects with pedicled^{3–5} or free flaps taken from the instep.^{22,23} These flaps include the same anatomical features that are unique to the plantar skin, namely the thick, waxy glabrous skin, a thin layer of subcutaneous fat, and dense fibrous septae that anchor the skin to the underlying fascia.⁵ However, when defects of the plantar foot are larger than 100 cm² or are associated with fractures or chronic infection, skin-grafted muscle flaps and free fasciocutaneous flaps are considered the two main reconstructive options.^{8–14} Historically skin-grafted free muscle flaps were believed to yield optimal results^{8,11,12}; however, functional impairment, absence of sensation and high ulceration rates have since been highlighted.^{13,14} On the other hand, fasciocutaneous flap can provide thin, pliable tissue that can be neurotized, but the main disadvantage is the high modulus of shear in the subcutaneous plane resulting in a degree of instability when mobilizing.^{10,13,24}

Perforator skin flaps and especially the ALT flap have been used in the reconstruction of a wide variety of soft tissue defects with good functional and aesthetic results,^{15,25} and many variations and modifications have been described for its use.¹⁸ Indeed, in the setting of foot and ankle reconstruction, the ALT flap is gaining in popularity (► Table 2). The main advantage of the ALT about the reconstruction of large defects of the weight-bearing foot is its versatility in design. It can be raised as a double-paddled flap to allow for a bespoke three-dimensional reconstruction, harvested as a thin skin flap or

This document was downloaded for personal use only. Unauthorized distribution is strictly prohibited.

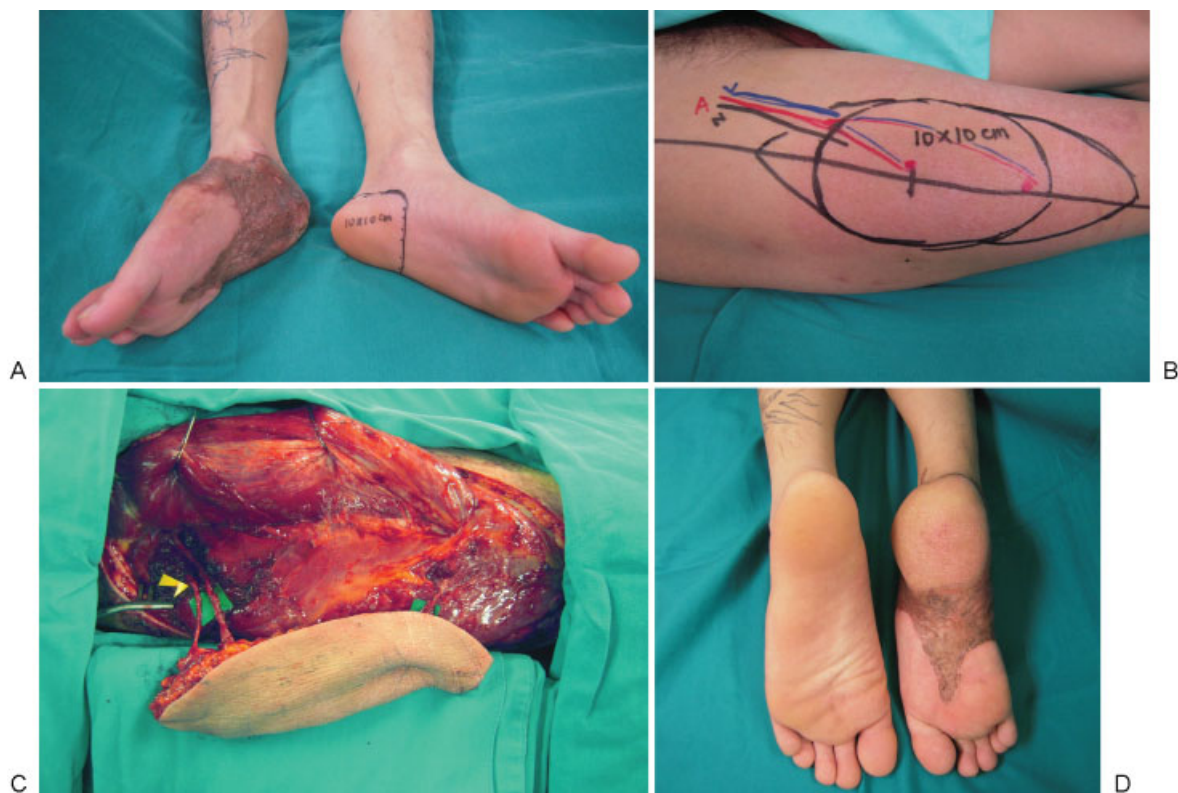


Fig. 1 (A) Case 4. A 21-year-old man presented with an unstable scar after split-thickness skin grafting over the right heel that was preventing ambulation. (B, C) Postdebridement, a 10- × 10-cm ALT perforator flap was harvested with the LFCN (yellow arrowhead). The artery was anastomosed in an end-to-side fashion to the posterior tibial artery and the LFCN was coapted to a branch of the medial plantar nerve. (D) At 2-year follow-up, the two-point discrimination in the flap was 12 mm. The reconstructed heel regained protective sensation, no tissue breakdown has been observed, and the patient is able to ambulate well with normal shoes. Source: Fig. 1B and C Reprinted with permission from Taylor and Francis Group LLC Books. Levine JP, Wei FC, *Reconstructive Surgery of the Lower Extremity*. Vol. 1. St. Louis, MO: Quality Medical Publishing; 2013:565.

raised as a myocutaneous flap with a segment of vastus lateralis to obliterate dead space, as has been reported in previous studies.¹⁵ Hong and Kim have also noted that the flap can be thinned down to a thickness of 3 to 6 mm to reduce the need for secondary debulking procedures and improve stability.¹⁵ Although we agree that this is a good solution for the non-weight-bearing zones of the foot as it can provide excellent contour, we feel that for the heel a well-cushioned reconstruction is essential to prevent breakdown over the underlying calcaneus and allow the patient to ambulate barefoot without special shoes. Furthermore, Hollenbeck et al noted that, regarding the weight-bearing subunits of the foot, thin flaps may indeed be at increased risk of breakdown.²⁰

The question of whether or not to raise a neurotized flap and perform sensory nerve coaptation at the recipient is another area of debate. Indeed, a normal range for two-point discrimination in the foot has not been precisely determined; however, the study by Nolan showed that the skin covering the plantar surface of the great toe demonstrated the greatest sensitivity in two-point discrimination ability with a mean value of 6.6 mm.⁴⁷ In addition, in a more recent study by Trevatt et al, it was shown that the mean two-point discrimination in native tissue of the foot and ankle region was 29 mm (standard deviation [SD] 11.9).⁴⁸ This suggests that a

range exists for normal two-point discrimination in the foot of between 6.6 and 29 mm. Some studies have indeed revealed that patients reconstructed with sensate flaps regained earlier sensibility and faster rehabilitation and return to work.^{15,26,27} However, most authors have highlighted no significant difference between neurotized and non-neurotized flaps regarding sensory recovery and long-term ulceration rate.^{11,15,27,28} Indeed, in our series we have shown that return to protective sensation was achieved in all cases despite 8/20 flaps being non-neurotized. However, as highlighted in previous studies,^{15,27} a faster return to protective sensation can be expected with neurotized flaps and in our series this was seen as early as 4 months postoperatively. At our institution, we adopt a policy of performing neurotization when sensory nerve is available at the recipient site. We feel that in young patients with trauma, this is worthwhile as it may speed up sensory recovery and functional return; however, further investigation is warranted to establish the exact effect that this may have on functional outcome. When raising an ALT perforator flap with the lateral cutaneous nerve of the thigh, the additional time for dissection is minimal as the nerve is easily identifiable in the subcutaneous tissue of the proximal skin paddle. However, care must be taken to orient the skin paddle such that the coaptation of the nerve does not put undue tension on the

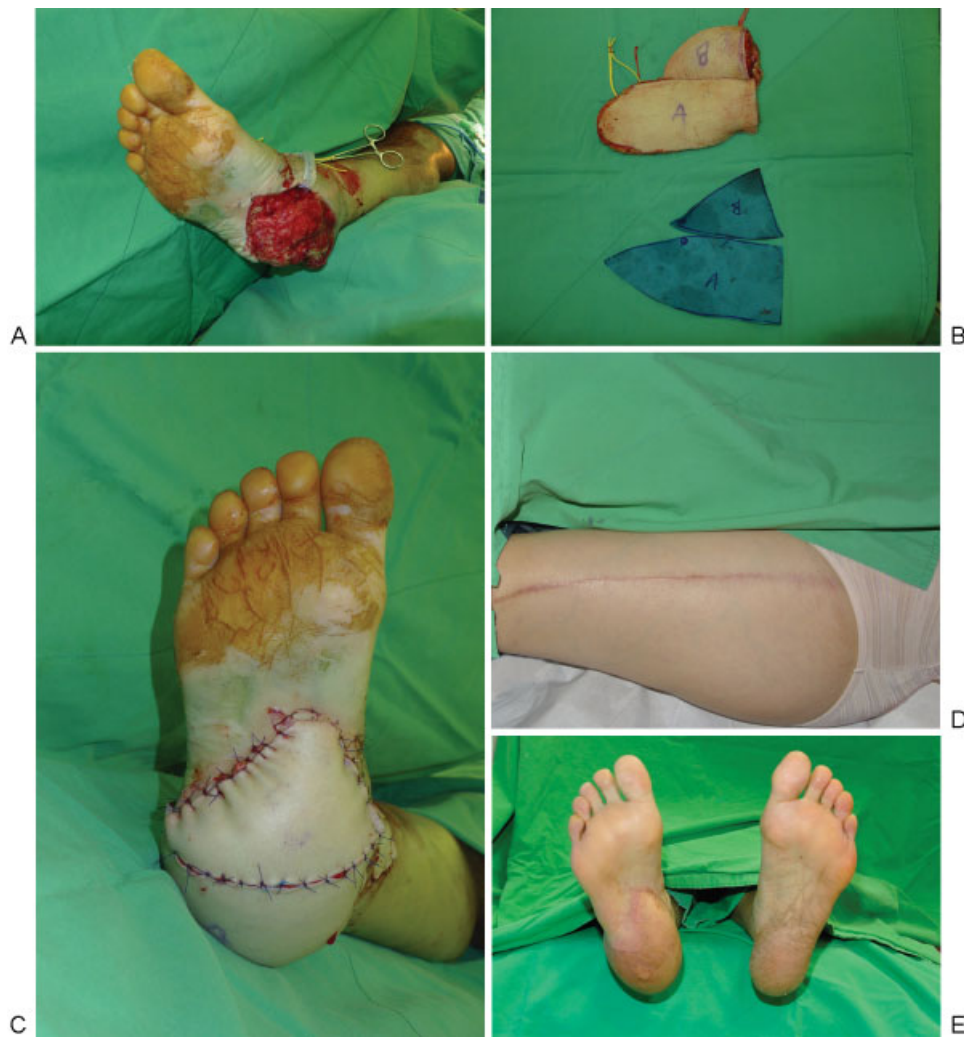

Fig. 2 (A) Case 14. A 54-year-old woman presented with right heel pad degloving injury. After debridement, the defect size measured 14×16 cm and was divided into subunits A,B for a bespoke three-dimensional subunit reconstruction. (B, C) A 23×8 -cm split neurotized free ALT based on two perforators was harvested. The neurotized A flap was used to reconstruct the weight-bearing heel pad, while the B flap was rotated to reconstruct the area just distal to the heel. (D) Primary closure of the donor site. (E) At 2-year follow-up, the foot demonstrated good contour, a 12-mm two-point discrimination, and recovery of protective sensation.

vascular anastomosis. The coaptation of the nerve to a sensory nerve in the foot is relatively quick and does not itself add much time to the procedure; however, meticulous reverse planning is essential to ensure that adequate nerve length has been harvested and that the skin paddle is of correct the dimensions to allow for tension-free neurotization. It is this planning process that indeed adds some time to the procedure, and the total additional operative time for neurotized versus non-neurotized flaps was on average 1 hour in our study.

Traditionally, when there has been no need for bony reconstruction, the use of free muscle flaps has been considered the treatment of choice.^{8,29,30} They provide robust vascular cover and great contour; however, skin grafting is required, which can result in long-term problems regarding breakdown over the graft. In our experience, muscle flaps with skin grafts for reconstruction of weight-bearing subunits of the foot are inferior to thin fasciocutaneous free flaps. We feel that not only is the donor-site morbidity less with a

fasciocutaneous perforator flap, but the skin cover at the recipient site is more robust and less likely to ulcerate in the long term. Indeed, a recent systematic review by Fox et al demonstrated that there was a higher rate of ulceration, revision, and the need for specialized foot wear in patients undergoing reconstruction with muscle flaps as compared with fasciocutaneous flaps.¹⁰

Although the study included more than 160 patients undergoing plantar resurfacing, these differences were not statistically significant demonstrating the need for more reconstructive surgeons to collaborate on multi-institutional prospective studies with robust outcome measures. In addition, the use of ALT flaps in the treatment of osteomyelitis is now well-established, as they provide a large amount of well-vascularized tissue that can be used to obliterate dead space and promote infection-free union.³¹ Indeed, numerous articles have reported on the excellent outcomes achieved with fasciocutaneous and skin flaps in this setting.^{24,32} Moreover, fasciocutaneous flaps can be easily lifted in

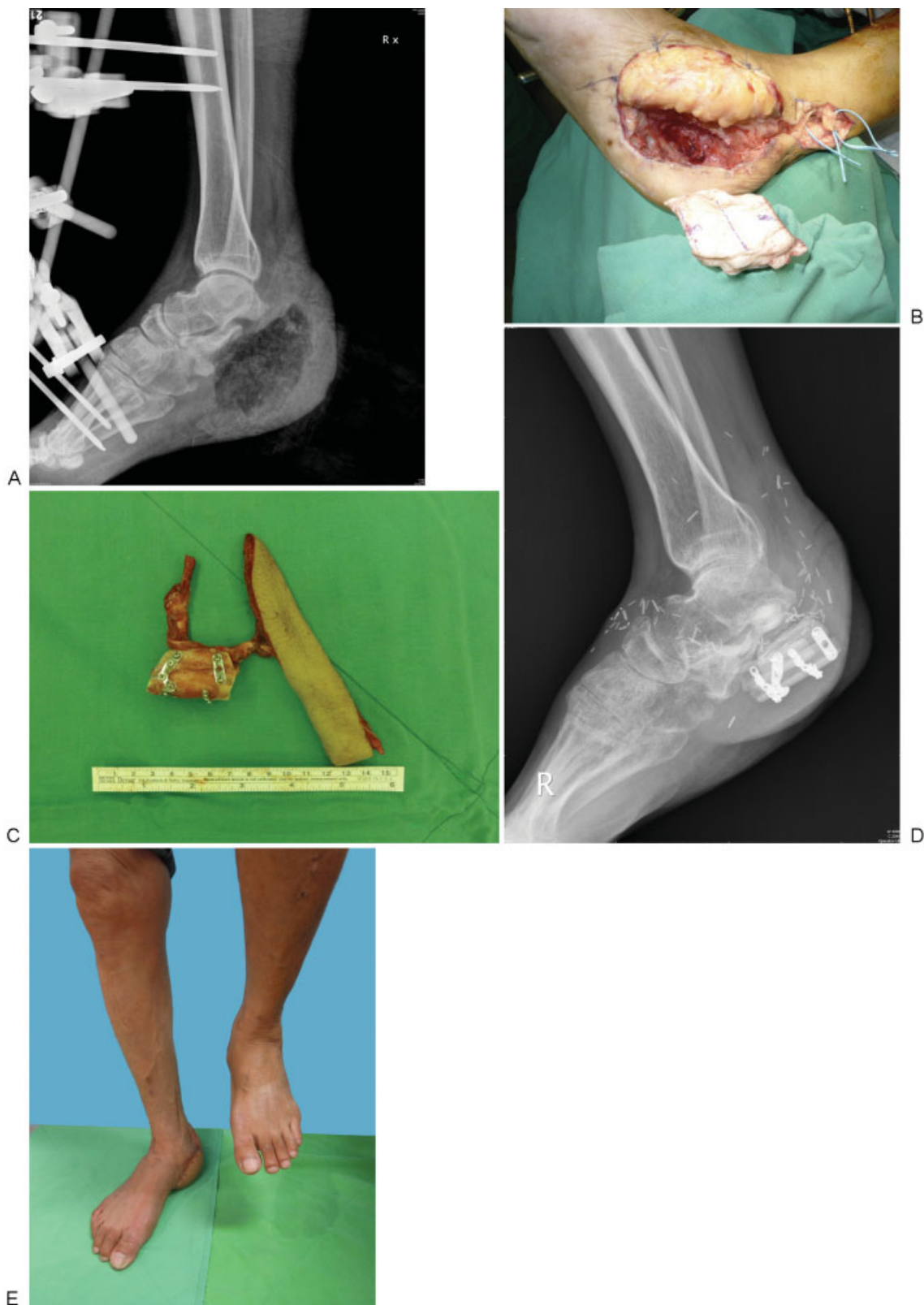

Fig. 3 (A) Case 20. A 50-year-old man presented with an open wound over the medial aspect of the right heel and open calcaneal fracture secondary to a fall from height. X-ray revealed an extensive calcaneal defect due to osteomyelitis. After serial debridement, the skin defect measured 14×8 cm with total calcaneal loss. A 12×6 -cm ALT flap was elevated for first-stage soft tissue coverage, and antibiotic beads were deployed to fill the bony defect. (B) The second-stage reconstruction was performed 45 days later. The calcaneal defect was preshaped with bone cement as a three-dimensional template. (C) Double-barrelled fibula osteocutaneous flap with a third barrel of free bone graft was modeled to match the size and shape of the template and inserted in situ using Kirschner wires for complete calcaneal reconstruction. (D, E) At 32 weeks, postoperative X-ray showed bony union and full-weight bearing was regained. (See ▶Video 1, which demonstrates the patient walking with normal gait.)

Table 2 Previous studies detailing the use of free ALT flaps in the reconstruction of defects of the foot and ankle

Reference	Country	Source	No. of patients	Type of flap	Site of defect
Pappalardo et al. 2016	Taiwan	Present study	20	ALT	Plantar resurfacing
Acar et al. 2015 ⁴¹	Turkey	J Reconstr Microsurg	11	ALT	Foot and ankle
Hu et al. 2015 ⁴²	China	Injury	25	ALT	Foot and ankle
El-Gammal et al. 2013 ⁴³	Egypt	Microsurgery	42	ALT	Dorsal foot
Liu et al. 2013 ⁴⁴	China	PLoS One	24	ALT	Dorsal foot, ankle, and plantar resurfacing
Demirtas et al. 2010 ⁴⁵	Turkey	Foot Ankle Int	5	ALT	Dorsal foot
Demirtas et al. 2010 ⁴⁶	Turkey	Foot Ankle Int	16	ALT	Dorsal foot, ankle, and plantar resurfacing
Hong and Kim 2007 ¹⁵	S. Korea	Plast Reconstr Surg	69	ALT	Plantar resurfacing

Abbreviation: ALT, anterolateral thigh flap.

second-stage procedures in which the bone needs to be accessed, and this represents another advantage in this approach over the skin-grafted muscle flap alternative.

In our series, we achieved good functional outcomes in all cases using free ALT fasciocutaneous flaps. We feel that an expert, thorough debridement of both the soft tissues and any affected bone, is paramount when tackling these challenging cases and is, in essence, the key step. Indeed, in 5 of 20 patients with associated calcaneal osteomyelitis, we achieved not only successful soft tissue coverage but also infection-free status of the bone. Use of antibiotic impregnated beads, a staged approach, meticulous debridement, and obliteration of all dead space with well-vascularized soft tissue were, we feel, key in achieving these results. Moreover, despite amputation as historically being the treatment of choice for complex (type III) calcaneal defects,^{33,34} we were able to not only salvage but also achieve a return to full weight-bearing status in a patient with total calcaneal loss secondary to infection.

In this modern era of reconstructive surgery, we should strive to improve outcomes not only at the recipient site but also at the donor site.³⁵⁻³⁷ In a study previously performed at our institution, we demonstrated that it was possible to directly close the ALT donor-site defects that were less than 16% of the thigh circumference.¹⁹ With this in mind, in five patients for whom a wide skin paddle was required, we adopted the principle of designing the ALT flap based on two sizable perforators. The skin paddle could then be split to achieve a bespoke three-dimensional reconstruction at the recipient site while allowing for direct closure of the donor site. Indeed, this technique is well established when attempting to reconstruct irregularly shaped defects.³⁸⁻⁴⁰ The need to raise the flap on at least two sizable perforators requires the need for accurate perforator mapping, however, and we tend to achieve this simply by using handheld Doppler, although the use of computed tomography (CT) angiography or color duplex ultrasound could represent alternative strategies to this end.

Although previous studies have reported on the use of the ALT in foot and ankle reconstruction (► **Table 2**), we feel that our series differs from that of previous studies for several reasons. First, our series deals with reconstructing large defects of the foot with the mean size of the ALT flaps that

we used being 180 cm². Moreover, we used several additional techniques to supplement our reconstructions, including the harvest of the LFCN for neurotization, splitting of the skin paddle based on at least two sizable perforators to ensure direct donor-site closure, and a three-dimensional bespoke inset at the recipient site. Indeed, in a single case we succeeded in achieving a functional reconstruction of total calcaneal loss with the use of an ALT flap and a double-barrelled free fibula osteocutaneous flap.

Conclusion

The ALT flap represents a versatile reconstructive option when tackling defects of the weight-bearing zones of the foot. It can be raised with a sensory nerve for coaptation at the recipient site and split into two paddles to achieve a bespoke three-dimensional inset. The skin is robust and the soft tissue is well vascularized that can help when associated calcaneal osteomyelitis is present. In our series protective sensation returned in all cases, no tissue breakdown has yet been detected throughout the follow-up period, and all patients returned to full weight-bearing status.

Disclosure

The authors have no financial interest to declare in relation to the content of this article.

References

- Cai J, Cao X, Liang J, Sun B. Heel reconstruction. *Plast Reconstr Surg* 1997;99(2):448-453
- Hidalgo DA, Shaw WW. Reconstruction of foot injuries. *Clin Plast Surg* 1986;13(4):663-680
- Shaw WW, Hidalgo DA. Anatomic basis of plantar flap design: clinical applications. *Plast Reconstr Surg* 1986;78(5):637-649
- Roblin P, Healy CM. Heel reconstruction with a medial plantar V-Y flap. *Plast Reconstr Surg* 2007;119(3):927-932
- Oh SJ, Moon M, Cha J, Koh SH, Chung CH. Weight-bearing plantar reconstruction using versatile medial plantar sensate flap. *J Plast Reconstr Aesthet Surg* 2011;64(2):248-254
- Jeng SF, Wei FC. Distally based sural island flap for foot and ankle reconstruction. *Plast Reconstr Surg* 1997;99(3):744-750

- 7 Benito-Ruiz J, Yoon T, Guisantes-Pintos E, Monner J, Serra-Renom JM. Reconstruction of soft-tissue defects of the heel with local fasciocutaneous flaps. *Ann Plast Surg* 2004;52(4):380-384
- 8 May JW Jr, Rohrich RJ. Foot reconstruction using free microvascular muscle flaps with skin grafts. *Clin Plast Surg* 1986;13(4):681-689
- 9 Lu S, Chai Y, Wang C, Wen G. Complex heel reconstruction with a sural fasciomyocutaneous perforator flap. *J Reconstr Microsurg* 2014;30(2):83-90
- 10 Fox CM, Beem HM, Wiper J, Rozen WM, Wagels M, Leong JC. Muscle versus fasciocutaneous free flaps in heel reconstruction: systematic review and meta-analysis. *J Reconstr Microsurg* 2015; 31(1):59-66
- 11 May JW Jr, Halls MJ, Simon SR. Free microvascular muscle flaps with skin graft reconstruction of extensive defects of the foot: a clinical and gait analysis study. *Plast Reconstr Surg* 1985;75(5): 627-641
- 12 Sommerlad BC, McGrouther DA. Resurfacing the sole: long-term follow-up and comparison of techniques. *Br J Plast Surg* 1978; 31(2):107-116
- 13 Sönmez A, Bayramiçli M, Sönmez B, Numanoğlu A. Reconstruction of the weight-bearing surface of the foot with nonneurosensory free flaps. *Plast Reconstr Surg* 2003;111(7):2230-2236
- 14 Ohjimi H, Taniguchi Y, Kawano K, Kinoshita K, Manabe T. A comparison of thinning and conventional free-flap transfers to the lower extremity. *Plast Reconstr Surg* 2000;105(2):558-566
- 15 Hong JP, Kim EK. Sole reconstruction using anterolateral thigh perforator free flaps. *Plast Reconstr Surg* 2007;119(1):186-193
- 16 Song YG, Chen GZ, Song YL. The free thigh flap: a new free flap concept based on the septocutaneous artery. *Br J Plast Surg* 1984; 37(2):149-159
- 17 Kuo YR, Seng-Feng J, Kuo FM, Liu YT, Lai PW. Versatility of the free anterolateral thigh flap for reconstruction of soft-tissue defects: review of 140 cases. *Ann Plast Surg* 2002;48(2):161-166
- 18 Wei FC, Jain V, Celik N, Chen HC, Chuang DC, Lin CH. Have we found an ideal soft-tissue flap? An experience with 672 anterolateral thigh flaps. *Plast Reconstr Surg* 2002;109(7):2219-2226, discussion 2227-2230
- 19 Boca R, Kuo YR, Hsieh CH, Huang EY, Jeng SF. A reliable parameter for primary closure of the free anterolateral thigh flap donor site. *Plast Reconstr Surg* 2010;126(5):1558-1562
- 20 Hollenbeck ST, Woo S, Komatsu I, Erdmann D, Zenn MR, Levin LS. Longitudinal outcomes and application of the subunit principle to 165 foot and ankle free tissue transfers. *Plast Reconstr Surg* 2010; 125(3):924-934
- 21 Lin CH, Lin CH. Reconstruction of the weight-bearing heel. In: Pu LLQ, Levine JP, Wei FC, eds. *Reconstructive Surgery of the Lower Extremity*. Vol. 1. St. Louis, MO: Quality Medical Publishing; 2013: 1251-1267
- 22 Morrison WA, Crabb DM, O'Brien BM, Jenkins A. The instep of the foot as a fasciocutaneous island and as a free flap for heel defects. *Plast Reconstr Surg* 1983;72(1):56-65
- 23 Scheufler O, Kalbermatten D, Pierer G. Instep free flap for plantar soft tissue reconstruction: indications and options. *Microsurgery* 2007;27(3):174-180
- 24 Weinzweig N, Davies BW. Foot and ankle reconstruction using the radial forearm flap: a review of 25 cases. *Plast Reconstr Surg* 1998; 102(6):1999-2005
- 25 Hong JP. Reconstruction of the diabetic foot using the anterolateral thigh perforator flap. *Plast Reconstr Surg* 2006;117(5):1599-1608
- 26 Kuran I, Turgut G, Bas L, Ozkan T, Bayri O, Gulgonen A. Comparison between sensitive and nonsensitive free flaps in reconstruction of the heel and plantar area. *Plast Reconstr Surg* 2000;105(2): 574-580
- 27 Santanelli F, Tenna S, Pace A, Scuderi N. Free flap reconstruction of the sole of the foot with or without sensory nerve coaptation. *Plast Reconstr Surg* 2002;109(7):2314-2322, discussion 2323-2324
- 28 Potparić Z, Rajacić N. Long-term results of weight-bearing foot reconstruction with non-innervated and reinnervated free flaps. *Br J Plast Surg* 1997;50(3):176-181
- 29 Mathes SJ, Alpert BS, Chang N. Use of the muscle flap in chronic osteomyelitis: experimental and clinical correlation. *Plast Reconstr Surg* 1982;69(5):815-829
- 30 Gosain A, Chang N, Mathes S, Hunt TK, Vasconez L. A study of the relationship between blood flow and bacterial inoculation in musculocutaneous and fasciocutaneous flaps. *Plast Reconstr Surg* 1990;86(6):1152-1162, discussion 1163
- 31 Hong JP, Shin HW, Kim JJ, Wei FC, Chung YK. The use of anterolateral thigh perforator flaps in chronic osteomyelitis of the lower extremity. *Plast Reconstr Surg* 2005;115(1):142-147
- 32 Musharrafieh R, Osmani O, Musharrafieh U, Saghie S, Atiyeh B. Efficacy of microsurgical free-tissue transfer in chronic osteomyelitis of the leg and foot: review of 22 cases. *J Reconstr Microsurg* 1999;15(4):239-244
- 33 Baumhauer JF, Fraga CJ, Gould JS, Johnson JE. Total calcaneotomy for the treatment of chronic calcaneal osteomyelitis. *Foot Ankle Int* 1998;19(12):849-855
- 34 Barbour J, Saunders S, Hartsock L, Schimpf D, O'Neill P. Calcaneal reconstruction with free fibular osteocutaneous flap. *J Reconstr Microsurg* 2011;27(6):343-348
- 35 Jeng SF, Tan NC. Optimizing aesthetic and functional outcomes at donor sites. *Chang Gung Med J* 2012;35(3):219-230
- 36 Kimata Y, Uchiyama K, Ebihara S, et al. Anterolateral thigh flap donor-site complications and morbidity. *Plast Reconstr Surg* 2000; 106(3):584-589
- 37 Calderón W, Borel C, Roco H, Piñeros JL, Olguin F. Primary closure of donor site in anterolateral cutaneous thigh free flap. *Plast Reconstr Surg* 2006;117(7):2528-2529
- 38 Tsai FC, Yang JY, Mardini S, Chuang SS, Wei FC. Free split-cutaneous perforator flaps procured using a three-dimensional harvest technique for the reconstruction of postburn contracture defects. *Plast Reconstr Surg* 2004;113(1):185-193, discussion 194-195
- 39 Marsh DJ, Chana JS. Reconstruction of very large defects: a novel application of the double skin paddle anterolateral thigh flap design provides for primary donor-site closure. *J Plast Reconstr Aesthet Surg* 2010;63(1):120-125
- 40 Chang NJ, Waughlock N, Kao D, Lin CH, Lin CH, Hsu CC. Efficient design of split anterolateral thigh flap in extremity reconstruction. *Plast Reconstr Surg* 2011;128(6):1242-1249
- 41 Acar MA, Güleç A, Aydin BK, Erkoçak ÖF, Yilmaz G, Şenaran H. Reconstruction of foot and ankle defects with a free anterolateral thigh flap in pediatric patients. *J Reconstr Microsurg* 2015;31(3): 225-232
- 42 Hu R, Ren YJ, Yan L, et al. A free anterolateral thigh flap and iliotibial band for reconstruction of soft tissue defects at children's feet and ankles. *Injury* 2015;46(10):2019-2023
- 43 El-Gammal TA, El-Sayed A, Kotb MM, et al. Dorsal foot resurfacing using free anterolateral thigh (ALT) flap in children. *Microsurgery* 2013;33(4):259-264
- 44 Liu L, Cao X, Zou L, Li Z, Cao X, Cai J. Extended anterolateral thigh flaps for reconstruction of extensive defects of the foot and ankle. *PLoS ONE* 2013;8(12):e83696
- 45 Demirtas Y, Neimetzade T, Kelahmetoglu O, Guneren E. Free anterolateral thigh flap for reconstruction of car tire injuries of children's feet. *Foot Ankle Int* 2010;31(1):47-52
- 46 Demirtas Y, Neimetzade T, Kelahmetoglu O, Guneren E. Comparison of free muscle and perforator skin flaps for soft tissue reconstruction of the foot and ankle. *Foot Ankle Int* 2010;31(1):53-58
- 47 Nolan MF. Limits of two-point discrimination ability in the lower limb in young adult men and women. *Phys Ther* 1983;63(9):1424-1428
- 48 Trevatt AE, Filobos G, Ul Haq A, Khan U. Long-term sensation in the medial plantar flap: a two-centre study. *Foot Ankle Surg* 2014; 20(3):166-169